

· 临床研究 ·

椎弓根螺钉在颈胸段骨折脱位中的临床运用

赵刘军, 徐荣明, 马维虎, 蒋伟宇, 校佰平, 阮永平, 孙韶华, 胡勇, 顾勇杰
(宁波市第六医院脊柱外科, 浙江 宁波 315040)

【摘要】 目的:评价椎弓根螺钉技术在颈胸段骨折脱位(C_6-T_2)中的运用价值。方法:2001年5月至2008年1月运用椎弓根螺钉植入技术治疗颈胸段骨折脱位患者26例,男17,女9例;年龄20~75岁,平均48.5岁。采用单纯后路椎弓根螺钉技术17例,后路椎弓根螺钉技术结合前路减压钢板内固定9例。术后3d运用CT平扫及重建片观察评价植入颈胸段椎弓根螺钉的准确性、螺钉植入相关并发症;随访观察患者颈胸段术后植骨融合情况;统计患者术前与术后6个月JOA评分及ASIA分级改善情况,综合评价患者脊髓及神经功能改善情况。结果:所有患者获得随访,随访时间3~74个月,平均36.5个月。4例完全性瘫痪患者术后6个月内死亡。共计植入椎弓根螺钉104枚,其中颈椎椎弓根74螺钉枚(其中: C_5 16枚, C_6 16枚, C_7 42枚),胸椎椎弓根螺钉30枚(其中: T_1 22枚, T_2 8枚),所有椎弓根螺钉在术中均成功植入,无脊髓、神经根及椎动脉损伤。术后CT提示颈椎椎弓根螺钉11枚(14.9%)穿破椎弓根,其中7枚(9.5%)穿破外侧皮质,1枚(1.4%)穿破椎弓根上侧皮质,3枚(4.1%)穿破椎弓根下侧皮质。胸椎椎弓根螺钉中,3枚(10%)穿破胸椎椎弓根,其中2枚(6.7%)穿出椎弓根外侧缘,1枚(3.3%)穿破内侧缘(<2 mm),但无临床症状。术后随访1枚 C_5 椎弓根螺钉断裂,但患者无明显临床症状,其余无螺钉松动及断钉情况出现。所有患者固定良好,并均达到骨性融合。术后6个月患者平均JOA评分由术前(7.5 ± 2.0)分恢复到(14.5 ± 2.3)分,差异有统计学意义($t=6.34, P<0.05$)。ASIA分级情况,除3例完全性瘫痪患者脊髓功能术后无明显改善外,余患者术后脊髓神经功能均有不同程度恢复。结论:椎弓根螺钉在颈胸段骨折脱位治疗中安全、可靠。术者应熟练掌握颈胸段后路解剖及椎弓根螺钉植入技巧,术前要仔细测量相关影像学参数,个体化治疗每一位患者。

【关键词】 颈椎; 胸椎; 骨折; 骨折固定术,内

Application of the pedicle screws for cervicothoracic fracture-dislocation ZHAO Liu-jun, XU Rong-ming, MA Wei-hu, JIANG Wei-yu, XIAO Bai-ping, RUAN Yong-ping, SUN Shao-hua, HU Yong, GU Yong-jie. Orthopaedic Department, the 6th Hospital of Ningbo, Ningbo 315040, Zhejiang, China

ABSTRACT **Objective:** To explore pedicle screw implantation for fracture-dislocation injuries at cervicothoracic junction (C_6-T_2). **Methods:** Pedicle screw implantation was used for twenty-six patients with cervicothoracic fracture-dislocation from May 2001 to Jan 2008. There were 17 males and 9 females with an average of 48.5 years (range, 20 to 75 years). Single posterior pedicle screw fixation was performed for 17 cases, and posterior screw fixation combined with anterior reduction and plate fixation for the other nine. The accuracy of the pedicle screws were evaluated by CT views after surgery. Complications and neurological recovery were also recorded after the procedures. **Results:** All subjects were followed up from 3 to 74 months with average 36.5 months. Four cases of complete paraplegia died of cardiovascular or pulmonary failure within half a year after surgery. There were 104 pedicle screws implanted totally including 74 pedicle screws in cervical vertebrae, 16 at C_5 , 16 at C_6 , 42 at C_7 , and 30 pedicle screws in upper thoracic vertebrae, in which 22 at T_1 , 8 at T_2 . No injury of spinal cord, nerve roots and vertebral artery was found during operation. Eleven screws (14.9%) were perforated out of the pedicles in cervical spine, in which 7 (9.5%) through lateral cortex, 1 (1.4%) through the superior and 3 (4.1%) through the inferior. Three screws (10%) were perforated in upper thoracic spine, in which 2 (6.7%) by lateral cortex and 1 (3.3%) by the medial (within 2 mm). Bony fusion was achieved for all cases and all internal fixator was good except 1 screw broken at C_5 . JOA score increased from preoperative (7.5 ± 2.0) to postoperative (14.5 ± 2.3) evaluated in 6 months after operation, with statistic difference ($t=6.34, P<0.05$). Neurological improvement was gotten in all patients according to ASIA classification but three cases who suffered from complete neurological injuries. **Conclusion:** Implantation of pedicle screws at cervicothoracic junction can be safe and reliable if the surgeon is familiar with the local anatomy of cervicothoracic spine, and the technique for implantation of the screws. Related radiological parameters should be measured for each subject before the operation in attempt to get a therapy individually.

Key words Cervical vertebrae; Thoracic vertebrae; Fractures; Fracture fixation, internal

颈胸段骨折脱位伴发或不伴发神经损伤的患者在临床上并不少见,由于部位特殊,临床上常有漏诊病例,治疗也有其特殊性。我们从 2001 年 5 月至 2008 年 1 月,运用椎弓根螺钉技术手术治疗 26 例患者,取得了满意疗效,现报告如下。

1 临床资料与方法

1.1 一般资料 本组 26 例,男 17,女 9 例;年龄 20~75 岁,平均 48.5 岁。其中车祸伤 15 例,高处坠落伤 8 例,2 例重物轧砸伤,1 例爆炸伤。C₆爆裂骨折 10 例,C₆-C₇骨折脱位 5 例,C₇爆裂骨折 3 例,C₇-T₁骨折脱位 6 例,T₁爆裂骨折 2 例。JOA 评分:术前平均为(7.5±2.0)分;ASIA 分级:A 级 8 例,B 级 10 例,C 级 5 例,D 级 2 例,E 级 1 例。

1.2 治疗方法

1.2.1 术前评估 所有患者均进行术前 CT 扫描加二维重建像。矢状位像上重点观察颈胸段椎弓根的高度、走行(相对于椎体终板而言)及其后缘的解剖关系;横断位像重点关注椎弓根的内外径、内倾角及椎弓根在后方的解剖投影点。

1.2.2 手术方式 采用单纯后路椎弓根螺钉技术 17 例,I 期后路椎弓根螺钉技术结合前路减压钢板内固定 9 例。手术在全麻下进行。对于单纯后路手术患者,采用俯卧位,头颈置于手术架上,头呈中立位固定,取后正中切口,切开皮肤、皮

下组织。顺白线切开,将两侧肌肉行骨膜下剥离,显露相应节段棘突、椎板、颈椎侧块及胸椎肋椎复合体,对于有脱位的椎体及交锁的关节突关节予以牵引撬拨复位,尽量恢复患者正常的颈胸段解剖序列。对于前后联合入路的患者均先后路手术(具体同单纯后路),翻身后再行前路手术。前路取左侧胸锁乳突肌前缘斜切口,行患椎椎体次全切除减压植骨融合内固定。典型病例见图 1-2。

(1)颈椎椎弓根螺钉的植入:充分暴露颈胸段颈椎侧块,取侧块外上象限中点作为进钉点,用球形钻头磨去骨皮质。用丝锥制备钉道,注意向尾侧倾 10°,锥入的深度约 2~2.5 cm(具体的进钉点及方向参考每位患者术前 CT 行个体化处理)。攻丝锥时要注意寻找松质骨的“软区”,若遇到较大阻力,则应改变方向,尽量顺软区前进。丝锥完成后,利用椎弓根探针探测通道的四周及底部,探查时若为骨性、有摩擦感的侧壁及坚实的底部,则通道制备正常,未穿出椎体前缘,根据所需长度可植入直径 3.5 mm 或 4.0 mm 的椎弓根螺钉;若为软区,无阻挡的软性侧壁或底部,则说明已穿出骨皮质外,此时应仔细分析原因并行 C 形臂透视,如二次或多次锥入仍错误,则应咬除同侧椎板,直视下行椎弓根螺钉的植入,本组 3 枚椎弓根螺钉进行了此种操作。当穿刺点有骨折时,应分情况对待:

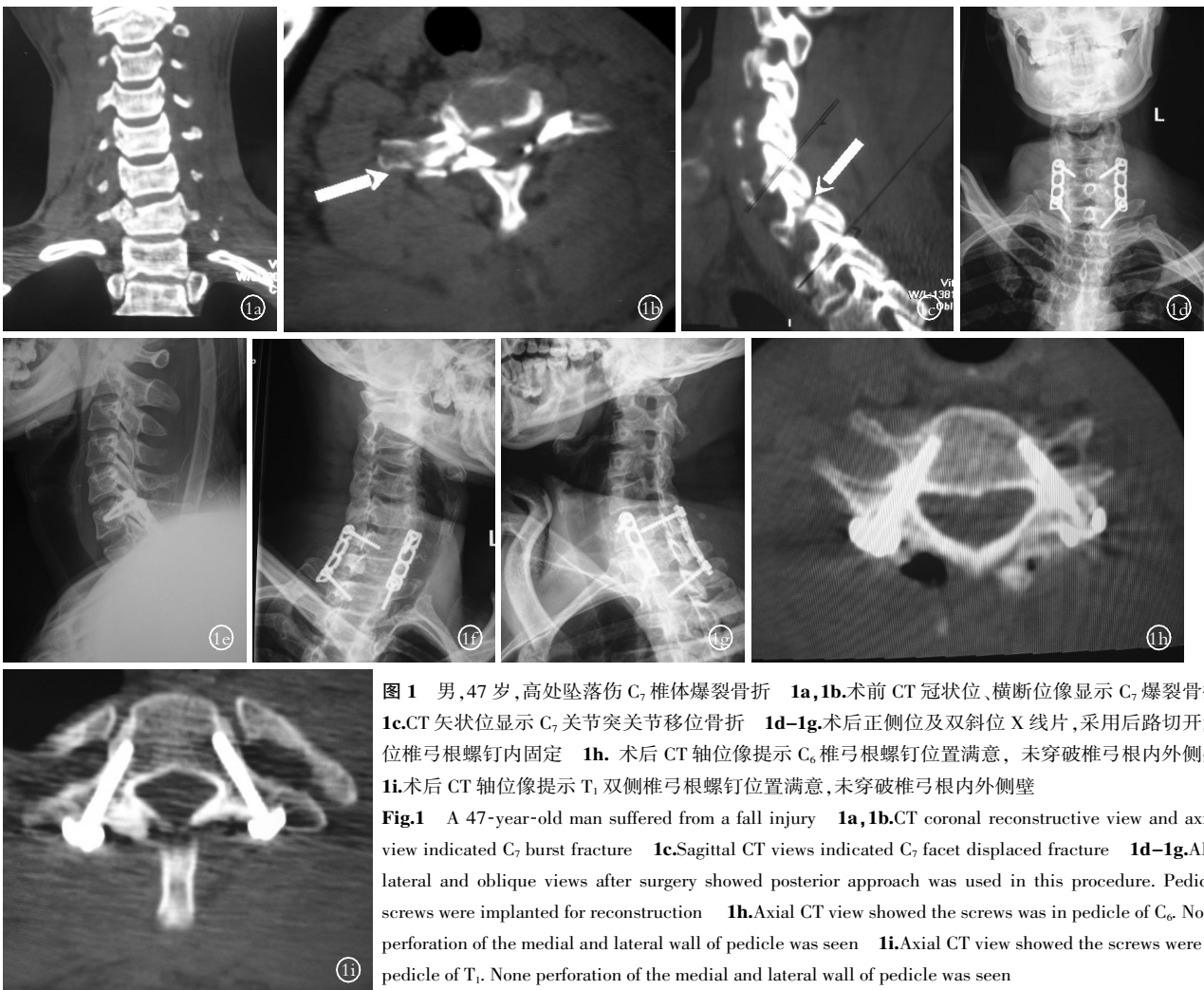

图 1 男,47 岁,高处坠落伤 C₇ 椎体爆裂骨折 1a,1b.术前 CT 冠状位、横断位像显示 C₇ 爆裂骨折 1c.CT 矢状位显示 C₇ 关节突关节移位骨折 1d-1g.术后正侧位及双斜位 X 线片,采用后路切开复位椎弓根螺钉内固定 1h.术后 CT 轴位像提示 C₆ 椎弓根螺钉位置满意,未突破椎弓根内外侧壁 1i.术后 CT 轴位像提示 T₁ 双侧椎弓根螺钉位置满意,未突破椎弓根内外侧壁

Fig.1 A 47-year-old man suffered from a fall injury 1a,1b.CT coronal reconstructive view and axial view indicated C₇ burst fracture 1c.Sagittal CT views indicated C₇ facet displaced fracture 1d-1g.AP, lateral and oblique views after surgery showed posterior approach was used in this procedure. Pedicle screws were implanted for reconstruction 1h.Axial CT view showed the screws was in pedicle of C₆. None perforation of the medial and lateral wall of pedicle was seen 1i.Axial CT view showed the screws were in pedicle of T₁. None perforation of the medial and lateral wall of pedicle was seen

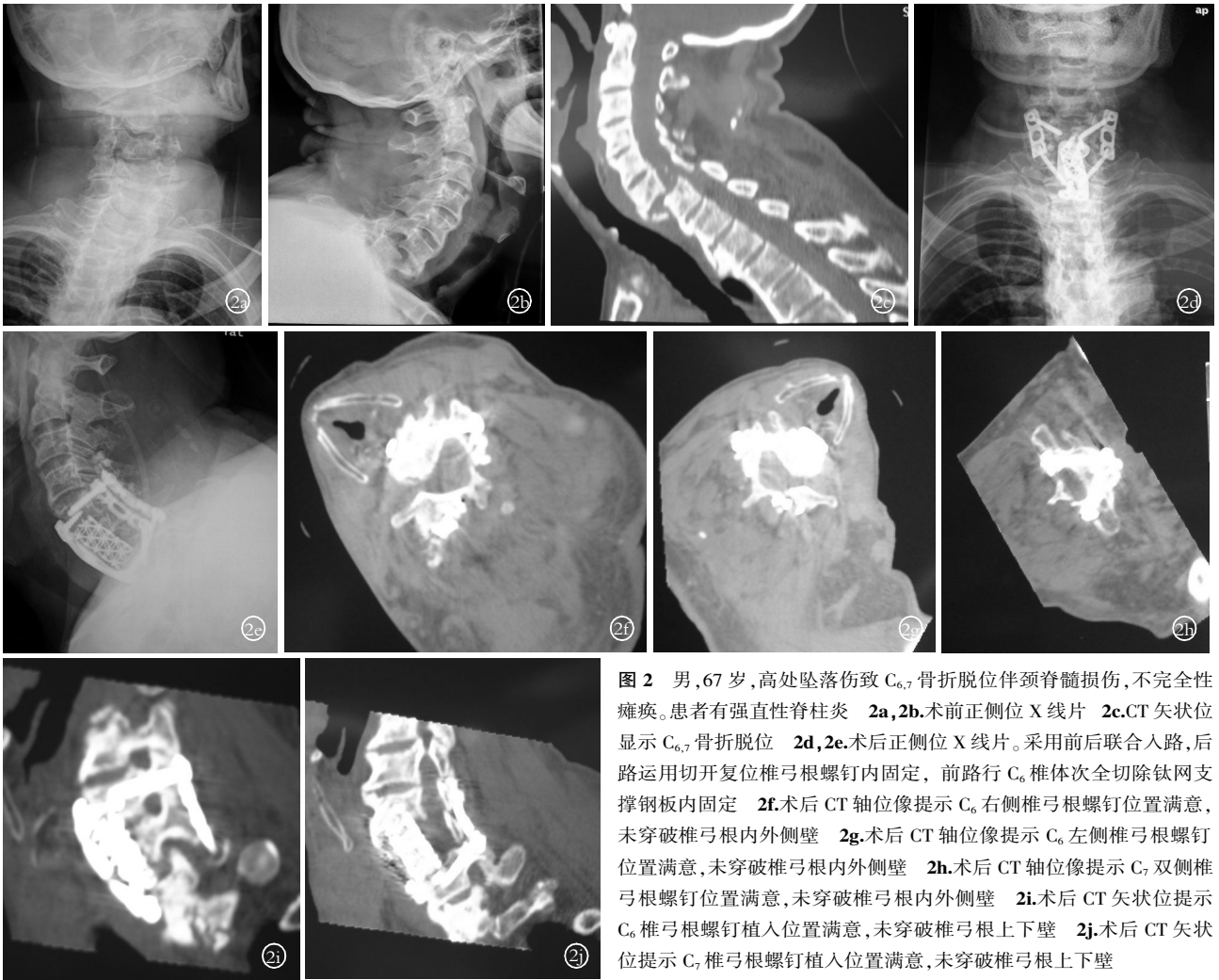


图 2 男,67 岁,高处坠落伤致 C_{6,7} 骨折脱位伴颈脊髓损伤,不完全性瘫痪。患者有强直性脊柱炎 2a,2b.术前正侧位 X 线片 2c.CT 矢状位显示 C_{6,7} 骨折脱位 2d,2e.术后正侧位 X 线片。采用前后联合入路,后路运用切开复位椎弓根螺钉内固定,前路行 C₆ 椎体次全切除钛网支撑钢板内固定 2f.术后 CT 轴位像提示 C₆ 右侧椎弓根螺钉位置满意,未突破椎弓根内外侧壁 2g.术后 CT 轴位像提示 C₆ 左侧椎弓根螺钉位置满意,未突破椎弓根内外侧壁 2h.术后 CT 轴位像提示 C₇ 双侧椎弓根螺钉位置满意,未突破椎弓根内外侧壁 2i.术后 CT 矢状位提示 C₆ 椎弓根螺钉植入位置满意,未突破椎弓根上下壁 2j.术后 CT 矢状位提示 C₇ 椎弓根螺钉植入位置满意,未突破椎弓根上下壁

Fig.2 A 67-year-old man suffered from ankylosing spondylitis before a fall

injury. C_{6,7} fracture-dislocation associated with incomplete paraplegia was found 2a,2b.AP and lateral views before surgery 2c.Sagittal CT indicated C₆-C₇ fracture dislocation 2d,2e.AP and lateral view after surgery showed combined posterior and anterior approaches were used in this procedure. Pedicle screws and anterior plate were implanted for reconstruction 2f.Axial CT view showed the screw was in pedicle of C₆ on right side. None perforation of the medial and lateral wall of pedicle was seen 2g.Axial CT view showed the screw was in pedicle of C₆ on left side. None perforation of the medial and lateral wall of pedicle was seen 2h.Axial CT view showed the screws were in pedicle of C₇. None perforation of the medial and lateral wall of pedicle was seen 2i.Sagittal CT view showed the screw was in pedicle of C₆. None perforation of the superior and inferior wall of pedicle was seen 2j.Sagittal CT view showed the screw was in pedicle of C₇. None perforation of the superior and inferior wall of pedicle was seen

如骨折无明显移位,仍可按照原计划行椎弓根螺钉植入;如骨折移位明显,则可咬除同侧椎板,探查椎弓根后在直视下行螺钉植入。

(2)胸椎椎弓根螺钉的植入;颈胸段胸椎椎弓根螺钉的进钉点选择在关节突关节中点下方约 1 mm,进钉方向为内倾 20°~40°、下倾 20°左右(具体根据患者术前 CT 测量个性化操作)。钉道制备及螺钉植入同颈胸段颈椎椎弓根螺钉。

1.3 观察项目与评价方法 术后 3 d 运用 CT 平扫及重建片观察评价植入颈胸段椎弓根螺钉的准确性、螺钉植入相关并发症。观察颈胸段椎弓根螺钉穿透椎弓根皮质的情况。随访椎弓根螺钉断钉、松动情况及随访观察患者颈胸段术后植骨融合情况。参照 JOA 评分法,统计患者术前及术后 6 个月 JOA 评分改善情况。随访 ASIA 分级改善情况,综合评价患者脊髓

及神经功能改善情况。

1.4 统计学方法 采用 SPSS 11.5 软件,对 JOA 评分进行配对 *t* 检验, $P < 0.05$ 为差异有统计学意义。

2 结果

2.1 螺钉置入情况 共计植入椎弓根螺钉 104 枚,其中颈椎椎弓根螺钉 74 枚(其中:C₅16 枚,C₆16 枚,C₇ 42 枚),胸椎椎弓根螺钉 30 枚(其中:T₁ 22 枚,T₂ 8 枚),所有椎弓根螺钉在术中均成功植入,无脊髓、神经根及椎动脉损伤。术后 3 d CT 平扫及重建片提示:颈椎椎弓根螺钉 11 枚(14.9%)突破椎弓根,其中 7 枚(9.5%)突破外侧皮质,1 枚(1.4%)突破椎弓根上侧皮质,3 枚(4.1%)突破椎弓根下侧皮质;胸椎椎弓根螺钉 3 枚(10%)突破胸椎椎弓根,其中 2 枚(6.7%)穿出椎弓根外侧缘,1 枚(3.3%)突破内侧缘(<2 mm),但无临床症状。术后

随访 1 枚 C₅ 椎弓根螺钉断裂,但患者无明显临床症状,其余无螺钉松动及断钉情况出现。所有患者固定良好,并均达到骨性融合,未见假关节形成。

2.2 JOA 评分情况 术后 6 个月 JOA 评分平均达 (14.5±2.3)分,较术前(7.5±2.0)分明显提高,差异有统计学意义($t=6.34, P<0.05$)。

2.3 脊髓神经功能 所有患者获随访,随访时间 3~74 个月,平均 36.5 个月。4 例完全性瘫痪患者术后 6 个月内死亡。8 例 ASIA 分级为 A 级的患者中,3 例术后无明显改善,5 例截瘫平面下降 1~2 个脊髓节段。其余患者脊髓神经功能均有明显恢复(B 级 10 例中,2 例恢复为 E 级,5 例恢复为 D 级,3 例恢复为 C 级;C 级 5 例中,4 例恢复为 E 级,1 例恢复为 D 级;D 级 2 例中,均恢复为 E 级;E 级 1 例患者术后肢体麻木症状明显好转)。

3 讨论

3.1 颈胸段损伤的特殊性 颈胸段损伤患者由于肩部阻挡,常常难于诊断,容易漏诊甚至误诊^[1-3]。对颈胸段的损伤常规运用 X 线片、CT 平扫及矢状位冠状位重建、MRI 检查,这样可以避免延误诊断,有利于尽快制定有效的治疗方案。有理由相信,随着 CT 三维重建和 MRI 在临床上的广泛应用,颈胸段骨折脱位的误诊及漏诊率将会明显下降,而针对该部位开展的手术也必将会更加广泛^[4]。

3.2 颈胸段骨折脱位后路椎弓根螺钉固定、复位的技巧及方法 在颈胸段骨折脱位时,常常伴有小关节突关节交锁。此时应仔细将撕裂的关节囊切除,以清楚显示手术野,软组织向两侧剥离至颈椎显露两侧侧块的外缘、胸椎节段暴露两侧横突,以保证颈胸段椎弓根螺钉的精确放置。在颅骨牵引帮助下,术者直视将损伤节段上下棘突分别向上下牵引,关节突即可复位。复位后,可视骨折脱位的部位、程度,选择适当的椎弓根螺钉固定节段。通常采用钛或钛合金内固定器械,这样可确保术后 MRI 检查不受影响。在复位时,由于后结构损伤,用力需均匀缓慢。如复位有困难,则可用神经剥离子或小的骨膜剥离器伸入脱位的关节突下方撬拨复位。如果仍然较困难,可将脱位的关节突关节部分切除后再复位。如果脱位关节突不能复位,亦不能使用暴力强求复位,可在原位固定,然后再考虑颈椎前路减压和固定融合术,本组 11 例患者选择了 I 期前后联合入路手术治疗。

3.3 颈胸段椎弓根螺钉治疗的优势及注意事项 颈胸段椎弓根螺钉经过“力核”固定,具有三维稳定性,优于其他内固定

方法。徐荣明等^[5]运用 342 枚颈椎椎弓根螺钉治疗 76 例患者,除 1 例螺钉断裂外未见螺钉松动或断裂及颈椎不稳症,取得了明显的临床效果。Daubs 等^[6]认为,T₁-T₃ 椎弓根相对较大,呈卵圆形,大多数患者可以行椎弓根螺钉固定,这种固定优于其他内固定形式。

然而,颈胸段椎弓根直径细,角度特殊,经椎弓根螺钉固定手术操作风险大,有损伤脊髓、神经根及周围血管的可能,因此熟悉颈胸段局部解剖是手术成功的重要前提。在手术操作中,由于肩部阻挡使得 C 形臂监视下控制螺钉矢状位的方向和深度难以实现,这进一步加大了椎弓根螺钉植入的风险。术前运用 CT 重建图像仔细测量颈胸段椎弓根轴线在后侧附件上的投影、椎弓根螺钉的内倾角及下倾角,这对于个体化颈胸段椎弓根螺钉植入意义重大。

颈胸段骨折脱位伴有完全性瘫痪者神经功能恢复率低、病死率高,预后不佳。Lenoir 等^[7]运用后路复位椎弓根螺钉治疗不稳定颈胸段骨折脱位患者 30 例,7 例患者 4 个月内死于心肺功能不全。本组 4 例完全性瘫痪患者术后 6 个月内死亡,死因也主要为心肺功能不全。单纯 I 期后路椎弓根螺钉系统固定节段最好不要超过 T₃。

参考文献

- [1] Bohlman HH, Freehafer A, Dejak J. The results of treatment of acute injuries of the upper thoracic spine with paralysis. *J Bone Joint Surg (Am)*, 1985, 67(3): 360-369.
- [2] Evans DK. Dislocation at the cervicothoracic junction. *J Bone Joint Surg (Br)*, 1983, 65(2): 124-127.
- [3] Stulik J, Vyskocil T, Sebesta P, et al. Surgical treatment for disorders of the cervicothoracic junction region. *Aeta Chir Orthop Traumatol Cech*, 2005, 72(4): 213-220.
- [4] 滕红林, 贾连顺, 肖建如, 等. MRI 测量颈胸角在选择颈胸段脊柱手术入路中的临床应用. *中国骨伤*, 2004, 17(6): 325-328.
- [5] 徐荣明, 马维虎, 刘观燧, 等. 椎弓根螺钉技术在颈下颈椎不稳中的安全使用方法. *中华创伤杂志*, 2007, 23(1): 21-24.
- [6] Daubs MD, Kim YJ, Lenke LG. Pedicle screw fixation (T₁, T₂, and T₃). *Instr Course Lect*, 2007, 56: 247-255.
- [7] Lenoir T, Hoffmann E, Thevenin-Lemoine C, et al. Neurological and functional outcome after unstable cervicothoracic junction injury treated by posterior reduction and synthesis. *Spine J*, 2006, 6(5): 507-513.

(收稿日期:2009-06-10 本文编辑:王玉蔓)

本刊关于“通讯作者”有关事宜的声明

本刊要求集体署名的文章必须明确通讯作者。凡文章内注明通讯作者的稿件,与该稿件相关的一切事宜(包括邮寄稿件、收稿通知单、退稿、退修稿件、校样、版面费、稿费、赠刊等)均与通信作者联系。如文内未注明通讯作者的文章,按国际惯例,有关稿件的一切事宜均与第一作者联系,特此声明!