

[19] He D, Yu W, Chen Z, et al. Pathogenesis of the intravertebral vacuum of Kümmell's disease [J]. *Exp Ther Med*, 2016, 12(2): 879-882.

[20] Ha KY, Kim YH. Risk factors affecting progressive collapse of acute osteoporotic spinal fractures [J]. *Osteoporos Int*, 2013, 24(4): 1207-1213.

[21] Wu AM, Chi YL, Ni WF. Vertebral compression fracture with intravertebral vacuum cleft sign: pathogenesis, image, and surgical intervention [J]. *Asian Spine J*, 2013, 7(2): 148-155.

[22] Matzaroglou C, Georgiou CS, Panagopoulos A, et al. Kümmell's disease: clarifying the mechanisms and patients' inclusion criteria [J]. *Open Orthop J*, 2014, 8: 288-297.

[23] Yu W, Liang Y, Yao Z, et al. Risk factors for recollapse of the augmented vertebrae after percutaneous vertebroplasty for osteoporotic vertebral fractures with intravertebral vacuum cleft [J]. *Medicine (Baltimore)*, 2017, 96(2): e5675.

[24] 倪文飞, 徐华梓, 池永龙, 等. 椎体裂隙征对经皮后凸成形术疗效的影响 [J]. *中华外科杂志*, 2012, 50(3): 251-255.
NI WF, XU HZ, CHI YL, et al. Influence of intravertebral cleft for outcome of percutaneous kyphoplasty [J]. *Zhonghua Wai Ke Za Zhi*, 2012, 50(3): 251-255. Chinese.

[25] Wu AM, Lin ZK, Ni WF, et al. The existence of intravertebral cleft impact on outcomes of nonacute osteoporotic vertebral compression fractures patients treated by percutaneous kyphoplasty: a comparative study [J]. *J Spinal Disord Tech*, 2014, 27(3): E88-E93.

[26] Huang Y, Peng M, He S, et al. Clinical efficacy of percutaneous kyphoplasty at the hyperextension position for the treatment of osteoporotic Kümmell disease [J]. *Clin Spine Surg*, 2016, 29(4): 161-166.

[27] Wu AM, Ni WF, Weng W, et al. Outcomes of percutaneous kyphoplasty in patients with intravertebral vacuum cleft [J]. *Acta Orthop Belg*, 2012, 78(6): 790-795.

[28] Yu W, Jiang X, Liang, et al. Intravertebral vacuum cleft and its varied locations within osteoporotic vertebral compression fractures: effect on therapeutic efficacy [J]. *Pain Physician*, 2017, 20(6): E979-E986.

[29] Fang X, Yu F, Fu S, et al. Intravertebral clefts in osteoporotic compression fractures of the spine: incidence, characteristics, and therapeutic efficacy [J]. *Int J Clin Exp Med*, 2015, 8(9): 16960-16968.

(收稿日期:2020-09-14 本文编辑:王宏)

颈椎前路 Hybrid 术在治疗颈椎退行性疾病中对活动度和曲度的影响

齐英娜¹, 李春根¹, 赵凯¹, 柳根哲¹, 尹辛成¹, 彭亚¹, 曾俊², 陈海东³, 郭雨霞²

(1.首都医科大学附属北京中医医院骨科, 北京 100010; 2.北京中医药大学, 北京 100029; 3.首都医科大学, 北京 100069)

【摘要】 目的:观察颈椎前路 Hybrid 术后 6 个月影像学上颈椎曲度和活动度的变化。方法:回顾性分析 2017 年 1 月至 2018 年 7 月接受颈椎前路 Hybrid 术的颈椎退行性疾病患者,符合纳入标准并获得术前和术后 6 个月影像学资料者 29 例。男 11 例,女 18 例,年龄 34~76(55.86±10.69)岁,手术时间 2~4(3.03±0.51)h。采用 Cobb 角法测量术前和术后 6 个月颈椎 X 线侧位片上 C₂-C₇、置换、融合及上位相邻节段曲度和活动度的变化。结果:术后 6 个月 C₂-C₇ 曲度和活动度与术前比较,差异无统计学意义 (P>0.05);置换节段曲度和活动度较术前增加 (P<0.05);融合节段曲度较术前增加 (P<0.05),融合节段活动度与术前比较,差异无统计学意义 (P>0.05);上位相邻节段的曲度和活动度与术前比较,差异无统计学意义 (P>0.05)。横向比较:术前和术后 6 个月时置换和融合节段曲度比较,差异均无统计学意义 (P>0.05);术后 6 个月置换节段活动度高于融合节段活动度 (P<0.05)。结论:颈椎前路 Hybrid 术重建了颈椎整体和责任节段的前凸曲度,保留了颈椎置换节段活动度,恢复了颈椎整体生物力学功能。

【关键词】 颈椎退行性疾病; 外科手术; Hybrid 术; 活动范围, 关节

中图分类号:R681.5

DOI: 10.12200/j.issn.1003-0034.2021.08.003

开放科学(资源服务)标识码(OSID):



Efficacy of Hybrid anterior cervical spine surgery on range of motion and curvature in the treatment of cervical degenerative diseases QI Ying-na, LI Chun-gen, ZHAO Kai*, LIU Gen-zhe, YIN Xin-cheng, PENG Ya, ZENG Jun, CHEN Haidong, and GUO Yu-xia. *Department of Orthopaedics, Beijing Hospital of Traditional Chinese Medicine, Capital Medical University, Beijing 100010, China

通讯作者:赵凯 E-mail:zhaokai67929@sina.com

Corresponding author: ZHAO Kai E-mail: zhaokai67929@sina.com

ABSTRACT Objective: To observe the change of cervical curvature and range of motion (ROM) on imaging at 6 months after Hybrid surgery. **Methods:** A total of 29 patients with cervical degenerative disease who underwent Hybrid surgery from January 2017 to July 2018 were retrospectively analyzed. Also, they all met the inclusion criteria and had complete preoperative and 6 months postoperative imaging data. There were 11 males and 18 females, aged from 34 to 76 (55.86 ± 10.69) years, and the operation time was from 2 to 4 (3.03 ± 0.51) hours. The Cobb angle method was used to measure the changes of cervical curvature and ROM of C₂-C₇, replacement segments, fusion segments, and upper adjacent segments on cervical lateral X-rays before and 6 months after surgery. **Results:** There was no statistically significant difference in C₂-C₇ curvature and ROM between 6 months after operation and before operation ($P > 0.05$). The degree of curvature and ROM of the replacement segment increased compared with that before operation ($P < 0.05$). The curvature of the fusion segment was increased than that before operation ($P < 0.05$). There was no statistically significant difference in ROM of the fusion segment compared with that before operation ($P > 0.05$). There was no statistically significant difference in the curvature and ROM of the upper adjacent segments compared with those before operation ($P > 0.05$). There was no significant difference in the curvature between the replacement and fusion segments before and 6 months after operation ($P > 0.05$); the ROM of the replacement segment was higher than that of the fusion segment at 6 months after operation ($P < 0.05$). **Conclusion:** Hybrid surgery reconstructs the lordotic curvature of the entire cervical spine and the responsible segment, retains the ROM of the cervical replacement segment, and restores the biomechanical function of cervical spine.

KEYWORDS Cervical degenerative diseases; Surgical procedures, operative; Hybrid surgery; Range of motion, articular

随着电子设备的普及和现代科技的快速发展,伏案和低头族人群明显增加,直接导致颈椎退行性疾病(cervical degenerative diseases, CDD)呈现高发率和年轻化的趋势^[1]。采用颈椎前路手术治疗 CDD,目前已经达到共识,但是前路手术仍然包括颈椎前路椎间融合术(anterior cervical decompression and fusion, ACDF),人工间盘置换术(total disc replacement, TDR)和二者联合的 Hybrid 术^[2-6]。目前多项研究证明 Hybrid 术临床疗效满意^[7-8],但针对其对颈椎活动度和曲度的改变,目前研究多单一测量颈椎曲度或相邻节段活动度,缺乏对同一批患者的详细评价^[9-10]。因此,此次研究采用回顾性研究,详细测量颈椎前路 Hybrid 术治疗前后影像学上颈椎曲度和活动度的变化,现报告如下。

1 资料与方法

1.1 病例选择

纳入标准:年龄 20~70 岁;影像学(X 线,CT, MRI)显示髓核突出,椎关节僵硬,或间盘高度丢失;非手术治疗 6 周无效;患者知情并签署知情同意书。排除标准:连续性后纵韧带骨化和(或)黄韧带骨化同时存在(节段 ≥ 3 个);已知的对内置物材料过敏史(钛,聚乙烯,钴,铬,钼);不明原因的颈部和手臂疼痛;轴性颈部疼痛作为孤立的症状;严重骨质疏松/骨量不足;目标节段既往手术史;活动期局部或全身性感染;自身免疫脊椎关节病(风湿性关节炎);临床资料及影像学资料不完整患者;随访期间新出现其他影响颈椎退行性疾病临床和影像学评估的疾病:脑血管病、类风湿性关节炎、骨折、肿瘤等。

1.2 临床资料

2017 年 1 月至 2018 年 7 月,首都医科大学附

属北京中医医院行颈椎前路 Hybrid 术治疗的 CDD 住院患者共 75 例,符合病例选择标准并获得完整影像学随访资料者 29 例,所有患者为 I 期融合术联合 TDR 手术,手术节段为 2 节段者 18 例,3 节段者为 11 例;C₄-C₆ 者 8 例,C₅-C₇ 者 8 例,C₆-T₁ 者 2 例,C₃-C₆ 者 3 例,C₄-C₇ 者 8 例。单节段 TDR+单节段 ACDF 18 例,单节段 TDR+双节段 ACDF 10 例,单节段 TDR+双节段 ACCF (anterior cervical corpectomy decompression and fusion, ACCF) 1 例。男 11 例,女 18 例,年龄 34~76 (55.86 ± 10.69) 岁,手术时间 2~4 (3.03 ± 0.51) h。此次研究通过本院伦理委员会批准并遵守赫尔辛基宣言。

1.3 治疗方法

1.3.1 术前准备 完善术前颈椎 X 线、CT 和 MRI 的影像学检查,明确责任节段。节段选择^[11]:间盘置换节段选择相对较轻和生理颈椎活动度较大的节段(C₅-C₆ > C₄-C₅ > C₆-C₇ > C₃-C₄)。融合节段选择退变相对较重和有颈椎不稳的节段。退变相对较重为严重椎关节僵硬(桥状骨化,椎间高度丢失 > 50%,活动度丢失 < 2%);颈椎不稳为椎体位移 > 3 mm 和(或) > 11° 旋转改变。术前 3~4 d 指导患者行气管推移训练。

1.3.2 手术步骤 全麻下颈椎呈中立位或轻度过伸位。以标准 3~5 cm 切口经颈动脉鞘和内脏鞘间进入,暴露椎间隙,C 形臂 X 线定位责任节段。在辅助放大镜下,采用高速磨钻,仔细清除椎前骨赘和骨化的前纵韧带,摘除突出的椎间盘。必要时切开前后纵韧带,以探查突出的间盘组织。采用大小适宜装有同种异体骨和(或)自体骨的 ROI-C 融合器和人工间盘置入椎间隙,透视置入物位置良好,充分清洗切口,检查无活动性出血后留置引流管,逐层缝合切口。

1.3.3 术后处理 绝对卧床观察 24 h, 拔除引流管并在颈托保护下下地活动, 颈托佩戴 1~2 周。术后常规采用非甾体抗炎药、甘露醇、地塞米松和质子泵抑制剂治疗 5 d, 手术均由相同的 3 个术者完成。

1.4 观察项目与方法

术前和术后 6 个月时采用 Cobb 角测量法^[12]于颈椎 X 线侧位片上测量 C₂-C₇、置换、融合及上位相邻节段曲度活动度, 颈椎活动度为过伸过屈位曲度之和。由经过培训的非此次试验相关的 2 个骨科研究生在院内 Rogan Delft View Pro-X 软件上测量, 采用 Cobb 角测量法由双人测量、录入的方式采集数据, 建立 Epidata 数据库, 存在争议时由第 3 人进行确定。

1.5 统计学处理

统计软件采用 SPSS 19.0 软件, 定量资料以均数±标准差($\bar{x}\pm s$)表示, 计数资料以 n(%) 表示。C₂-C₇ 曲度和活动度、置换节段曲度和活动度、融合节段曲度、上位相邻节段曲度治疗前后比较采用配对样本 *t* 检验; 融合节段活动度、上位相邻节段活动度治疗前后比较采用非参数检验; 置换和融合节段曲度的横向比较采用独立样本 *t* 检验; 置换和融合节段活动度的横向比较采用非参数检验; 双侧检验, 均以 *P*<0.05 为差异有统计学意义。

2 结果

2.1 Hybrid 术治疗前后颈椎曲度的变化

术后 6 个月和术前颈椎曲度变化比较: C₂-C₇ 曲度与术前比较, 差异无统计学意义 (*P*>0.05); 置换和融合节段曲度较术前明显改善 (*P*<0.05); 上位相邻节段曲度与术前比较, 差异无统计学意义 (*P*>0.05)。横向比较置换和融合节段的曲度: 术前和术后 6 个月时差异均无统计学意义 (*t*=-1.309, *P*=0.201; *t*=1.898, *P*=0.068)。见表 1。

表 1 颈椎退行性疾病 29 例患者 Hybrid 治疗前后颈椎曲度的变化($\bar{x}\pm s, ^\circ$)

Tab.1 Comparison of cervical curvature of 29 patients with cervical degenerative diseases before and after Hybrid surgery($\bar{x}\pm s, ^\circ$)

时间	C ₂ -C ₇	置换节段	融合节段	上位相邻节段
术前	9.71±10.30	3.23±4.39	2.05±3.79	3.83±3.66
术后 6 个月	11.19±9.63	8.39±5.82	5.47±6.00	3.24±3.86
<i>t</i> 值	-0.773	-4.913	-2.277	0.855
<i>P</i> 值	0.446	0.000	0.021	0.400

2.2 Hybrid 治疗前后颈椎活动度的变化

术后 6 个月和术前颈椎活动度变化比较: C₂-C₇

活动度与术前比较, 差异无统计学意义 (*P*>0.05); 置换节段活动度较术前明显改善 (*P*<0.05); 融合和上位相邻节段活动度与术前比较, 差异无统计学意义 (*P*>0.05)。横向比较置换和融合节段的活动度: 术前差异无统计学意义 (*Z*=0.725, *P*=0.469); 术后 6 个月置换节段的活动度高于融合节段的活动度 (*Z*=2.855, *P*=0.004)。见表 2。典型病例影像学资料见图 1。

表 2 颈椎退行性疾病 29 例患者 Hybrid 治疗前后颈椎活动度的变化($\bar{x}\pm s, ^\circ$)

Tab.2 Comparison of cervical ROM of 29 patients with cervical degenerative diseases before and after Hybrid surgery($\bar{x}\pm s, ^\circ$)

时间	C ₂ -C ₇	置换节段	融合节段	上位相邻节段
术前	28.19±14.32	4.92±5.40	4.18±4.79	5.41±7.24
术后 6 个月	27.48±15.01	11.99±7.38	6.68±8.87	5.74±8.83
检验值	<i>t</i> =0.187	<i>t</i> =4.619	<i>Z</i> =1.384	<i>Z</i> =0.130
<i>P</i> 值	0.853	0.000	0.166	0.897

3 讨论

3.1 颈椎前路 Hybrid 治疗前后颈椎曲度的变化

颈椎退行性疾病影像学上表现为颈椎曲度变直、反张和(或)颈椎活动度减小, 神经和脊髓活动空间减小, 受压后产生放射性或髓性相关症状。颈椎前路手术在充分减压后, 置入间盘和(或)融合器, 可部分恢复颈椎的曲度和活动度, 临床疗效满意^[13-15]。国内学者李晋玉等^[16]测量了单纯 Bryan 颈椎间盘置换术后颈椎曲度和活动度的变化, 结果表明颈椎整体曲度由术前 (10.64±4.26)[°]增加至 (13.68±4.56)[°], 与此次研究结果相似, 但该研究未测量置换节和相邻节段的曲度。此次研究中术后 6 个月时颈椎置换和融合节段曲度较术前明显改善 (*P*<0.05), C₂-C₇、上位相邻节段曲度与术前比较, 差异无统计学意义 (*P*>0.05), 表明颈椎前路 Hybrid 手术可以较好地改善责任节段的曲度。

3.2 颈椎前路 Hybrid 治疗前后颈椎活动度的变化

部分生物力学研究表明此类“非常规”的使用方法即 Hybrid 术会导致应用于融合部位相邻节段的人工椎间盘假体屈伸活动度降低^[17], 进而导致置换节段的异位骨化和相邻节段退变率增加, 此次研究中置换节段活动度明显改善, 长期是否会出现活动度减低, 仍需要进一步深入观察。刘海鹰等^[18]测量了双节段 Hybrid 术和 ACDF 术治疗后颈椎活动度的变化: Hybrid 术颈椎整体活动度由术前的 (46.00±11.00)[°]降低至术后的 (41.00±8.00)[°], 此次研究中术后 6 个月 C₂-C₇ 活动度与术前比较, 差异无统计学

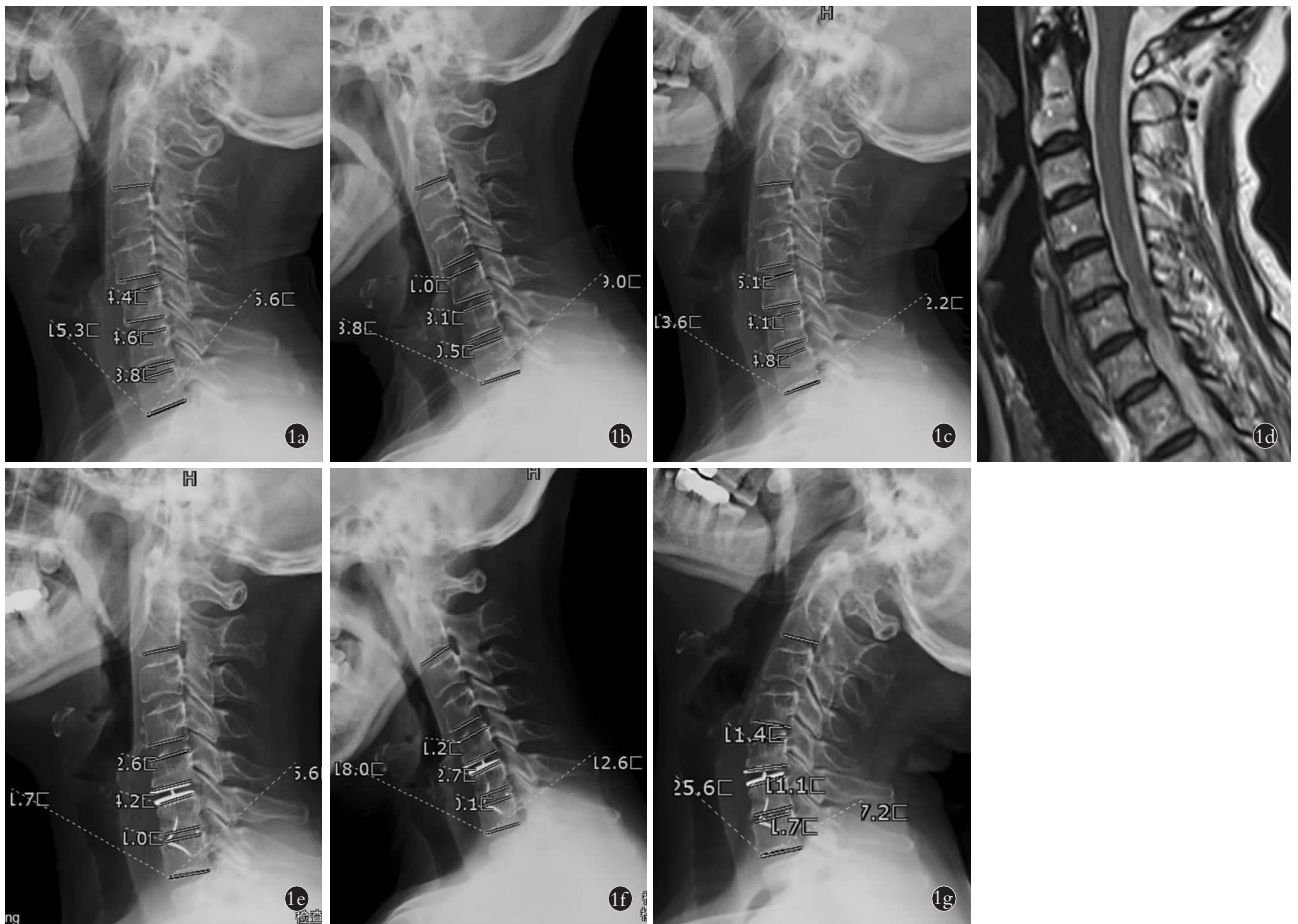


图 1 患者,女,67岁,神经根型颈椎病,颈肩疼痛伴左手桡侧三指疼痛、麻木半年,加重9d。采用 Hybrid 术治疗(C₅-C₆人工间盘置换术和 C₆-C₇颈椎前路椎间融合术) **1a,1b,1c**。术前侧位 X 线片显示颈椎整体曲度和活动度减少 **1d**。颈椎 MRI 显示 C₅-C₇ 椎间盘突出,相应椎管狭窄 **1e,1f,1g**。Hybrid 术后 6 个月颈椎侧位 X 线片显示颈椎曲度和活动度明显改善,人工间盘和椎间融合器位置良好

Fig.1 A 67-year-old female patient was diagnosed with cervical spondylotic radiculopathy, presenting as neck and shoulder pain with radial side of the left hand pain and numbness for half a year, aggravating for 9 days. The patient was treated by Hybrid surgery (C₅-C₆ artificial total disc replacement and C₆-C₇ anterior cervical decompression and fusion) **1a,1b,1c**. The preoperative lateral X-rays showed that the overall curvature and range of motion of the cervical spine were reduced **1d**. Cervical MRI showed C₅-C₇ intervertebral disc herniation and corresponding spinal stenosis **1e,1f,1g**. Six months after Hybrid surgery, the lateral X-rays showed that the curvature and range of motion of the cervical spine were significantly improved, and the position of the artificial disc and interbody fusion cage was good

意义($P>0.05$)。最早提出的颈前路减压融合术,其核心理念是在充分减压的基础上促进骨性融合,而颈椎前路间盘置换术的核心理念是保留颈椎的生理活动度^[11,19-21]。2009年 Kim 等^[21]提出 Hybrid 术式,在保证临床疗效的基础上兼顾人工颈椎间盘置换术与颈前路椎间融合术,也有部分生物力学研究显示这种非常规的手术会导致应用于融合部位相邻节段的人工椎间盘假体屈伸活动度降低,但在此次研究结果表明,置换节段活动度较术前明显改善($P<0.05$),由术前(4.92 ± 5.40)°增加至术后(11.99 ± 7.38)°,证实了该术式保留颈椎活动度的作用。

综上,颈椎前路 Hybrid 术重建了颈椎和责任节段的前凸曲度,保留了颈椎置换节段活动度,恢复了颈椎整体生物力学功能。但此次研究仍存在以下缺

点:此次研究为回顾性分析,缺乏前瞻性、对照研究,而且此次研究样本量偏少,随访时间偏短。

参考文献

- [1] 吴云霞,刘忠军,刘晓光,等. 2008-2014 年北医三院骨科脊柱退行性疾病的住院人群特征分析[J]. 中国脊柱脊髓杂志, 2016,26(1):70-76.
WU YX, LIU ZJ, LIU XG, et al. An analysis of social characteristics of hospitalized spinal degenerative disease patients in the orthopedic department of Peking University Third Hospital during a period of 2008 to 2014[J]. Zhongguo Ji Zhu Ji Sui Za Zhi, 2016,26(1): 70-76. Chinese.
- [2] Yang SD, Zhu YB, Yan SZ, et al. Anterior cervical discectomy and fusion surgery versus total disc replacement: A comparative study with minimum of 10-year follow-up[J]. Scientific Reports, 2017,7(7):1-7.
- [3] Litrico S, Lonjon N, Riouallon G, et al. Adjacent segment disease

- after anterior cervical interbody fusion. A multicenter retrospective study of 288 patients with long-term follow-up[J]. *Orthop Traumatol Surg Res*, 2014, 100(6):305-309.
- [4] Shriver MF, Lubelski D, Sharma AM, et al. Adjacent segment degeneration and disease following cervical arthroplasty: a systematic review and meta-analysis[J]. *Spine J*, 2016, 16(2):168-181.
- [5] Kong L, Meng F, Cao J, et al. The prevalence of heterotopic ossification among patients after cervical artificial disc replacement[J]. *Medicine*, 2017, 96(24):7163.
- [6] Walker AE, Riley LH, Robinson RA, et al. The results of anterior interbody fusion of the cervical spine[J]. *J Neurosurg*, 1969, 30(2):127-133.
- [7] 贾育松, 陈江, 孙旗, 等. 颈椎前路 Hybrid 手术保留颈后纵韧带的临床意义[J]. *中国骨伤*, 2015, 31(1):26-30.
JIA YS, CHEN J, SUN Q, et al. Clinical study of a cervical anterior Hybrid technique with posterior longitudinal ligament retained for cervical spondylosis[J]. *Zhongguo Gu Shang/China J Orthop Trauma*, 2015, 31(1):26-30. Chinese with abstract in English.
- [8] 张耐洋, 彭宝淦. Hybrid 术式治疗多节段颈椎病的短中期临床疗效研究[J]. *军事医学*, 2017, 41(6):520-523, 529.
ZHANG NY, PENG BG. Short-and medium-term clinical outcomes of Hybrid surgery for the treatment of multilevel cervical spondylosis[J]. *Jun Shi Yi Xue*, 2017, 41(6):520-523, 529. Chinese.
- [9] 陈江, 贾育松, 孙旗, 等. 双节段颈椎间盘置换联合 cage 融合术治疗颈椎病[J]. *临床骨科杂志*, 2014, 17(4):361-364, 368.
CHEN J, JIA YS, SUN Q, et al. Clinical study of a cervical anterior hybrid technique with Bi-level Bryan artificial disc replacement and nearby segment fusion for cervical myelopathy[J]. *Lin Chuang Gu Ke Za Zhi*, 2014, 17(4):361-364, 368. Chinese.
- [10] 段硕, 朱震奇, 钱亚龙, 等. 颈椎前路椎间融合术与人工椎间盘置换术联合椎间融合术治疗连续双节段颈椎病的中长期疗效对比[J]. *中国脊柱脊髓杂志*, 2017, 27(11):1004-1012.
DUAN S, ZHU ZQ, QIAN YL, et al. Anterior cervical discectomy and fusion vs combined with cervical artificial disc replacement in bi-level cervical disc degenerative disease: a mid- and long-term follow-up study[J]. *Zhongguo Ji Zhu Ji Sui Za Zhi*, 2017, 27(11):1004-1012. Chinese.
- [11] Auerbach JD, Jones KJ, Fras CI, et al. The prevalence of indications and contraindications to cervical total disc replacement[J]. *Spine J*, 2008, 8(5):711-716.
- [12] Harrison DE, Harrison DD, Cailliet R, et al. Cobb method or Harrison posterior tangent method: Which to choose for lateral cervical radiographic analysis[J]. *Spine (Phila Pa 1976)*, 2000, 25(16):2072-2078.
- [13] Wu B. Comparison of Hybrid constructs with 2-level artificial disc replacement and 2-level anterior cervical discectomy and fusion for surgical reconstruction of the cervical spine: a kinematic study in whole cadavers[J]. *Med Sci Monitor*, 2015, 21:1031-1037.
- [14] Tian P, Fu X, Li ZJ, et al. Hybrid surgery versus anterior cervical discectomy and fusion for multilevel cervical degenerative disc diseases: A meta-analysis[J]. *Sci Rep*, 2015, 5(8):1-8.
- [15] Alvin MD, Mroz TE. The Mobi-C cervical disc for one-level and two-level cervical disc replacement: a review of the literature[J]. *Med Dev Eviden Res*, 2014, 7:397-403.
- [16] 李晋玉, 贾育松, 郑晨颖, 等. Bryan 颈椎间盘置换在治疗颈椎病中对颈椎曲度和置换节段的影响[J]. *中国骨伤*, 2018, 31(8):751-756.
LI JY, JIA YS, ZHENG CY, et al. Effect of Bryan cervical disc replacement on cervical curvature and replacement segment in treating cervical spondylosis[J]. *Zhongguo Gu Shang/China J Orthop Trauma*, 2018, 31(8):751-756. Chinese with abstract in English.
- [17] 姜建元. 理性认识邻近节段退变, 慎重开展颈椎混合术式[J]. *中国脊柱脊髓杂志*, 2014, 24(1):11-12.
JIANG JY. Rational understanding of adjacent segment degeneration, and cautious performing of cervical hybrid surgery[J]. *Zhongguo Ji Zhu Ji Sui Za Zhi*, 2014, 24(1):11-12. Chinese.
- [18] 刘海鹰, 许晓诺, 王波, 等. 双节段 Hybrid 手术治疗颈椎病的临床疗效观察[J]. *中华外科杂志*, 2012, 50(3):238-242.
LIU HY, XU XN, WANG B, et al. Clinical outcomes of Hybrid-Surgery to treat the two-level cervical disease[J]. *Zhonghua Wai Ke Za Zhi*, 2012, 50(3):238-242. Chinese.
- [19] Chang P, Chang H, Wu J, et al. Is cervical disc arthroplasty good for congenital cervical stenosis[J]. *Spine (Phila Pa 1976)*, 2017, 26(5):577-585.
- [20] Wu TK, Meng Y, Wang BY, et al. Is the behavior of disc replacement adjacent to fusion affected by the location of the fused level in hybrid surgery[J]. *Spine J*, 2018, 18(12):2171-2180.
- [21] Kim KN, Yoon DH, Shin DA, et al. Artificial disc replacement combined with fusion versus two-level fusion in cervical two-level disc disease[J]. *Spine (Phila Pa 1976)*, 2009, 34(11):1153-1159.

(收稿日期:2020-04-17 本文编辑:王宏)