·经验交流·

# 负压封闭引流结合间断开窗技术在大面积跟腱外露创面修复中的使用体会

车永琦,赵建强,翟伟,王文亮,王军成,亢向辉
(宝鸡市电子 409 医院,陕西　宝鸡　721006)

【摘要】 **目的**:总结应用负压封闭引流(VSD)结合间断开窗技术促进大面积跟腱外露创面肉芽组织生长后植皮修复的临床效果。**方法**:2009 年 7 月至 2014 年 5 月收治跟腱大面积外露创面患者 11 例,其中男 5 例,女 6 例;年龄 7~65 岁,平均 43 岁。重物擦挫伤致皮肤坏死 4 例,胫腓骨远端骨折术后皮肤坏死 3 例,车轮夹伤致皮肤坏死 3 例,糖尿病致皮肤坏死 1 例。跟腱外露面积 6 cm×3 cm~14 cm×5 cm,均无跟腱断裂及骨质外露。清创后于跟腱表面以尖刀片和跟腱纵轴平行间断开窗,结合负压封闭引流(VSD)治疗。**结果**:所有创面经 1 个 VSD 周期(5~7 d)吸引后,均有丰富新鲜肉芽组织生成,Ⅱ期植皮后均成活。患者均获随访,时间 12~24 个月,皮片色泽良好,质地柔软,无破溃。术后 3~4 个月皮片下即有皮下脂肪生成,皮肤滑动满意,踝关节活动良好。无迟发型跟腱断裂发生。**结论**:负压封闭引流(VSD)结合间断开窗技术修复大面积跟腱外露创面,简便易行,安全有效,可最大程度减少患者行皮瓣修复创面所带来的副损伤。

【关键词】 负压封闭引流;　跟腱;　软组织损伤;　皮肤开窗术;　外科手术
**DOI**:10.3969/j.issn.1003-0034.2015.12.020

**Vacuum sealing drainage combined with discontinuous windowing technique for repairing large area exposed wound of Achilles tendon**

*CHE Yong-qi, ZHAO Jian-qiang, ZHAI Wei, WANG Wen-liang, WANG Jun-cheng, and KANG Xiang-hui. Baoji Electron 409 Hospital, Baoji* 721006, *Shaanxi, China*

**ABSTRACT**　**Objective**: To explore clinical effect of vacuum sealing drainage (VSD) combined with discontinuous windowing technique for repairing large area exposed wounds of Achilles tendon. **Methods**: From July 2009 to May 2014, 11 patients with large exposed wounds of Achilles tendon were treated, including 5 males and 6 females with an average age of 43 years old (aged from 7 to 65 years old). Among them, 4 cases were skin necrosis caused by heavy objects abrasion and contusion; 3 cases were caused by distal tibiofibula fractures; 3 cases were caused by bicycle-spoke injuries; 1 case was caused by diabetes. Areas of exposed Achilles tendon were from 6 cm×3 cm to 14 cm×5 cm without tendon rupture or bone exposed. After debridement, discontinuous fenestration on Achilles tendon was made by knife blade parallel with longitudinal axis of Achilles tendon, combined with Vacuum Sealing Drainage (VSD) treatment. **Results**: After drainage treatment with one VSD cycle (5 to 7 days), abundant fresh granulation tissues were growing on all wounds and survived well after the second phase dermatoplasty. All patients were followed up for 12 to 24 months, the color of skin flap was good, the texture was soft without burst. At 3 to 4 months after operation, subcutaneous fat was appeared under the flap, the skin was sliding, movement of ankle joints was good. No delayed Achilles tendon rupture were occurred. **Conclusion**: Vacuum sealing drainage (VSD) combined with discontinuous fenestration is a simple, safe and effective method for repairing large area exposed wounds of Achilles tendon, which could minimize the secondary damage caused by wounds of skin flap grafting.

**KEYWORDS**　Vacuum sealing drainage (VSD);　Achilles tendon;　Soft tissue injuries;　Skin window technique;　Surgical procedures, operative

Zhongguo Gu Shang/China J Orthop Trauma, 2015, 28(12): 1153-1155　www.zggszz.com

各种原因引起的跟腱外露创面在临床越来越常见,如不及时修复常出现感染及坏死。但常规治疗需要使用小腿皮瓣转移修复[1],创伤较大。2009 年至 2014 年我科收住跟腱大面积外露创面患者 11 例。使用负压封闭引流(VSD)结合间断开窗技术促进创面肉芽组织生成后,Ⅱ期植皮,获得满意疗效,报告如下。

## 1　临床资料

本组 11 例患者,男 5 例,女 6 例;年龄 7~65 岁,平均 43 岁。重物擦挫伤致皮肤坏死 4 例,胫腓骨远端骨折术后皮肤坏死 3 例,车轮夹伤致皮肤坏死 3 例,糖尿病致皮肤坏死 1 例。跟腱外露面积 6 cm×3 cm~14 cm×5 cm。其中 2 例合并金黄色葡萄球菌感

通讯作者:车永琦　E-mail:cyqtt@126.com
Corresponding author: CHE Yong-qi　E-mail: cyqtt@126.com

染。均无骨质外露。

## 2　治疗方法

术前积极控制空腹血糖(≤8 mmol/L),创面换药控制感染(连续 2 次细菌培养阴性)后进行手术。Ⅰ期手术清除创面内坏死组织后，于跟腱表面以尖刀片和跟腱纵轴平行间断开窗。沿外露跟腱组织纵向切开长约 5 mm，横向间隔约 5~8 mm 再次切开长约 5 mm,以穿透跟腱为限;第 2 排切口与第 1 排间隔 5 mm,且切口位于第 1 排相邻两切口中间,如此在跟腱表面呈网状间断开窗后，以聚乙烯水化海藻盐泡沫敷料覆盖创面,医用透明贴膜封闭,持续负压吸引,压力-14~-16 kPa。连续吸引 1 个周期(5~7 d),拆除 VSD 敷料后,跟腱表面长满肉芽组织,即可自大腿或下腹部切取全厚皮片植皮，棉纱打包加压固定,12 d 后,拆除加压包,观察植皮成活情况。

## 3　结果

本组患者住院时间 19~35 d,平均 23 d。所有植皮均顺利成活。Ⅰ期术后 5~7 d 即可见跟腱表面有鲜红嫩活、饱满丰富的肉芽组织生长,且可完全覆盖跟腱。Ⅱ期植皮后,无合并感染发生,植皮均顺利成活。患者均获随访,时间 12~24 个月,皮片色泽良好,质地柔软,无破溃。术后 3~4 个月皮片下即有皮下脂肪生成,皮肤滑动满意,踝关节活动良好。无迟发型跟腱断裂发生。

## 4　讨论

### 4.1　大面积跟腱外露创面的特点

大面积跟腱外露创面常常需要切取腓肠神经营养支皮瓣、外踝上穿支皮瓣、内踝上穿支皮瓣等小腿部皮瓣转移修复,手术创伤较大,术区瘢痕显著,严重影响美观。且如患者高龄、患有糖尿病、合并下肢血液循环障碍等,行皮瓣修复手术风险明显增大。但以往行创面常规换药，或单纯负压封闭引流(VSD)治疗以期促进肉芽组织生长后植皮,因周期过长,外露跟腱极易坏死或肉芽组织生长不良，无法覆盖跟腱,从而无法植皮或植皮后部分坏死[2]。

### 4.2　负压封闭引流的应用

封闭式负压引流能增加创面血流量，刺激血管内皮生长因子等细胞增殖，促进创面的肉芽组织快速生长[3]。但在跟腱大面积外露创面单纯使用负压封闭引流(VSD)治疗,肉芽组织需要从跟腱周围筋膜组织生长后，逐渐爬行覆盖跟腱。常需要 3~5 个 VSD 周期(约 20~35 d),过程漫长,肉芽组织易老化,且常无法完全覆盖跟腱。根据跟腱组织的解剖特点,本组患者采用了跟腱表面间断开窗技术，使肉芽组

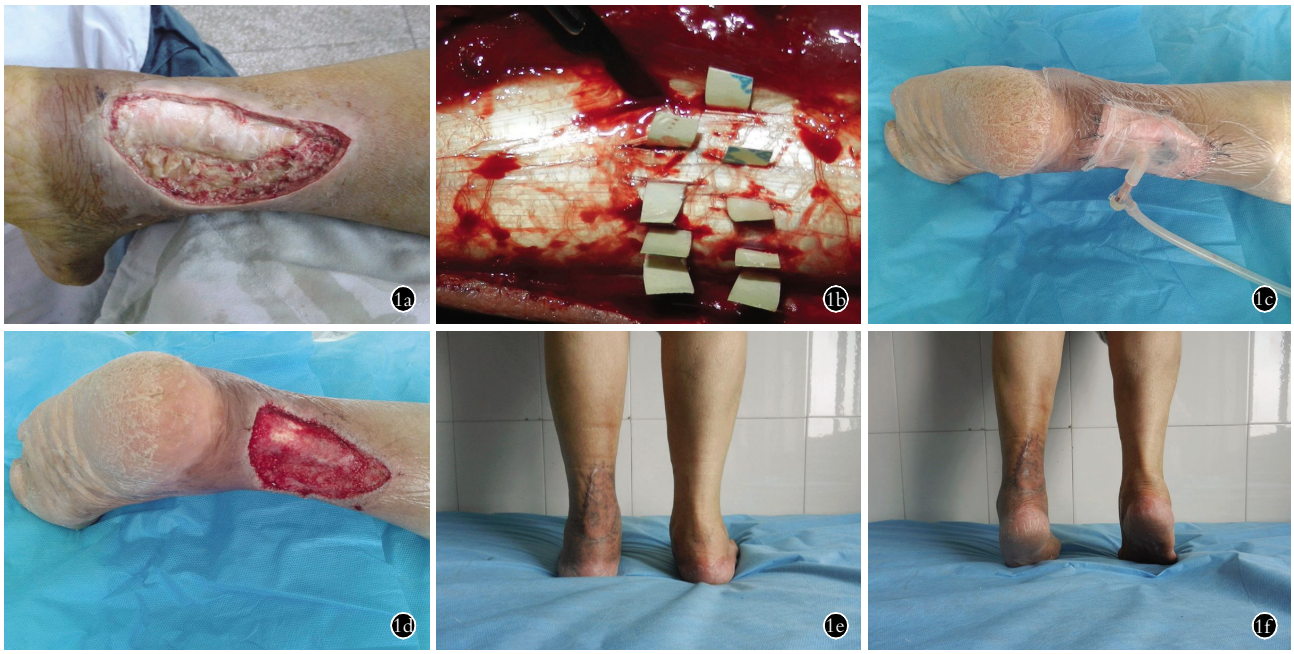


**图 1**　患者,女,65 岁,患糖尿病 30 余年。左小腿远端后侧擦挫伤后皮肤坏死　**1a.** 清创后可见大面积跟腱外露　**1b.** 行跟腱间断开窗术　**1c.** 行跟腱间断开窗后 VSD 吸引　**1d.** 拆除 VSD 后即可见肉芽组织生长良好,完全覆盖跟腱,可全厚皮片植皮　**1e.** 术后 1 年随访见皮片成活良好,质地柔软,滑动度满意　**1f.** 术后 1 年随访患足跖屈提踵不受限,功能良好

**Fig.1**　A 65-year-old female patient with more than 30 years diabetes. Skin scratch and bruise injuries on distal near side of left calf　**1a.** Large exposed wounds of Achilles tendon were observed after debridement　**1b.** discontinuous windowing technique of Achilles tendon　**1c.** VSD drainage after discontinuous windowing technique　**1d.** After VSD removal, good growth of granulation tissue was observed covering on Achilles tendon completely and full-thickness skin grafting could be performed　**1e.** At 1 year after operation, skin grafts survived well which were soft and gliding smoothly over the underlying tissues　**1f.** At 1 year after operation, involved feet function was well, motion of plantar flexion and heel raise were not restricted

织从跟腱前方及跟腱中穿行的血管组织周围生长，肉芽组织生长快速，质地良好，可自开窗部位直接覆盖跟腱。且本组患者均采用全厚皮片植皮，植皮成活后，皮肤质地柔软、耐磨，不易挛缩，对踝关节功能影响小。

**4.3　跟腱表面间断开窗术的应用**

跟腱是由小腿三头肌肌腱合成，由弹力纤维和胶原纤维一起组成的复合材料样结构，纵行向下止于跟骨结节，腱中段血供最差，通常损伤后最易自腱中段断裂[4]。在跟腱表面进行间断开窗，切口与跟腱纵轴平行，对跟腱的腱纤维损伤最小。且通过负压封闭引流的使用，增加了局部血液循环，刺激了血管内皮生长因子的生成，在生长肉芽组织的同时，可使开窗部位的跟腱组织快速愈合[5]，不影响跟腱的拉伸性能和强度。本组患者通过随访，无一例出现迟发型跟腱断裂。

**4.4　本手术方式的缺点**

(1)需要分期手术，增加了患者的住院时间及费用；(2)负压封闭引流材料较昂贵，限制了在临床中广泛应用；(3)术中如果操作不当，刀片切入过深，有可能损伤跟腱前方滑囊，造成术后慢性疼痛；(4)如患者为瘢痕体质，术后有可能因植皮部位瘢痕组织挛缩致踝关节活动受限。

总之，针对儿童患者，或对小腿外形美观要求较高的患者及伴有下肢血液循环障碍的老年跟腱大面积外露的患者，采用负压封闭引流(VSD)结合间断开窗技术修复创面，简便易行，安全有效，可最大程度减少患者治疗的副损伤，是治疗此类疾病较好的手术方式。

**参考文献**

[1] 张功林，甄平. 修复四肢软组织缺损应注意的几个问题[J]. 中国骨伤，2013，26(8)：621-623.
Zhang GL, Zhen P. Several problems should be paid attention for repairing soft tissue defect in extremities[J]. Zhongguo Gu Shang/China J Orthop Trauma, 2013, 26(8): 621-623. Chinese.

[2] 刘华水，楚万忠，栾涛，等. 闭式负压引流联合带腓肠神经营养血管皮瓣修复近踝足部肌腱与骨外露创面[J]. 中国骨伤，2010，23(8)：613-615.
Liu HS, Chu WZ, Luan T, et al. Analysis of the vacuum sealing drainage technique combined with sural neurovasculr pedicle fasciocutaneous flap to repair deep wounds in the foot near the ankle joint with exposed bone and tendons[J]. Zhongguo Gu Shang/China J Orthop Trauma, 2010, 23(8): 613-615. Chinese with abstract in English.

[3] 黄雷，张锋，叶鹏翰，等. 负压封闭引流在开放性足踝部骨折脱位中的应用[J]. 中国骨伤，2012，25(8)：651-653.
Huang L, Zhang F, Ye PH, et al. Application of vacuum sealing drainage in open ankle fracture and dislocation[J]. Zhongguo Gu Shang/China J Orthop Trauma, 2012, 25(8): 651-653. Chinese with abstract in English.

[4] 周洪翔，宁涛，李超. 陈旧性跟腱断裂的诊治进展[J]. 中国骨与关节损伤杂志，2011，26(12)：1149-1150.
Zhou HX, Ning T, Li C. The diagnosis and treatment of chronic Achilles tendon rupture[J]. Zhongguo Gu Yu Guan Jie Sun Shang Za Zhi, 26(12): 1149-1150. Chinese.

[5] 何爱咏，莫挺挺. 血管内皮生长因子对兔跟腱内源性愈合作用的量效关系[J]. 中国组织工程研究与临床康复，2009，13(37)：7335-7340.
He AY, Mo TT. Concentration-response relationship of vascular endothelial growth factor on rabbit Achilles tendon endogenous healing [J]. Zhongguo Zu Zhi Gong Cheng Yan Jiu Yu Lin Chuang Kang Fu, 2009, 13(37): 7335-7340. Chinese.

(收稿日期：2014-10-20　本文编辑：王玉蔓)