

· 经验交流 ·

膝上外侧动脉穿支髂胫束皮瓣修复腘窝部 瘢痕挛缩

郑鑫, 安洪宾, 陈滔, 王海宝
(台州市立医院, 浙江 台州 318000)

【摘要】 目的:探讨膝上外侧动脉穿支髂胫束皮瓣治疗腘窝部瘢痕挛缩的临床疗效,为腘窝区瘢痕挛缩寻找最佳的手术方式。**方法:**自 2009 年 1 月至 2011 年 12 月,应用膝上外侧动脉穿支髂胫束动脉皮瓣修复腘窝瘢痕挛缩 11 例,男 7 例,女 4 例;年龄 24~58 岁,平均 33 岁;病程 3 个月~1 年,平均 6.5 个月;右膝关节 8 例,左膝关节 3 例;交通伤 5 例,热压伤 3 例,烧伤 3 例。采用膝上外侧动脉穿支髂胫束皮瓣局部转移修复创面,切取皮瓣面积最大 20.0 cm×8.0 cm,最小 7.0 cm×4.0 cm。**结果:**术后皮瓣全部成活,3 例远端血运差,局部色素沉着,表皮坏死脱痂。术后随访 5 个月~2 年,膝关节活动均恢复正常,皮瓣外形良好,皮肤松紧度适中。**结论:**膝上外侧动脉穿支髂胫束皮瓣实用性好,手术操作简单,是修复腘窝区瘢痕挛缩是较为理想的皮瓣选择。

【关键词】 膝关节; 外科皮瓣; 瘢痕; 挛缩

DOI: 10.3969/j.issn.1003-0034.2013.02.011

The lateral superior genicular artery perforator iliotibial band flap for the treatment of scar contraction of popliteal fossa ZHENG Xin, AN Hong-bin, CHEN Tao, and WANG Hai-bao. Department of Hand Surgery, Taizhou Municipal Hospital, Taizhou 318000, Zhejiang, China

ABSTRACT Objective: To discuss clinical results of the lateral superior genicular artery perforator iliotibial band flap for the treatment of scar contracture of popliteal fossa. **Methods:** From January 1999 to December 2011, 11 patients with scar contraction of popliteal fossa were treated with the lateral superior genicular artery perforator iliotibial band flap. Among the patients, 7 patients were male and 4 patients were female, ranging in age from 24 to 58 years old, with an average of 33 years old. The operation time ranged from 3 months to 1 year after trauma. Eight patients had injuries in the right side and 3 patients had the injuries in the left. Five patients had the injuries caused by traffic, 3 patients had the injuries caused by hot compression and other 3 patients suffered from burns. The flap area ranged from 7.0 cm×4.0 cm to 20.0 cm×8.0 cm. **Results:** All the flaps survived. Three patients had epidermis necrosis. After 5 months to 2 years follow-up period, the knee function recovered, the flap shape was favorable and the skin firmness was moderated. **Conclusion:** The lateral superior genicular artery perforator iliotibial band flap is a practical, simple and an ideal donor in the reconstruction of popliteal fossa scar contracture.

KEYWORDS Knee joint; Surgical flaps; Cicatrix; Contraction

Zhongguo Gu Shang/China J Orthop Trauma, 2013, 26(2): 128-130 www.zggszz.com

腘窝部损伤如外伤、热压伤、烧伤等在临床上越来越常见,严重者导致腘窝皮肤坏死损伤,导致腘窝部皮肤瘢痕挛缩,严重影响膝关节的正常屈伸功能。自 2009 年 1 月至 2011 年 12 月,应用膝上外侧动脉穿支髂胫束皮瓣^[1-2]修复腘窝部瘢痕挛缩 11 例,取得满意的效果,报告如下。

1 临床资料

本组 11 例,男 7 例,女 4 例;年龄 24~58 岁,平均 33 岁。病程 3 个月~1 年,平均 6.5 个月。右膝关节 8 例,左膝关节 3 例。交通伤 5 例,热压伤 3 例,烧伤 3 例。最大面积 20.0 cm×8.0 cm,最小面积 7.0 cm×

4.0 cm。

2 手术方法

2.1 皮瓣设计 根据皮瓣设计“点、线、面”的原则,患肢屈膝位,以大腿外侧正中线为轴心线,股骨外上髁以近 4.0 cm 处动脉穿支入皮点为旋转点。髌骨外侧缘向近端延长线为皮瓣的前缘,股二头肌后缘为皮瓣的后缘,下界为髌骨上缘水平线,根据膝关节最大伸直位时腘窝瘢痕挛缩范围设计皮瓣面积^[3]。

2.2 手术步骤 采用全身麻醉或硬膜外麻醉,患肢上止血带,取侧卧位,常规消毒。先将瘢痕创面彻底切除,将皮下四周瘢痕纤维组织彻底向四周松解,术中止血彻底,尽量保留皮下的小隐静脉及腓肠神经,勿伤及深层的主要神经及血管束,待创面处理完毕

通讯作者:郑鑫 E-mail:zx_19850801@163.com

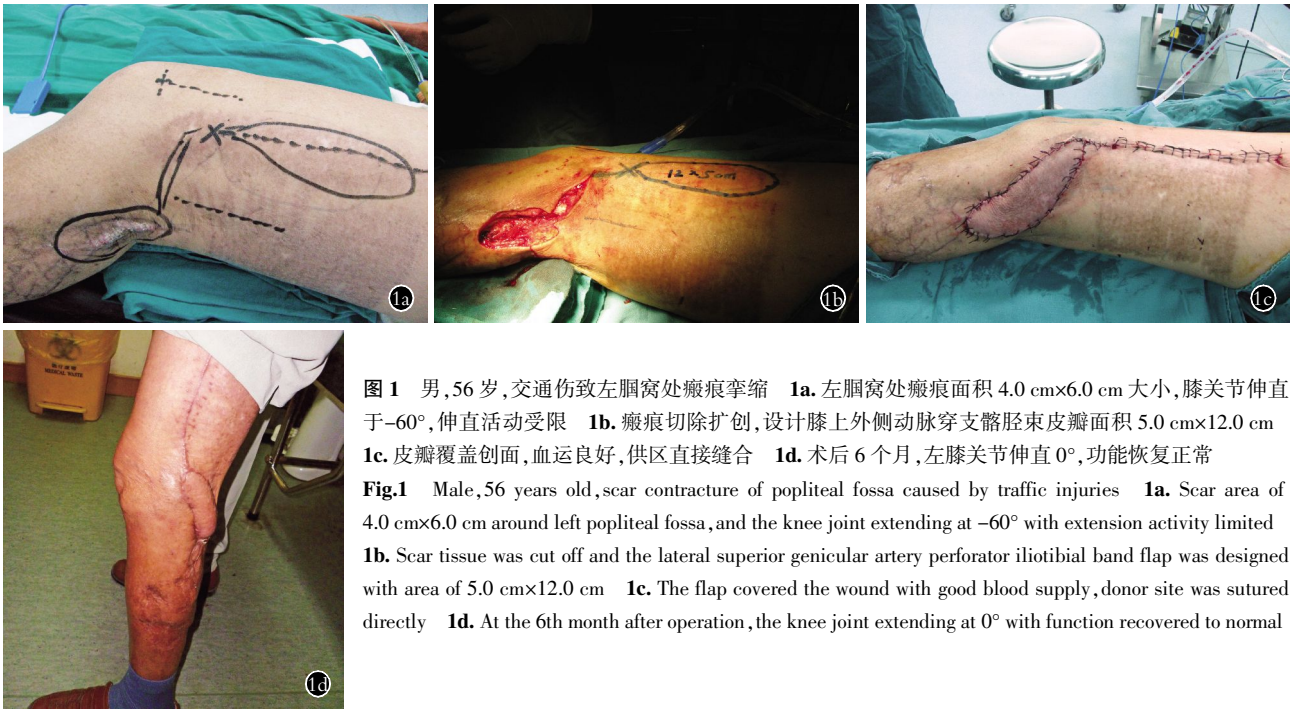


图 1 男, 56 岁, 交通伤致左腘窝处瘢痕挛缩 1a. 左腘窝处瘢痕面积 4.0 cm×6.0 cm 大小, 膝关节伸直于 -60°, 伸直活动受限 1b. 瘢痕切除扩创, 设计膝上外侧动脉穿支髂胫束皮瓣面积 5.0 cm×12.0 cm 1c. 皮瓣覆盖创面, 血运良好, 供区直接缝合 1d. 术后 6 个月, 左膝关节伸直 0°, 功能恢复正常

Fig. 1 Male, 56 years old, scar contracture of popliteal fossa caused by traffic injuries 1a. Scar area of 4.0 cm×6.0 cm around left popliteal fossa, and the knee joint extending at -60° with extension activity limited 1b. Scar tissue was cut off and the lateral superior genicular artery perforator iliotibial band flap was designed with area of 5.0 cm×12.0 cm 1c. The flap covered the wound with good blood supply, donor site was sutured directly 1d. At the 6th month after operation, the knee joint extending at 0° with function recovered to normal

后, 将受区近端与皮瓣旋转点处, 切开显露皮瓣转移隧道, 切开皮瓣近端前缘达阔筋膜下, 肌包膜上, 沿股外侧肌表面钝性向远端游离皮瓣, 术中将阔筋膜与皮下缝合数针以免分离。切开皮瓣的上下缘后, 向远端继续分离。参考高建明等^[1]的方法, 沿髂胫束表面血管向股外侧肌及股二头肌间隙分离, 可见膝上外侧血管和膝最上外侧血管的股外侧肌间隔穿支和股外侧肌的肌皮穿支, 取其中相对较粗大的穿支, 切取以膝上外侧血管穿支或膝最上外侧血管穿支为蒂的髂胫束皮瓣。穿支至少保留一支, 皮瓣的远端皮肤设计为三角皮瓣, 待旋转时可保留蒂部皮肤张力适当, 保护蒂部不受压迫。待皮瓣游离至旋转点处, 观察皮瓣近端的血运情况, 见皮下明显血液渗出, 血循环良好后, 将皮瓣顺时针方向旋转至受区。远端蒂部适当做皮下游离, 保证蒂部血管旋转处不受压迫, 以免影响远端供血障碍。于患膝伸直位, 将皮瓣远端与受区缝合, 并同时调节皮瓣张力, 供区直接缝合, 不能缝合时, 取皮植皮。待皮瓣与受区缝合完毕后, 皮瓣下放置负压引流, 以免渗出血肿导致皮瓣血循环障碍。患肢略屈膝位外固定 2 周, 待皮瓣愈合后, 拆除外固定, 适当进行功能康复。

3 结果

术后 11 例皮瓣均成活。3 例皮瓣远端血运较差, 最后色素沉着, 表皮坏死脱痂, 最大面积为 3.0 cm×2.5 cm, 可能与局部张力过大有关或蒂部受压, 导致远端供血不足, 予以间断拆线、换药后血运好转成活。术后随访 5 个月~2 年, 平均 14 个月。关节活动均恢复正常, 腘窝外形良好, 皮肤松紧度适

中。典型病例见图 1。

4 讨论

4.1 修复膝部瘢痕挛缩的皮瓣选择 随着显微技术的不断发展, 临床上常应用皮瓣移植的方法修复腘窝部的瘢痕挛缩。股前外侧皮瓣在修复肢体组织缺损应用广泛, 被誉为“万能皮瓣”, 是游离修复肢体创伤的首选, 临床上有学者采用逆行带蒂皮瓣移位修复膝部软组织缺损, 取得满意疗效^[4-7]。陈立军等^[8]利用带蒂筋膜瓣修复膝前软组织缺损。但是也存在着供区与受区距离较远, 血管蒂长度不够等问题^[9]。腘动脉在股骨下端发出众多穿支血管, 为局部皮瓣的设计提供了良好的条件。其中以膝上外侧动脉皮瓣的应用较为广泛。膝上外侧动脉上连接于旋股外侧动脉降支末端, 下交通于膝关节血管网, 其间有多条骨皮穿支。20 世纪 90 年代以来, 国内外学者已经开始对该皮瓣进行了解剖学及临床应用的报道, 认为膝上外侧动脉皮瓣血管蒂较长、皮肤较薄, 可以设计带有髂胫束、股骨、皮肤等复合组织瓣, 并且供区可以直接缝合或仅植少许的皮片就可以覆盖, 非常适用于膝部瘢痕挛缩的修复, 并且可以广泛应用于四肢软组织缺损的修复^[1, 3, 10-12]。李小毅等^[10]应用膝上外侧逆行皮瓣修复了 30 例腘窝创面, 取得了良好的效果, 并认为皮瓣转移幅度较大, 长度可达膝上 20.0 cm, 可以达到腘窝创面的内侧缘, 满足临床需要, 并且供区隐蔽, 大都可以直接缝合, 不影响关节活动。王俊义等^[13]应用膝上外侧筋膜皮瓣修复膝关节周围软组织缺损, 术后皮瓣全部成活, 膝关节活动恢复良好。笔者也采用该皮瓣对膝部瘢痕挛缩进行

修复,取得了满意的效果。

4.2 手术注意事项 患者体位采取侧卧位或俯卧位,以便于手术操作。皮瓣近端切取时将皮肤与阔筋膜缝合数针,防止皮瓣分离。蒂部切开分离时,将皮瓣掀起,可见有动脉穿支进入髂胫束内,尽量保留。蒂部远端基底部尽量宽一些,切开皮肤,可见浅筋膜内有丰富的血管网交汇入髂胫束,这样可增加皮瓣血运循环。蒂部旋转时可顺时针或逆时针,主要是皮瓣蒂部皮肤保留三角状或植皮,以免蒂部外露。不可强行缝合,以免压迫蒂部,影响血运。受区止血一定要彻底,以免皮瓣覆盖后形成血肿压迫,影响皮瓣远端血运。受区扩创时尽量达到深筋膜下肌层,因胫束不易与受区深筋膜愈合,导致局部脂肪液化或延迟愈合等。术后石膏固定患膝略屈曲,因伸直导致皮瓣远端张力较大,影响血运等。术后建议患者早期卧床,不能下床活动及负重,以免伤口出血,形成血肿影响皮瓣血运及愈合。

4.3 该术式的优缺点 笔者应用膝上外侧动脉穿支髂胫束皮瓣转移修复腓窝瘢痕挛缩,也取得了满意的效果,术后皮瓣全部成活,随访皮瓣外形良好,膝关节活动恢复正常,认为该皮瓣血管蒂位置恒定,变异较少,且血管蒂周围血管交通支丰富,利于手术操作。并且该皮瓣切取范围较大,蒂部较长,局部转移可以覆盖膝部外侧、后方甚至内侧的皮肤,也可以游离修复肢体组织缺损。因为供区皮肤较薄,术后受区外观较为良好。由于供区位于膝上外侧,切口相对隐蔽,且术后瘢痕对膝关节原有活动无影响。但该皮瓣内无知名感觉神经支配,故皮瓣感觉恢复不理想。

参考文献

- [1] 高建明,徐达传,储旭东,等.膝上外侧动脉穿支髂胫束皮瓣的解剖特点与临床应用[J].中华显微外科杂志,2010,33:450-453.
Gao JM, Xu DC, Chu XD, et al. The anatomical characteristics and clinical application of the lateral superior genicular artery perforator iliotibial band flap[J]. Zhonghua Xian Wei Wai Ke Za Zhi, 2010, 33:450-453. Chinese.
- [2] 高建明,徐达传,俞立新.吻合血管髂胫束移植修复跟腱缺损[J].中国修复重建外科杂志,2004,18:475-477.
Gao JM, Xu DC, Yu LX. Repair of achilles tendon defect by transplantation of iliotibial band with vascular anastomoses[J]. Zhongguo Xiu Fu Chong Jian Wai Ke Za Zhi, 2004, 18:475-477. Chinese.
- [3] 王树锋,周忠水,于胜军,等.膝上外侧动脉为蒂股骨远端骨皮瓣的应用解剖[J].中华显微外科杂志,2001,24:46-48.
Wang SF, Zhou ZS, Yu SJ, et al. Applied anatomy of distal femur osteocutaneous flap pedicle with the genu superior lateral artery[J]. Zhonghua Xian Wei Wai Ke Za Zhi, 2001, 24:46-48. Chinese.
- [4] 张启旭,乔群,陈光宇,等.股前外侧组织瓣临床应用 112 例分析[J].中国修复重建外科杂志,2006,20:540-543.
Zhang QX, Qiao Q, Chen GY, et al. Clinical application of the anterolateral thigh flap in 112 patients[J]. Zhongguo Xiu Fu Chong Jian Wai Ke Za Zhi, 2006, 20:540-543. Chinese.
- [5] 孙宝东,乔群,闫迎军.股前外侧皮瓣与筋膜组织瓣的临床应用[J].中国修复重建外科杂志,2006,20:550-552.
Sun BD, Qiao Q, Yan YJ. Clinical applications of anterolateral thigh flap[J]. Zhongguo Xiu Fu Chong Jian Wai Ke Za Zhi, 2006, 20:550-552. Chinese.
- [6] 王生钰.股前外侧皮瓣急诊修复手部皮肤软组织缺损[J].中国修复重建外科杂志,2005,19:498.
Wang SY. Repair of hand skin soft tissue defect by anterolateral thigh flap in emergency[J]. Zhongguo Xiu Fu Chong Jian Wai Ke Za Zhi, 2005, 19:498. Chinese.
- [7] 张志新,庄玉君,陈雷,等.带蒂股前外侧皮瓣修复手部大面积皮肤缺损[J].中国修复重建外科杂志,2006,20:1199-1200.
Zhang ZX, Zhuang YJ, Chen L, et al. Application of pedicled anterolateral thigh flap transferring for coverage of oversized skin defect of hand[J]. Zhongguo Xiu Fu Chong Jian Wai Ke Za Zhi, 2006, 20:1199-1200. Chinese.
- [8] 陈立军,薛防震,朱劲松.带蒂筋膜瓣治疗腓前软组织缺损[J].中国骨伤,2008,21(1):45-46.
Chen LJ, Xue FZ, Zhu JS. Treatment of soft tissue defects of anterior patellar region by the vascularized fascia flap[J]. Zhongguo Gu Shang/China J Orthop Trauma, 2008, 21(1):45-46. Chinese.
- [9] 王赤宇,康庆林,宋文奇,等.血管蒂延长技术在股前外侧逆行岛状皮瓣中的应用[J].中国修复重建外科杂志,2007,21:1284-1286.
Wang CY, Kang QL, Song WQ, et al. Vascular pedicle elongation technique in anterolateral thigh island flap transportation[J]. Zhongguo Xiu Fu Chong Jian Wai Ke Za Zhi, 2007, 20:1284-1286. Chinese.
- [10] 李小毅,黄书润,苏金荣,等.膝上逆行皮瓣修复腓窝瘢痕挛缩[J].中华整形外科杂志,2002,18:343-345.
Li XY, Huang SR, Su JR, et al. Investigation of a retrograded supra-genicular flap for treatment of scarring contraction of popliteal fossa[J]. Zhonghua Zheng Xing Wai Ke Za Zhi, 2002, 18:343-345. Chinese.
- [11] Spokevicius S, Jankauskas A. Anatomy and clinical applications of a composite cutaneo-subcutaneous flap based on the lateral superior genicular vessels[J]. J Reconstr Microsurg, 1995, 11(1):15-20.
- [12] 郑松,刘明,徐竹,等.膝前外侧皮瓣的临床应用[J].中国骨伤,2007,20:782-783.
Zheng S, Liu M, Xu Z, et al. Clinical application of pedicled anterolateral knee flap[J]. Zhongguo Gu Shang/China J Orthop Trauma, 2007, 20:782-783. Chinese.
- [13] 王俊义,李大伟,金天明,等.膝上外侧筋膜皮瓣修复结合退热消肿汤治疗膝关节周围皮肤软组织缺损[J].中国骨伤,2010,23:175-176.
Wang JY, Li DW, Jin TM, et al. Lateral superior genicular flap combined with *Tuihuang Xiaozhong* decoction for the treatment of soft tissue defects around the knee joint[J]. Zhongguo Gu Shang/China J Orthop Trauma, 2010, 23:175-176. Chinese.

(收稿日期:2012-07-24 本文编辑:王玉蔓)