

· 临床研究 ·

斜外侧椎间融合在 Modic 改变伴终板硬化 腰椎间盘退变治疗中的应用

陈平泉¹, 曾忠友², 赵兴³, 范时洋², 吴宏飞², 俞伟², 张建乔¹, 宋永兴², 范顺武³, 方向前³, 裴斐², 宋国浩²

(1. 嘉兴市中医医院骨伤科, 浙江 嘉兴 314001; 2. 武警部队骨科医学中心 武警海警总队医院骨二科, 浙江 嘉兴 314000; 3. 浙江大学医学院附属邵逸夫医院骨科, 浙江 杭州 310016)

【摘要】 目的: 探讨 Stand-alone 斜外侧椎间融合 (oblique lateral interbody fusion, OLIF) 应用于 Modic 改变伴终板硬化的腰椎间盘退变治疗的可行性和临床效果。方法: 回顾性分析 2015 年 1 月至 2018 年 12 月 3 家医疗中心收治的 16 例 Modic 改变伴终板硬化的腰椎间盘退变患者。其中男 6 例, 女 10 例; 年龄 45~67 (55.48±8.07) 岁; 病史 36~240 (82.40±47.68) 个月。病变部位: L_{2,3} 2 例, L_{3,4} 5 例, L_{4,5} 9 例; 均表现为慢性腰痛, 伴下肢神经症状 3 例。采用单纯斜外侧腰椎椎间融合术治疗, 术后对临床和影像学结果, 以及并发症情况进行观察。结果: 术中无血管、终板损伤和椎体骨折。切口长度 (4.06±0.42) cm, 手术时间 (45.12±5.43) min, 术中出血量 (33.40±7.29) ml; 术后 72 h 切口疼痛视觉模拟评分 (visual analogue scale, VAS) 为 1.14±0.47。所有患者无切口皮肤坏死、愈合不良或感染; 出现交感链损伤 1 例、左大腿前外侧疼痛并麻木 2 例、左侧髂腰肌无力 1 例, 均为一过性损伤, 并发症发生率为 25% (4/16)。16 例患者均获得随访, 时间 12~36 (20.80±5.46) 个月。术后椎间隙高度获得明显的恢复, 随访过程中有轻度丢失。末次随访时腰椎冠状面和矢状面平衡均获得良好的改善。融合器无明显沉降或移位, 均获得椎间融合。末次随访时日本骨科协会 (Japanese Orthopaedic Association, JOA) 评分和 Oswestry 功能障碍指数 (Oswestry disability index, ODI) 明显改善。结论: 只要严格病例选择, 充分的术前检查, 采用 Stand-alone OLIF 治疗 Modic 改变伴终板硬化的腰椎间盘退变效果良好, 临床优势明显, 是较好的手术选择。

【关键词】 腰椎间盘退变; Modic 改变; 终板硬化; 脊柱融合术; 并发症

中图分类号: R681.5

DOI: 10.12200/j.issn.1003-0034.2023.01.006

开放科学 (资源服务) 标识码 (OSID):



Application of oblique lateral interbody fusion in the treatment of lumbar intervertebral disc degeneration in patients with Modic change and endplate sclerosis

CHEN Ping-quan¹, ZENG Zhong-you², ZHAO Xing³, FAN Shi-yang², WU Hong-fei², YU Wei², ZHANG Jian-qiao¹, SONG Yong-xing², FAN Shun-wu³, FANG Xiang-qian³, PEI Fei², SONG Guo-hao² (1. Department of Orthopaedics, Jiaxing TCM Hospital, Jiaxing 314001, Zhejiang, China; 2. The Second Department of Orthopaedics, Armed Police Marine Police Corps Hospital, Orthopaedic Medical Center of Armed Police Force, Jiaxing 314000, Zhejiang, China; 3. Department of Orthopaedics, Run Run Show Hospital Affiliated to Zhejiang University Medical School, Hangzhou 310016, Zhejiang, China)

ABSTRACT Objective To explore the feasibility and clinical effect of Stand-alone oblique lateral interbody fusion (OLIF) in the treatment of lumbar intervertebral disc degeneration with Modic changes and endplate sclerosis. **Methods** A retrospective analysis was performed on 16 cases with lumbar intervertebral disc degeneration with Modic changes and endplate sclerosis admitted to three medical centers from January 2015 to December 2018. There were 6 males and 10 females, the age ranged from 45 to 67 years old with an average of (55.48±8.07) years old, the medical history ranged from 36 to 240 months with an average of (82.40±47.68) months. The lesion sites included L_{2,3} in 2 cases, L_{3,4} in 5 cases, and L_{4,5} in 9 cases. All patients presented with chronic low back pain with lower limb neurological symptoms in 3 cases. All patients were treated by Stand-alone oblique lateral lumbar interbody fusion. Clinical and radiological findings and complications were observed. **Results** There was no vascular injury, endplate injury and vertebral fracture during the operation. The mean incision length, operation time, and intraoperative blood loss were (4.06±0.42) cm, (45.12±5.43) min, (33.40±7.29) ml, respectively. The mean visual analogue

基金项目: 浙江省医药卫生科技计划项目 (编号: 2020KY968)

Fund program: Medicine Health Science Technology Project of Zhejiang Province (No.2020KY968)

通讯作者: 曾忠友 E-mail: zjzengzy@126.com

Corresponding author: ZENG Zhong-you E-mail: zjzengzy@126.com

scale (VAS) of the incision pain was (1.14±0.47) at 72 hours after operation. There was no incision skin necrosis, poor incision healing or infection in patients. Sympathetic chain injury occurred in 1 case, anterolateral pain and numbness of the left thigh in 2 cases, and weakness of the left iliopsoas muscle in 1 case, all of which were transient injuries with a complication rate of 25%(4/16). All 16 patients were followed up from 12 to 36 months with an average of (20.80±5.46) months. The intervertebral space height was significantly recovered after operation, with slight lost during the follow-up. Coronal and sagittal balance of the lumbar spine showed good improvement at the final follow-up. There was no obvious subsidence or displacement of the cage, and the interbody fusion was obtained. At the final follow-up, Japanese Orthopaedic Association (JOA) score and Oswestry disability index(ODI) were significantly improved. **Conclusion** As long as the selection of case is strict enough and the preoperative examination is sufficient, the use of Stand-alone OLIF in the treatment of lumbar intervertebral disc degeneration with Modic changes and endplate sclerosis has a good results, with obvious clinical advantages and is a better surgical choice.

KEYWORDS Lumbar disc degeneration; Modic changes; Endplate sclerosis; Spinal fusion; Complications

Modic 改变与腰椎间盘突出、腰痛密切相关,形成机制主要有力学改变、局部生物化学变化、低毒性细菌感染等^[1-8]。Modic 于 1988 年首次被系统地进行描述,并根据 MRI 上信号的不同分为 I、II、III 型^[9]。在 Modic 改变中,部分病例伴有终板硬化^[10],主要为部分 II 型和全部的 III 型。终板硬化患者影像学表现为椎间隙的狭窄、终板骨质的不同程度和不同范围硬化、局部骨质增生^[1,3,5,7-8,11]。对于伴 Modic 改变的腰椎间盘突出,多数作者^[2,4-5,12-13]主张手术治疗,且多采用椎间融合的方式^[2,5,12-13]。椎间融合方式很多,传统的后路椎弓根螺钉固定并椎间融合器植骨治疗技术成熟、疗效确切,但也存在骶棘肌剥离和牵拉导致的肌肉损害^[14-15],以及椎管减压和经椎管的椎间隙操作对脊膜或神经带来的干扰、甚至损伤等^[16-18]。由于 Modic 改变伴终板硬化的腰椎间盘突出病例椎管大部分无实质性神经压迫,临床上较少出现因神经受压而伴发的下肢症状,无须直接进行椎管减压。因而,如何选择创伤小而效果确切的融合方式一直是临床困扰的问题。近年来,随着腰椎斜外侧椎间融合技术(oblique lateral interbody fusion, OLIF)的出现^[19],特别是联合后路椎弓根螺钉固定方式,由于创伤小、出血少、间接减压效果好、稳定性好、恢复快、融合率高等优点获得快速而大量的应用^[20-23]。但斜外侧椎间融合和后路椎弓根螺钉固定作为解剖入路完全不同的两种手术方式的联合,术中患者需要改变体位,再次进行消毒铺巾。虽然有同一个体位下完成手术的报道^[24],但由于外科医生个人的习惯,更多作者^[20-23]仍然采用 2 个体位下的操作。如此,势必延长麻醉和手术时间,增加切口和创伤。为了减少操作步骤、缩短麻醉和手术时间、减小创伤,在 OLIF 的临床应用中,有作者^[25-26]采用了 Stand-alone OLIF 的方式,但生物力学试验^[27-28]表明:与联合椎弓根螺钉固定相比,Stand-alone OLIF 轴向载荷能力和抵抗各向活动能力较弱。而且临床结果亦显示:采用 Stand-alone OLIF 方式术后融合器沉降甚至移位的风险较

大^[25-26,29-30]。那么,针对 Modic 改变伴终板硬化腰椎间盘突出病变的特殊椎间病理改变及病情,应用 Stand-alone OLIF 是否可行?临床效果如何?笔者回顾性分析武警海警总队医院、浙江大学附属邵逸夫医院和嘉兴市中医医院 3 个医疗中心 2015 年 1 月至 2018 年 12 月采用 Stand-alone OLIF 方式治疗的 16 例 Modic 改变伴终板硬化病例,报告如下。

1 资料与方法

1.1 病例选择

1.1.1 纳入标准 (1)存在慢性腰痛的腰椎间盘突出,伴或不伴下肢神经症状,影像学表现有 Modic 改变^[9]并终板硬化。(2)临床表现、化验检查和影像检查提示椎间隙无炎症表现或椎间隙炎症处于转归期,包括无畏寒发热、红细胞沉降率和 C 反应蛋白检查正常;影像学上病变节段邻近骨质无明显吸收或破坏,软组织无肿胀或脓肿。(3)经严格保守治疗 6 个月无效。(4)需要融合的部位为 L₁-L₅ 节段。(5)随访 1 年或以上,且资料完整。

1.1.2 排除标准 (1)伴严重的腰椎管狭窄(按 SCHIZAS 等^[31]分级 D 级),或椎管内马尾神经、神经根存在骨性卡压,或游离型椎间盘突出,需要直接椎管减压者。(2)腰椎关节突自发性融合。(3)既往有腹膜外手术史,或腹部血管鞘与腰大肌间隙消失。

1.2 一般资料

根据病例选择标准,共纳入患者 16 例,其中男 6 例,女 10 例;年龄 45~67(55.48±8.07)岁;病史 36~240(82.40±47.68)个月;Modic 改变 II 型 4 例,III 型 12 例。病变部位:L_{2,3} 2 例,L_{3,4} 5 例,L_{4,5} 9 例。均表现为慢性腰痛,伴下肢神经症状 3 例,主要为行走时下肢放射痛伴麻木,卧床时腰痛和下肢放射痛缓解。入院后常规摄腰椎正侧位、过屈过伸位 X 线片,行腰椎间盘 CT 平扫和腰椎平扫并二维重建,腰椎 MRI 检查。所有患者影像检查显示病变椎间隙高度明显下降、终板部分或完全硬化、椎体缘骨质增生,部分终板有虫蚀样改变。术前血常规、红细胞沉降率和 C

反应蛋白检查均正常。

1.3 治疗方法

1.3.1 手术方法 均采用全麻,患者右侧卧位,保持屈髋,腋下及髋部用宽布胶分别固定。手术步骤:C形臂 X 线定位并规划切口。沿病变椎间隙体表投影,椎体前缘向前延伸 2 cm,向后 1 cm,切口长 3~4 cm。分别沿腹外斜肌、腹内斜肌肌纤维走行方向做钝性分离,切开腹横肌,向腹侧推开腹膜外脂肪和腹内脏器,显露腰大肌。用骨膜剥离器将腰大肌稍向背侧推开,牵开器将腰大肌牵向背侧、将腹内脏器连同腹膜外脂肪牵向腹侧,显露病变节段椎间隙,于椎间隙前中 1/3 斜向插入导针。C 形臂 X 线透视确定病变节段无误后逐级放置扩张套管和带光源的通道。移除套管,张开通道并予以固定(保持通道斜向方向),切开纤维环,顺椎间隙垂直插入钝性绞刀,C 形臂 X 线透视确定椎间隙位置和方向。用融合器试模作椎间隙的逐级撑开,进一步清除残余髓核组织,制作融合器床。C 形臂 X 线透视确认所用融合器的高度和长度。将填入骨块的融合器(融合器填入骨块后用可吸收缝线予以连续性捆绑,以防止融合器在植入椎间隙过程中骨块脱落)垂直植入椎间隙,C 形臂 X 线透视确定融合器位置良好后,冲洗切口,探查切口内无活动性出血,撤除通道,再次探查并确认切口内无活动性出血后予逐层缝合切口,均未放置引流管。

1.3.2 术后处理 术后常规予预防感染、补液等处理,并卧床休息。麻醉苏醒后,嘱患者主动进行双侧踝关节背伸运动、被动进行双下肢直腿抬高运动。术后 2~3 d 佩戴胸腰支具下床活动,6 周后进行渐进性腰背肌、腹肌锻炼。

1.4 观察项目与方法

1.4.1 一般情况 记录术中各项指标,如切口长度、手术时间、术中出血量。

1.4.2 影像学观察 于术后 3~5 d、3、6、12 个月,随后每隔 12 个月行腰椎正侧位 X 线检查,术后 12 个月行腰椎过屈过伸位 X 线检查,术后 3~5 d、12 个月行 CT 平扫并矢状面、冠状面重建。根据影像学检查测量并对比手术前后及末次随访病变节段椎间隙高度(病变节段椎间隙前后缘高度的平均值),术前和末次随访时腰椎冠状面和矢状面 Cobb 角(L_1 椎体上终板平行线垂线与 S_1 椎体上终板平行线垂线的夹角),融合器沉降或移位、椎间融合情况,以及邻近节段退变现象。

1.4.3 临床效果 所有病例于术后 72 h 采用视觉模拟评分(visual analogue scale, VAS)^[32]对切口疼痛进行评分。术前和末次随访采用日本骨科学会(Japanese Orthopaedic Association, JOA)^[33]下腰痛评

分系统(29 分法),对患者症状、体征、日常活动及膀胱功能进行评价,同时采用 Oswestry 功能障碍指数(Oswestry disability index, ODI)^[34]对患者疼痛程度、生活自理能力、提物、坐、站立、行走、睡眠、性生活、社会活动、旅游等 10 个方面进行评分。

1.4.4 并发症情况 观察术中是否有血管和终板损伤,术中术后神经损伤,术后切口皮肤愈合、切口感染、下肢肿胀等情况。

1.5 统计学处理

所有数据采用 SPSS 20.0 软件进行统计处理,对手术前后和末次随访时病变节段椎间隙高度的比较采用单因素方差分析,对术前、末次随访时腰椎冠状面和矢状面 Cobb 角、JOA 评分和 ODI 的比较采用配对设计定量资料 t 检验。以 $P < 0.05$ 为差异有统计学意义。

2 结果

所有病例顺利完成手术操作,通道和融合器由美国枢法模公司提供,融合器为 Peek 材料 Clydesdale 系统。融合器内植骨:同种异体骨 6 例,人工骨加骨形态发生蛋白(bone morphogenetic protein, BMP)10 例。同种异体骨由北京鑫康辰医学科技发展有限公司提供,人工骨为美国 Wright 公司生产提供,BMP 为杭州九源基因工程有限公司生产提供。本组病例均获得随访,时间 12~36 (20.80±5.46)个月,典型病例影像学资料见图 1、图 2。

2.1 一般情况

本组患者切口长度 3.4~4.7 (4.06±0.42) cm,手术时间 38~55 (45.12±5.43) min,术中出血量 20~45 (33.40±7.29) ml。

2.2 影像学结果

椎间隙高度由术前的(4.87±1.25) mm,恢复至术后的(11.91±0.88) mm,手术前后差异有统计学意义($t=8.39, P < 0.001$),随访过程中椎间隙高度部分丢失,末次随访时为(11.18±0.71) mm,与术后比较差异有统计学意义($t=2.26, P=0.041$)。腰椎冠状面 Cobb 角由术前的(7.31±3.14)°减小至末次随访时的(3.26±1.47)°($t=7.75, P=0.013$);矢状面 Cobb 角由术前的(32.59±4.76)°恢复至末次随访时的(45.86±7.32)°($t=5.02, P=0.034$)。融合器无明显沉降和移位,椎间融合良好。

2.3 临床效果

术后 72 h 切口疼痛 VAS 为 0~2 (1.14±0.47) 分。JOA 评分由术前的 15.20±2.49 恢复至末次随访时的 27.40±1.18 ($t=6.23, P=0.011$);ODI 由术前的(41.80±2.76)%下降至末次随访时的(7.10±1.36)%($t=9.74, P < 0.000 1$)。

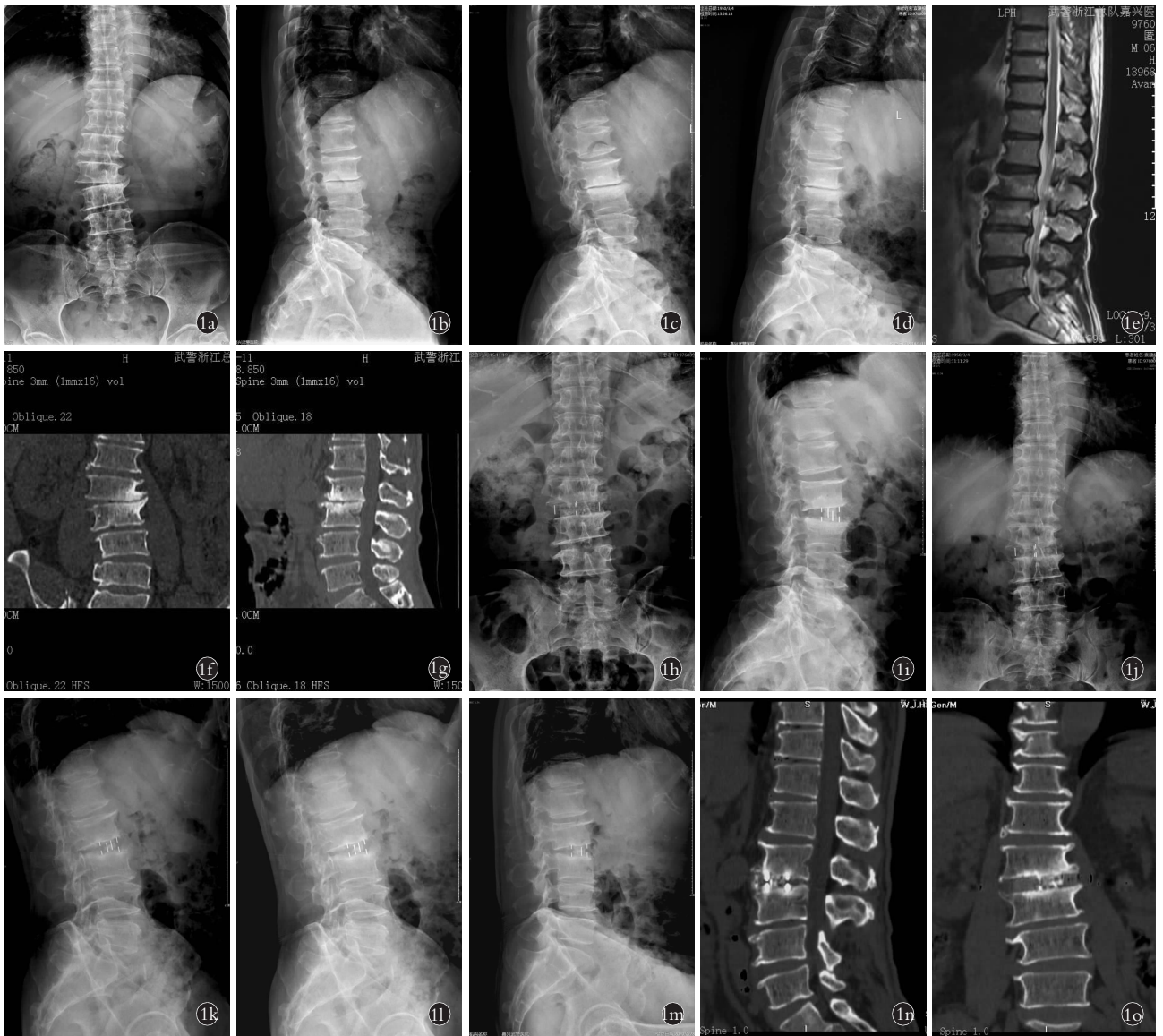


图 1 患者,男,67岁,反复腰痛11年余,诊断为L_{2,3}椎间盘退行性病变(Modic改变Ⅲ型) **1a,1b.** 术前腰椎正侧位X线片示腰椎侧弯,椎体缘骨质增生,L_{2,3}椎间隙明显狭窄,终板硬化 **1c,1d.** 术前腰椎过屈过伸侧位X线片示L₂下终板和L₃上终板角度无明显变化,L_{2,3}椎体无相对位移 **1e.** 术前腰椎MRI矢状面扫描示L_{2,3}椎间隙明显狭窄,L_{2,3}节段椎管狭窄 **1f,1g.** 术前腰椎CT冠状面、矢状面重建示腰椎侧弯,L_{2,3}椎间隙明显狭窄,终板硬化 **1h,1i.** 经行Stand-alone斜外侧L_{2,3}椎间融合术,术后腰椎正侧位X线片示腰椎侧弯明显矫正,L_{2,3}椎间融合器在位良好,L_{2,3}椎间隙高度获得良好恢复 **1j,1k.** 术后2年腰椎正侧位X线片示腰椎生理弧度良好,L_{2,3}椎间融合器在位良好,椎间隙高度轻度丢失 **1l,1m.** 术后2年腰椎过屈过伸侧位X线片示L₂下终板和L₃上终板角度无明显变化,L_{2,3}椎体无相对位移 **1n,1o.** 术后2年腰椎CT冠状面、矢状面重建示L_{2,3}椎间融合良好

Fig.1 A 67-year-old male patient with recurrent low back pain for more than 11 years, diagnosed as L_{2,3} intervertebral disc degeneration (Modic change type III) **1a,1b.** Anterior and lateral X-rays of lumbar spine before operation showed lumbar scoliosis, bone hyperplasia at the vertebral body edge, significant stenosis of the L_{2,3} intervertebral space, and endplate sclerosis **1c,1d.** Preoperative lateral X-rays of lumbar hyperflexion and hyperextension showed no significant changes in the angles of the L₂ lower endplate and L₃ upper endplate, and no relative displacement of L₂ and L₃ vertebral bodies **1e.** Preoperative sagittal MRI of lumbar spine showed the L_{2,3} intervertebral space was significantly narrowed, with spinal canal stenosis of L_{2,3} **1f,1g.** Preoperative lumbar CT by coronal and sagittal reconstruction showed lumbar scoliosis, significant stenosis of L_{2,3} intervertebral space, and endplate sclerosis **1h,1i.** After Stand-alone oblique lateral L_{2,3} interbody fusion, postoperative anterior and lateral X-rays showed the lumbar scoliosis was significantly corrected, the L_{2,3} interbody cage was well on place, and the height of L_{2,3} intervertebral space recovered well **1j,1k.** AP and lateral X-rays at 2 years after operation showed that lumbar spine had a good physiological curvature, L_{2,3} interbody cage was well on place, and height of intervertebral space was slightly lost **1l,1m.** Two years after operation, lateral X-rays of lumbar hyperflexion and hyperextension showed no significant changes in the angles of L₂ lower endplate and L₃ upper endplate, and no relative displacement of L₂ and L₃ vertebral bodies **1n,1o.** Two years after operation, lumbar CT by coronal and sagittal reconstruction showed that L_{2,3} interbody fusion was good

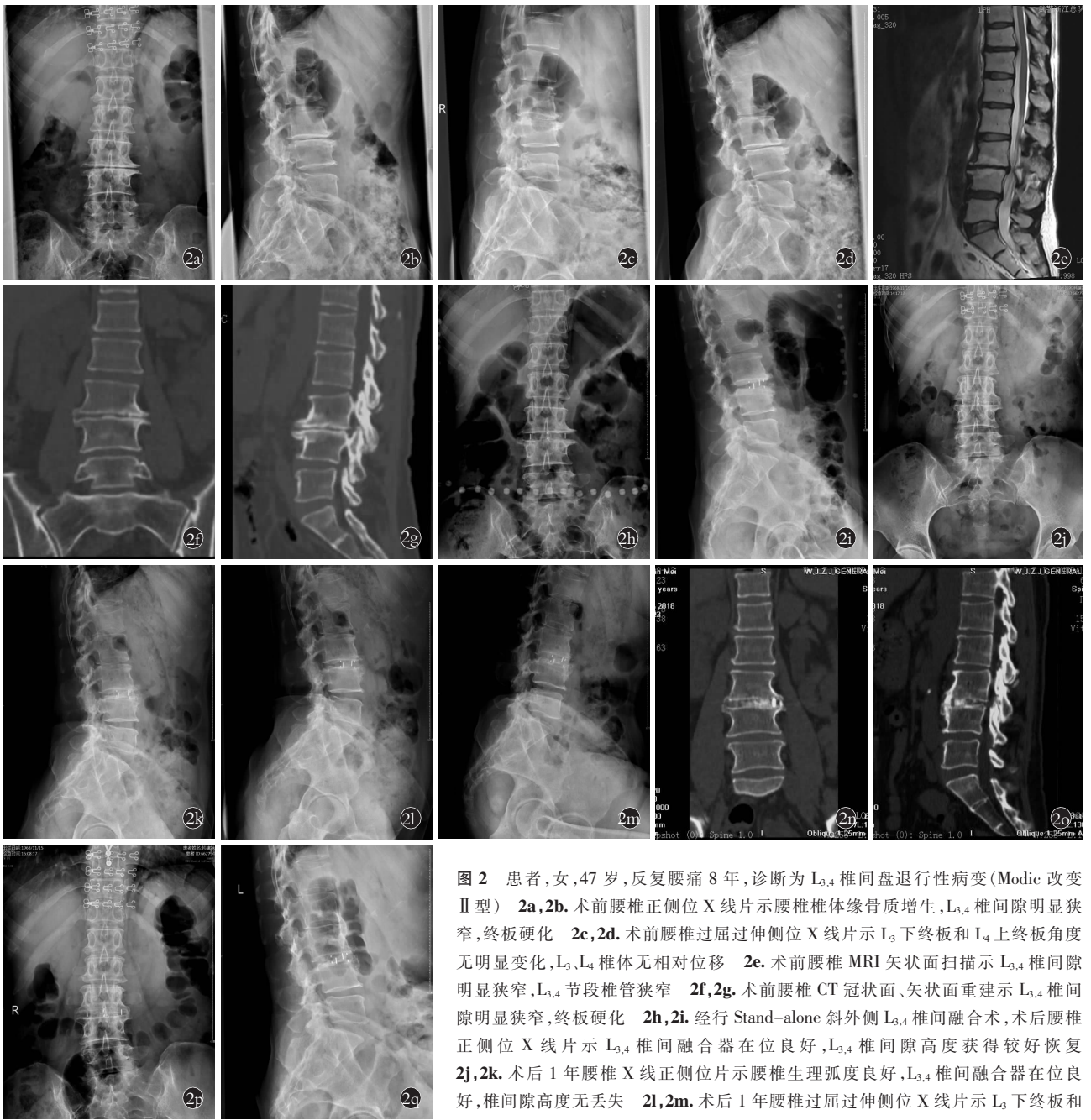

图 2 患者,女,47岁,反复腰痛8年,诊断为L_{3,4}椎间盘退行性病变(Modic改变II型) 2a,2b.术前腰椎正侧位X线片示腰椎椎体缘骨质增生,L_{3,4}椎间隙明显狭窄,终板硬化 2c,2d.术前腰椎过屈过伸侧位X线片示L₃下终板和L₄上终板角度无明显变化,L_{3,4}椎体无相对位移 2e.术前腰椎MRI矢状面扫描提示L_{3,4}椎间隙明显狭窄,L_{3,4}节段椎管狭窄 2f,2g.术前腰椎CT冠状面、矢状面重建示L_{3,4}椎间隙明显狭窄,终板硬化 2h,2i.经行Stand-alone斜外侧L_{3,4}椎间融合术,术后腰椎正侧位X线片示L_{3,4}椎间融合器在位良好,L_{3,4}椎间隙高度获得较好恢复 2j,2k.术后1年腰椎X线正侧位片示腰椎生理弧度良好,L_{3,4}椎间融合器在位良好,椎间隙高度无丢失 2l,2m.术后1年腰椎过屈过伸侧位X线片示L₃下终板和L₄上终板角度无明显变化,L_{3,4}椎体无相对位移 2n,2o.术后1年腰椎CT平扫并冠状面、矢状面重建示L_{3,4}椎间融合良好 2p,2q.术后3年腰椎正侧位X线片示L_{3,4}椎间融合器在位良好,椎间隙高度无明显丢失

Fig.2 A 47-year-old female patient with recurrent low back pain for 8 years, diagnosed as L_{3,4} intervertebral disc degeneration (Modic change type II) 2a,2b. Anterior and lateral X-rays of lumbar spine before operation showed bone hyperplasia at the vertebral body edge, significant stenosis of the L_{3,4} intervertebral space, and endplate sclerosis 2c,2d. Preoperative lateral X-rays of lumbar hyperflexion and hyperextension showed no significant changes in the angles of the L₃ lower endplate and L₄ upper endplate, and no relative displacement of L₃ and L₄ vertebral bodies 2e. Preoperative sagittal MRI of lumbar spine showed the L_{3,4} intervertebral space was significantly narrowed, with spinal canal stenosis of L_{3,4} 2f,2g. Preoperative lumbar CT by coronal and sagittal reconstruction showed significant stenosis of L_{3,4} intervertebral space, and endplate sclerosis 2h,2i. After Stand-alone oblique lateral L_{3,4} interbody fusion, postoperative anterior and lateral X-rays showed the L_{3,4} interbody cage was well on place, and the height of L_{3,4} intervertebral space recovered well 2j,2k. AP and lateral X-rays at 1 year after operation showed that lumbar spine had a good physiological curvature, L_{3,4} interbody cage was well on place, and height of intervertebral space was no lost 2l,2m. One year after operation, lateral X-rays of lumbar hyperflexion and hyperextension showed no significant changes in angles of L₃ lower endplate and L₄ upper endplate, and no relative displacement of L₃ and L₄ vertebral bodies 2n,2o. One year after operation, lumbar CT by coronal and sagittal reconstruction showed that L_{3,4} interbody fusion was good 2p,2q. Three years after operation, anterior and lateral X-rays of lumbar spine showed that L_{3,4} interbody cage was on good position, and height of the intervertebral space was no obvious lost

2.4 并发症情况

本组术中无血管、终板损伤和椎体骨折,出现左侧交感链损伤 1 例,1 周后恢复;左大腿前外侧疼痛、麻木 2 例,5~7 d 后缓解;髂腰肌无力 1 例,术后 3~5 d 恢复。本组并发症发生率为 25%(4/16),均为一过性损伤,无严重或持续性损害。

3 讨论

3.1 Modic 改变伴终板硬化腰椎间盘突出症的融合治疗

本组病史时间长,病情迁延;主要表现为慢性、顽固性腰痛,较少神经症状;病变节段椎间隙高度明显下降,极度狭窄;病变节段终板硬化明显、椎间关节僵硬,特别是 III 型患者;部分病例硬化的终板有虫蚀样改变,考虑其 Modic 改变的机制可能来源于椎间隙低毒性感染。对于 Modic 改变伴终板硬化病例,虽然多数作者^[1-8]认为其终板及终板下骨质改变趋于稳定,但患者多存在慢性腰痛,部分病例因椎间隙高度下降和椎间孔容积减少可能出现神经根刺激,导致下肢症状。因此,对于 Modic 改变伴终板硬化腰椎间盘突出症的手术治疗目标主要是恢复椎间隙高度,增强病变节段的稳定性。

临床上常用的后路正中切口显露椎弓根螺钉固定并椎间融合方法,虽然操作技术标准、椎间隙清理彻底、固定牢固、融合率高、效果确切^[35-37],但存在切口大、软组织损伤重、出血多、椎管内干扰和神经损伤等不足。既使采用肌间隙入路通道显露下的操作^[36,38]减小了切口及软组织损害和出血,但由于减压和融合方式没有改变,仍然存在椎管内出血、椎管干扰和神经损害的问题^[38-39]。近年来出现的 OLIF 技术^[19-26],由于采用腰椎斜外侧切口,经腹壁肌纤维,通过腰大肌和髂血管鞘的天然间隙,不进入椎管。不仅显露快速,而且不进行直接的椎管减压,减少了出血,避免了椎管内组织干扰和椎管内神经损伤的风险,加之所用的融合器体积和面积较大,有利于提高椎间的稳定性,促进融合。因此,OLIF 技术临床优势明显^[19-26]。

目前,OLIF 技术的临床应用^[19-27]主要有两种方式:Stand-alone OLIF 和 OLIF 联合后路椎弓螺钉固定。Stand-alone OLIF 相对于联合椎弓螺钉固定方式,切口和创伤小、出血少、手术时间短、费用省。但 Stand-alone OLIF 技术由于局部解剖^[40-41]、手术设计、个体终板强度差异^[42-43]、融合部位稳定性^[27-28]等因素影响,术后融合器沉降,甚至融合器移位、椎间不融合的风险较大^[29-30]。当然,由于 Modic 改变伴终板硬化特有的病理改变,其采用 Stand-alone OLIF 的方式是否可行?能否降低上述风险?还需要更深度

的探讨。

3.2 斜外侧椎间融合治疗 Modic 改变伴终板硬化腰椎间盘突出症的临床特点和效果

本组病例采用标准的斜外侧入路,经腰大肌与髂血管间隙进入,行椎间清理、松解、撑开、融合器植入,未附加侧方或后方内固定。术后未出现切口皮肤坏死、愈合不良或感染。由于斜外侧入路操作窗口大、显露良好、进入椎间隙直接快速,且椎间隙操作基本在直视下完成,椎间清理彻底、松解充分,OLIF 技术不仅可以很好地恢复椎间隙高度,而且能较好地改善腰椎冠状面和矢状面平衡。末次随访时 JOA 评分和 ODI 均获得明显的改善。虽然并发症发生率较高,但均为一过性损伤,无重要神经或大血管损伤等严重并发症的发生,亦无持续性损害。因此,Stand-alone OLIF 用于 Modic 改变伴终板硬化腰椎间盘突出症的治疗充分显示了 OLIF 技术的优势,当然,本组病例术后腰椎功能良好的恢复除了 OLIF 技术优势,还可能与本组病例均为单节段融合、且多为青壮年患者、能较好地进行术后的康复锻炼等有关。

3.3 关于终板硬化患者术中终板损伤、术后融合器沉降和椎间融合问题

术中终板损伤和术后融合器沉降是 OLIF 技术最为常见的并发症^[23,29-30,44-47],而在 Stand-alone OLIF 的应用中,不仅有融合器的移位,且融合器沉降更明显^[29-30],但在本组病例中,无论是术中操作,或是术后的影像检查均未发现终板损伤。虽然随访过程中椎间隙高度出现轻度丢失,但并未出现融合器的明显沉降以及融合器的移位。本组术中未出现终板损伤和术后融合器的明显沉降或移位,分析原因可能有:Modic 改变伴终板硬化病例往往病史较长,椎间盘退变明显,炎症反应、免疫反应及终板长时间承受异常应力刺激,病变椎间隙上下终板出现增厚和硬化。增厚和硬化的终板在进行椎间隙清理时出血少、不易损伤,而且承载能力强,术后不易被融合器切割,加之椎间较僵硬,融合器置入后稳定性较好。LIU 等^[48]研究发现:伴有 MRI 上椎体终板 Modic 改变或 CT 上椎体终板硬化的患者,应用 Stand-alone OLIF 发生融合器下沉的概率明显低于没有这两个影像学征象的患者。另外,关于 Modic 改变伴终板硬化的融合问题,由于本病特殊的椎间病理生理改变,可能抑制融合过程,这方面已有来自后路椎间融合结果^[49-50]的佐证。本组病例均融合,高于文献报道^[19-26,29-30,51]的关于 Stand-alone OLIF 或联合椎弓根螺钉固定方式的融合率,而且融合速度快、质量好。考虑可能有以下因素:(1)由于 Modic 改变伴终板硬化所具有的病史和病理特点,病变节段局部稳定性较好。(2)增厚、

硬化的终板不易损伤,本组融合节段的终板均完好,在椎间充分松解的基础上可以尽量选用稍大号融合器,较好地恢复了纤维环张力,进一步增强了椎间的稳定。(3)OLIF 技术所用融合器无论是体积和面积均较大,增加了终板接触面积。(4)虽然未附加内固定,应力完全通过终板和融合器传导,但由于终板与融合器接触面积大,终板承受应力均匀分散。(5)在良好稳定的前提下,OLIF 所用融合器植骨量多、植骨部分与终板接触面大、部分病例使用了 BMP 也可能是促进融合的重要因素。CHUNG 等^[52]报道,采用 OLIF 技术治疗 116 例腰椎合并 Modic 改变或终板硬化病例,并进行超过 1 年的随访,发现无论是椎间隙高度、融合器沉降或椎间融合均获得理想的结果。以上结果显示,Stand-alone OLIF 在 Modic 改变伴终板硬化融合的应用避免了本技术常见的问题,如术中终板损伤、术后融合器的明显沉降或移位等。

3.4 斜外侧椎间融合用于 Modic 改变伴终板硬化腰椎间盘退变的手术适应证

由于 Modic 改变伴终板硬化腰椎间盘退变多表现为慢性、顽固性腰痛,较少合并神经症状,且多发生于单节段。理论上讲,绝大部分发生于 L₁-L₅ 节段的 Modic 改变伴终板硬化的腰椎间盘退变均可采用 Stand-alone OLIF 治疗。而对于部分由于细菌感染所致的 Modic 改变,且终板有明显骨吸收,甚至破坏表现者,或腰椎以外部位有病灶者,建议慎用本手术方式。或炎症处于活动期,周围软组织内、椎管内有脓肿,或神经存在粘连甚至压迫,需要直接行病灶清除或神经减压、松解者,亦不适合采用本手术方式,至于 2 个节段或以上病变是否适用,有待进一步的临床实践。

3.5 本治疗方式的注意事项与本研究的不足

由于本病的特殊性,需要注意以下几点:(1)术前充分的检查,以明确椎间隙病灶的性质,如考虑为椎间隙炎,需要了解原发或继发,以及炎症所处的阶段等,必要时建议病灶活检,如发现明确的病原菌,建议采用敏感抗生素治疗^[53-54]。(2)由于本组病例病史较长,且椎间狭窄、僵硬,虽然终板均有增生、硬化,作椎间清理、松解和撑开时终板不易出现损伤,但仍要强调术中细致、规范的操作,特别是椎间的逐级撑开和融合器试模的逐级应用,以避免终板的损伤。(3)由于终板硬化,不利于骨愈合,建议椎间清理要更加彻底,植骨量要充足。不足之处:(1)临床上 Modic 改变主要为 I、II 型,III 型患者较少,且大部分病例通过保守治疗能获得较好的预后,需要采取手术干预的更少,因而本组样本量不大。(2)本组随访时间不够长,有待加强随访观察。(3)未与 OLIF 联

合椎弓螺钉固定方式,以及其他固定融合方式进行对比。

总之,由于 Modic 改变伴终板硬化腰椎间盘退变病例所特有的病史、椎间隙的病理改变,以及生物力学特点,只要严格掌握手术适应证,合适的病例选择,术前的充分检查,采用 Stand-alone OLIF 方式治疗 Modic 改变伴终板硬化的腰椎间盘退变临床优势明显,是较好的治疗选择。

参考文献

- [1] GUO R S, YANG X W, ZHONG Y C, et al. Correlations between modic change and degeneration in 3-joint complex of the lower lumbar spine: a retrospective study [J]. *Medicine (Baltimore)*, 2018, 97 (38): e12496.
- [2] 王牧一, 徐亮, 邱勇, 等. Modic 改变对腰椎经椎间孔椎间融合效果和融合器沉降的影响 [J]. *中华医学杂志*, 2019, 99 (47): 3703-3704.
WANG M Y, XU L, QIU Y, et al. Effect of Modic changes on lumbar interbody fusion through intervertebral foramen and fusion cage settlement [J]. *Natl Med J China*, 2019, 99 (47): 3703-3704. Chinese.
- [3] LV B, YUAN J S, DING H, et al. Relationship between endplate defects, modic change, disc degeneration, and facet joint degeneration in patients with low back pain [J]. *Biomed Res Int*, 2019, 2019: 9369853.
- [4] MACLEAN M A, KURESHI N, SHANKAR J, et al. Modic change and clinical assessment scores in patients undergoing lumbar surgery for disk herniation [J]. *Clin Spine Surg*, 2021, 34 (4): E205-E210.
- [5] SHAHMOHAMMADI M R, BEHROUZIAN S. Effect of preoperative modic change in the outcome of patients with low back pain following posterior spinal fusion or laminectomy [J]. *Asian J Neurosurg*, 2019, 14 (2): 432-435.
- [6] BRATEN L C H, SCHISTAD E I, ESPELAND A, et al. Association of Modic change types and their short tau inversion recovery signals with clinical characteristics-a cross sectional study of chronic low back pain patients in the AIM-study [J]. *BMC Musculoskelet Disord*, 2020, 21 (1): 368.
- [7] FIELDS A J, BALLATORI A, HAN M, et al. Measurement of vertebral endplate bone marrow lesion (Modic change) composition with water-fat MRI and relationship to patient-reported outcome measures [J]. *Eur Spine J*, 2021, 30 (9): 2549-2556.
- [8] APPLEBAUM A, NESSIM A, CHO W. Modic change: an emerging complication in the aging population [J]. *Clin Spine Surg*, 2022, 35 (1): 12-17.
- [9] MODIC M T, MASARYK T J, ROSS J S, et al. Imaging of degenerative disk disease [J]. *Radiology*, 1988, 168 (1): 177-186.
- [10] LIU J H, HUANG B, HAO L, et al. Association between Modic changes and endplate sclerosis: evidence from a clinical radiology study and a rabbit model [J]. *J Orthop Translat*, 2019, 16: 71-77.
- [11] PERILLI E, PARKINSON I H, TRUONG L H, et al. Modic (endplate) changes in the lumbar spine: bone micro-architecture and remodelling [J]. *Eur Spine J*, 2015, 24 (9): 1926-1934.
- [12] KIM S M, RHEE W, HA S, et al. Influence of alendronate and endplate degeneration to single level posterior lumbar spinal interbody fusion [J]. *Korean J Spine*, 2014, 11 (4): 221-226.

- [13] STAARTJES V E, VERGROESEN P A, ZEILSTRA D J, et al. Identifying subsets of patients with single-level degenerative disc disease for lumbar fusion: the value of prognostic tests in surgical decision making[J]. *Spine J*, 2018, 18(4): 558–566.
- [14] BUTTERMANN G R, MULLIN W J. Two-level circumferential lumbar fusion comparing midline and paraspinal posterior approach: 5-year interim outcomes of a randomized, blinded, prospective study[J]. *J Spinal Disord Tech*, 2015, 28(9): E534–E543.
- [15] HUNG C W, WU M F, HONG R T, et al. Comparison of multifidus muscle atrophy after posterior lumbar interbody fusion with conventional and cortical bone trajectory[J]. *Clin Neurol Neurosurg*, 2016, 145: 41–45.
- [16] 曾忠友, 裴斐, 张建乔, 等. 腰椎后路内固定融合术并发神经损伤的原因分析和处理[J]. *脊柱外科杂志*, 2016, 14(2): 83–86. ZENG Z Y, PEI F, ZHANG J Q, et al. Cause analysis and treatment of nerve damage after posterior lumbar fusion for lumbar disease[J]. *J Spinal Surg*, 2016, 14(2): 83–86. Chinese.
- [17] GHOBRIAL G M, WILLIAMS K A Jr, ARNOLD P, et al. Iatrogenic neurologic deficit after lumbar spine surgery: a review[J]. *Clin Neurol Neurosurg*, 2015, 139: 76–80.
- [18] 曾忠友, 吴鹏, 宋永兴, 等. 小切口单侧椎弓根螺钉联合对侧经椎板关节突螺钉固定并椎间融合治疗腰椎病变的并发症分析[J]. *中国骨伤*, 2016, 29(3): 232–241. ZENG Z Y, WU P, SONG Y X, et al. Unilateral pedicle screw fixation combined with contralateral percutaneous translaminar facet screw fixation and lumbar interbody fusion for the treatment of lower lumbar diseases: an analysis of complications[J]. *China J Orthop Traumatol*, 2016, 29(3): 232–241. Chinese.
- [19] SILVESTRE C, MAC-THIONG J M, HILMI R, et al. Complications and morbidities of mini-open anterior retroperitoneal lumbar interbody fusion: oblique lumbar interbody fusion in 179 patients[J]. *Asian Spine J*, 2012, 6(2): 89–97.
- [20] OHTORI S, ORITA S, YAMAUCHI K, et al. Mini-open anterior retroperitoneal lumbar interbody fusion: oblique lateral interbody fusion for lumbar spinal degeneration disease[J]. *Yonsei Med J*, 2015, 56(4): 1051–1059.
- [21] MOLLOY S, BUTLER J S, BENTON A, et al. A new extensile anterolateral retroperitoneal approach for lumbar interbody fusion from L₁ to S₁: a prospective series with clinical outcomes[J]. *Spine J*, 2016, 16(6): 786–791.
- [22] KIM K T, JO D J, LEE S H, et al. Oblique retroperitoneal approach for lumbar interbody fusion from L1 to S1 in adult spinal deformity[J]. *Neurosurg Rev*, 2018, 41(1): 355–363.
- [23] 曾忠友, 张建乔, 宋永兴, 等. 对比斜外侧椎间融合与后路融合治疗腰椎管狭窄症[J]. *中华骨科杂志*, 2020, 40(11): 707–718. ZENG Z Y, ZHANG J Q, SONG Y X, et al. Comparison of two different decompression and fusion methods in the treatment of lumbar spinal stenosis[J]. *Chin J Orthop*, 2020, 40(11): 707–718. Chinese.
- [24] BLIZZARD D J, THOMAS J A. MIS single-position lateral and oblique lateral lumbar interbody fusion and bilateral pedicle screw fixation: feasibility and perioperative results[J]. *Spine (Phila Pa 1976)*, 2018, 43(6): 440–446.
- [25] MEHREN C, MAYER H M, ZANDANELL C, et al. The oblique anterolateral approach to the lumbar spine provides access to the lumbar spine with few early complications[J]. *Clin Orthop Relat Res*, 2016, 474(9): 2020–2027.
- [26] HE W, HE D, SUN Y Q, et al. Quantitative analysis of paraspinal muscle atrophy after oblique lateral interbody fusion alone vs. combined with percutaneous pedicle screw fixation in patients with spondylolisthesis[J]. *BMC Musculoskelet Disord*, 2020, 21(1): 30.
- [27] FOGEL G R, TURNER A W, DOOLEY Z A, et al. Biomechanical stability of lateral interbody implants and supplemental fixation in a cadaveric degenerative spondylolisthesis model[J]. *Spine (Phila Pa 1976)*, 2014, 39(19): E1138–E1146.
- [28] LIU X L, MA J, PARK P, et al. Biomechanical comparison of multilevel lateral interbody fusion with and without supplementary instrumentation: a three-dimensional finite element study[J]. *BMC Musculoskelet Disord*, 2017, 18(1): 63.
- [29] ZENG Z Y, XU Z W, HE D W, et al. Complications and prevention strategies of oblique lateral interbody fusion technique[J]. *Orthop Surg*, 2018, 10(2): 98–106.
- [30] 曾忠友, 方向前, 马维虎, 等. 腰椎斜外侧椎间融合术中终板损伤的原因分析[J]. *中华骨科杂志*, 2020, 40(17): 1144–1154. ZENG Z Y, FANG X Q, MA W H, et al. Analysis the causes of endplate injury in oblique lateral interbody fusion[J]. *Chin J Orthop*, 2020, 40(17): 1144–1154. Chinese.
- [31] SCHIZAS C, THEUMANN N, BURN A, et al. Qualitative grading of severity of lumbar spinal stenosis based on the morphology of the dural sac on magnetic resonance images[J]. *Spine (Phila Pa 1976)*, 2010, 35(21): 1919–1924.
- [32] GLASER J, STANLEY M, SAYRE H, et al. A 10-year follow-up evaluation of lumbar spine fusion with pedicle screw fixation[J]. *Spine (Phila Pa 1976)*, 2003, 28(13): 1390–1395.
- [33] BRANTIGAN J W, NEIDRE A, TOOHEY J S. The Lumbar L/F Cage for posterior lumbar interbody fusion with the variable screw placement system: 10-year results of a Food and Drug Administration clinical trial[J]. *Spine J*, 2004, 4(6): 681–688.
- [34] FAIRBANK J C, PYNSENT P B. The Oswestry disability index[J]. *Spine (Phila Pa 1976)*, 2000, 25(22): 2940–2952.
- [35] TSCHUGG A, HARTMANN S, LENER S, et al. Minimally invasive spine surgery in lumbar spondylodiscitis: a retrospective single-center analysis of 67 cases[J]. *Eur Spine J*, 2017, 26(12): 3141–3146.
- [36] ZHANG T, HU J Z, WU J H, et al. One-stage posterior debridement and fusion combined with irrigation and drainage for the treatment of postoperative lumbar spondylodiscitis[J]. *Acta Orthop Traumatol Turc*, 2018, 52(4): 277–282.
- [37] CHEN M J, NIU C C, HSIEH M K, et al. Minimally invasive transforaminal lumbar interbody debridement and fusion with percutaneous pedicle screw instrumentation for spondylodiscitis[J]. *World Neurosurg*, 2019, 128: e744–e751.
- [38] OWENS K, GLASSMAN S D, HOWARD J M, et al. Perioperative complications with rhBMP-2 in transforaminal lumbar interbody fusion[J]. *Eur Spine J*, 2011, 20(4): 612–617.
- [39] 曾忠友, 宋永兴, 严卫锋, 等. 通道下肌间隙入路腰椎固定融合术并发神经损伤的原因及预防[J]. *脊柱外科杂志*, 2017, 15(4): 211–216. ZENG Z Y, SONG Y X, YAN W F, et al. Cause analysis and preventive strategy for nerve injury in lumbar vertebra fixation and

- fusion using a channel via muscle-splitting approach[J]. *J Spinal Surg*, 2017, 15(4):211–216. Chinese.
- [40] MORO T, KIKUCHI S I, KONNO S I, et al. An anatomic study of the lumbar plexus with respect to retroperitoneal endoscopic surgery[J]. *Spine (Phila Pa 1976)*, 2003, 28(5):423–428.
- [41] HU W K, HE S S, ZHANG S C, et al. An MRI study of psoas major and abdominal large vessels with respect to the X/DLIF approach[J]. *Eur Spine J*, 2011, 20(4):557–562.
- [42] 赵凤东, 范顺武, Patricia Dolan, 等. 腰椎终板骨折特点及相关因素的实验研究[J]. *中华外科杂志*, 2006, 44(16):1132–1135. ZHAO F D, FAN S W, DOLAN P, et al. The feature of experimental endplate fracture in lumbar spine and its related factors[J]. *Chin J Surg*, 2006, 44(16):1132–1135. Chinese.
- [43] 赵凤东, 范顺武, 丁献军, 等. 中老年人腰椎椎体区域性骨密度差异与力学特性的关系[J]. *中华物理医学与康复杂志*, 2006, 28(7):473–477. ZHAO F D, FAN S W, DING X J, et al. Bone mineral density and bone mineral content in the lumbar vertebrae and the vertebra's biomechanical properties[J]. *Chin J Phys Med Rehabil*, 2006, 28(7):473–477. Chinese.
- [44] KIM J S, CHOI W S, SUNG J H. Minimally invasive oblique lateral interbody fusion for L_{4,5}[J]. *Neurosurgery*, 2016, 63 (Supplement 1):190–191.
- [45] WOODS K R, BILLYS J B, HYNES R A. Technical description of oblique lateral interbody fusion at L₁–L₅ (OLIF25) and at L₅S₁ (OLIF51) and evaluation of complication and fusion rates[J]. *Spine J*, 2017, 17(4):545–553.
- [46] 王吉莹, 周志杰, 范顺武, 等. 斜外侧椎间融合术治疗腰椎退行性疾病的早期并发症分析[J]. *中华骨科杂志*, 2017, 37(16):1006–1013. WANG J Y, ZHOU Z J, FAN S W, et al. Early complications associated with oblique lateral interbody fusion in the treatment of degenerative lumbar diseases[J]. *Chin J Orthop*, 2017, 37(16):1006–1013. Chinese.
- [47] WU H, CHEUNG J P Y, ZHANG T, et al. The role of Hounsfield unit in intraoperative endplate violation and delayed cage subsidence with oblique lateral interbody fusion[J]. *Global Spine J*, 2021:21925682211052515.
- [48] LIU J H, DING W Y, YANG D L, et al. Modic changes (MCs) associated with endplate sclerosis can prevent cage subsidence in oblique lumbar interbody fusion (OLIF) stand-alone[J]. *World Neurosurg*, 2020, 138:e160–e168.
- [49] KIM S M, RHEE W, HA S, et al. Influence of alendronate and endplate degeneration to single level posterior lumbar spinal interbody fusion[J]. *Korean J Spine*, 2014, 11(4):221–226.
- [50] LI H, CHEN S, WEI H Y, et al. Type 2 sclerotic Modic change affect fusion result in patients undergoing PLIF with pedicle screw instrumentation; a retrospective study[J]. *BMC Musculoskelet Disord*, 2021, 22(1):598.
- [51] LI J X, PHAN K, MOBBS R. Oblique lumbar interbody fusion; technical aspects, operative outcomes, and complications[J]. *World Neurosurg*, 2017, 98:113–123.
- [52] CHUNG N S, LEE H D, JEON C H. The impact of vertebral endplate lesions on the radiological outcome in oblique lateral interbody fusion[J]. *Global Spine J*, 2021, 11(8):1176–1182.
- [53] NAM K H, SONG G S, HAN I H, et al. Diagnostic value of biopsy techniques in lumbar spondylodiscitis: percutaneous needle biopsy and open biopsy[J]. *Korean J Spine*, 2011, 8(4):267–271.
- [54] SPIRA D, GERMANN T, LEHNER B, et al. CT-guided biopsy in suspected spondylodiscitis: the association of paravertebral inflammation with microbial pathogen detection[J]. *PLoS One*, 2016, 11(1):e0146399.

(收稿日期:2022-04-11 本文编辑:王宏)