

前路不同手术方式治疗单节段颈椎间盘突出症的疗效比较

范亚一, 段亮, 徐洪海, 刘军, 祁洁, 弓立群

(陕西省人民医院骨科病院, 陕西 西安 710068)

【摘要】 目的: 比较前路不同手术方式治疗单节段颈椎间盘突出症患者的临床疗效。**方法:** 对 2013 年 9 月至 2018 年 9 月手术治疗的 46 例单节段颈椎间盘突出症患者临床资料进行回顾性分析,按不同的手术方法将患者分为 3 组,其中经皮前路椎间孔镜下颈椎间盘髓核摘除术(anterior percutaneous endoscopic cervical dissection, APECD)组 23 例,男 8 例,女 15 例,年龄(47±3)岁,突出节段 C_{3,4} 1 例,C_{4,5} 6 例,C_{5,6} 16 例;颈椎间盘置换术(cervical disc replacement, CDR)组 10 例,男 4 例,女 6 例,年龄(46±3)岁,突出节段 C_{3,4} 1 例,C_{4,5} 6 例,C_{5,6} 3 例;经颈前路椎间盘切除减压融合术(anterior cervical disc fusion, ACDF)组 13 例,男 8 例,女 5 例,年龄(53±2)岁,突出节段 C_{3,4} 1 例,C_{4,5} 3 例,C_{5,6} 9 例。对 3 组患者的手术时间、术中出血量、住院时间进行比较;并采用疼痛视觉模拟评分(visual analogue scale, VAS)及日本骨科协会(Japanese Orthopaedic Association, JOA)评分评价 3 组患者的临床疗效。**结果:** 46 例患者均获得随访,时间 12~24(17.57±3.15)个月。APECD, CDR, ACDF 组随访时间分别为(17.30±3.25), (17.80±3.16), (17.85±2.88)个月,两两比较差异均无统计学意义($P>0.05$);手术时间分别为(95.48±13.85), (58.50±7.09), (76.00±15.72) min, 两两比较差异均有统计学意义($P<0.05$);术中出血量分别(80.00±20.22), (82.60±7.20), (121.54±18.75) ml, CDR 组和 ACDF 组比较差异有统计学意义($P<0.05$), 其余比较差异无统计学意义($P>0.05$);3 组住院时间分别为(6.95±1.50), (6.60±0.80), (6.54±0.75) d, 两两比较差异无统计学意义($P>0.05$)。末次随访时 VAS 评分 APECD 组从术前的 6.78±0.83 降到 2.57±0.65;CDR 组从术前的 5.70±0.78 降到 2.00±0.45;ACDF 组从术前的 6.77±0.42 降低到 1.38±0.49;JOA 评分 APECD 组从术前的 8.91±0.97 增加到 13.04±1.40,改善率(65±15)%;CDR 从术前的 11.50±1.20 增加到 14.90±1.14,改善率(76±19)%;ACDF 组从术前的 8.54±0.93 增加到 14.00±0.96,改善率(74±8)%。各组改善率之间两两比较 APECD 组和 CDR 组差异有统计学意义($P<0.05$)。末次随访时 APECD 组和 CDR 组责任节段活动度均良好保留,并有所改善($P<0.05$)。APECD 组在中期随访(术后 4 和 6 个月)中出现 2 例症状复发,其中 1 例严格保守治疗后好转;另 1 例二次行 ACDF 手术,术后随访疗效满意。**结论:** 3 种前路手术方式治疗单节段颈椎间盘突出症均可获得满意的临床疗效,但 CDR 改善率及保留责任节段活动度优于其他两种术式,APECD 有复发的可能。

【关键词】 颈椎; 椎间盘移位; 外科手术

中图分类号:R681.5

DOI: 10.12200/j.issn.1003-0034.2021.04.012

开放科学(资源服务)标识码(OSID):



Comparison of clinical effects of different anterior surgical methods for the treatment of single segment cervical disc herniation FAN Ya-yi, DUAN Liang, XU Hong-hai, LIU Jun, QI Jie, and GONG Li-qun. Orthopedic Hospital of Shaanxi People's Hospital, Xi'an 710068, Shanxi, China

ABSTRACT Objective: To compare the clinical effects of different anterior surgical methods in treating single segment cervical disc herniation. **Methods:** The clinical data of 46 patients with single-segment cervical disc herniation underwent surgical treatment from September 2013 to September 2018 were retrospectively analyzed. The patients were divided into three groups according to different surgical methods. Among them, 23 patients in the anterior percutaneous endoscopic cervical dissection (APECD) group, there were 8 males and 15 females, aged (47±3) years old, prominent segments were C_{3,4} of 1 case, C_{4,5} of 6 cases, and C_{5,6} of 16 cases; 10 patients in cervical disc replacement (CDR) group, there were 4 males and 6 females, aged (46±3) years old, prominent segments were C_{3,4} of 1 case, C_{4,5} of 6 cases, C_{5,6} of 3 cases; 13 patients in transcervical anterior cervical disc fusion (ACDF) group, there were 8 males and 5 females, aged (53±2) years old, protruding segments were C_{3,4} of 1 case, C_{4,5} of 3 cases, C_{5,6} of 9 cases. The operation time, intraoperative blood loss, and length of hospitalization were compared

基金项目:陕西省自然科学基金(编号:2014JQ4125)

Fund program: Shaanxi Natural Science Foundation (No. 2014JQ4125)

通讯作者:段亮 E-mail: duanliang0620@163.com

Corresponding author: DUAN Liang E-mail: duanliang0620@163.com

among three groups; visual analogue scale (VAS) and Japanese Orthopaedic Association (JOA) score were used to evaluate the clinical efficacy. **Results:** All 46 patients were followed up for 12 to 24 (17.57±3.15) months. The follow-up time of APECD, CDR, ACDF groups were (17.30±3.25), (17.80±3.16), (17.85±2.88) months, and operation time were (95.48±13.85), (58.50±7.09), (76.00±15.72) min, respectively, there were no significant differences in follow-up time and operation time between two groups ($P>0.05$). The intraoperative blood loss of APECD, CDR, ACDF groups were (80.00±20.22), (82.60±7.20), (121.54±18.75) ml, there was significant difference between CDR group and ACDF group ($P<0.05$); and there was no significant difference between other groups ($P>0.05$). The length of hospitalization was (6.95±1.50) days in APECD group, (6.60±0.80) days in CDR group, (6.54±0.75) days in ACDF group, and there was no significant difference between two groups ($P>0.05$). At the latest follow-up, VAS scores were decreased from preoperative 6.78±0.83 to 2.57±0.65 in APECD group, decreased from 5.70±0.78 to 2.00±0.45 in CDR group, decreased from 6.77±0.42 to 1.38±0.49 in ACDF group. The JOA scores at final follow-up were increased from 8.91±0.97 to 13.04±1.40 in APECD group, and the improvement rate of (65±15)%; increased from 11.50±1.20 to 14.90±1.14 in CDR group, and the improvement rate of (76±19)%; increased from 8.54±0.93 to 14.00±0.96 in ACDF group, and the improvement rate of (74±8)%; there was significant difference in improvement rate between APECD group and CDR group ($P<0.05$). At final follow-up, the activities of the responsible segment in APECD group and CDR group were well preserved and improved ($P<0.05$). In the APECD group, the symptoms of two cases recurred during the mid-term follow-up (4 months and 6 months after surgery), one of which improved after strictly conservative treatment; the other one received ACDF surgery a second time, and the postoperative follow-up effect was satisfactory. **Conclusion:** The three anterior surgical approaches can achieve satisfactory clinical results for the treatment of single-segment cervical disc herniation. However, the improvement rate of the CDR group and the activity of the retained responsibility segment are better than those of the other two groups. APECD surgery may have recurrence.

KEYWORDS Cervical vertebrae; Intervertebral disc displacement; Surgical procedures, operative

随着影像学技术迅猛发展，颈椎间盘突出症的诊断率逐渐提高。若颈椎间盘退变持续加重，会出现不同程度的四肢瘫，严重影响日常生活，此时前路减压手术是治疗的有效方法之一。我院自 2013 年 9 月至 2018 年 9 月，对 46 例单节段颈椎间盘突出症患者分别应用经皮前路椎间孔镜下颈椎间盘髓核摘除术 (anterior percutaneous endoscopic cervical discectomy, APECD), 颈椎间盘置换术 (cervical disc replacement, CDR) 和颈前路椎间盘切除减压融合术 (anterior cervical discectomy and fusion, ACDF) 进行治疗。笔者回顾性比较 3 种手术方法的临床效果，现报告如下。

1 资料与方法

1.1 病例选择

1.1.1 纳入标准 (1)表现四肢不全瘫，伴眩晕。(2)腱反射活跃或亢进，Hoffmann 征阳性。(3)X 线显示颈椎受累椎间隙为单个节段并变窄，MRI 显示压

迫主要来自脊髓腹侧的单节段病变，伴或不伴 T2 高信号。(4)骨密度检查基本正常或轻度骨质疏松。

1.1.2 排除标准 (1)患有 2 个以上节段受累的颈椎间盘突出。(2)过伸过屈位 X 线失稳；伴严重连续性后纵韧带骨化。(3)伴其他神经系统疾病；既往有颈椎颅脑手术、感染、肿瘤等病史。

1.2 一般资料

本研究共纳入 46 例，男 20 例，女 26 例，年龄 38 ~76 (48±6) 岁。病程 5 个月 ~ 5 年 3 个月，平均 (26±7) 个月。3 组患者性别、年龄、体重指数、突出节段、病程等一般资料比较差异无统计学意义 ($P>0.05$)，见表 1。

1.3 治疗方法

患者均采用仰卧位，肩下垫薄枕，颈部自然后仰，双肩宽胶布粘贴牵拉与手术床粘贴在一起以便充分显露手术区域。3 组患者术前均给予 160 mg 甲泼尼龙琥珀酸钠静脉点滴。

表 1 各组颈椎间盘突出症患者术前一般资料比较

Tab.1 Comparison of preoperative general data of patients with cervical disc herniation among three groups

项目	例数	年龄 ($\bar{x}\pm s$, 岁)	性别(例)		病程 ($\bar{x}\pm s$, 月)	体重指数 ($\bar{x}\pm s$, kg/m ²)	突出节段(例)		
			男	女			C _{3,4}	C _{4,5}	C _{5,6}
APECD 组	23	47±3	8	15	14±4	25.6±3.5	1	6	16
CDR 组	10	46±3	4	6	17±5	22.6±2.8	1	6	3
ACDF 组	13	53±2	8	5	16±7	24.3±3.1	1	3	9
检验值		F=1.76	$\chi^2=0.014$		F=0.32	F=0.80	$\chi^2=0.048$		
P 值		0.07	0.911		0.76	0.43	0.826		

1.3.1 APECD 组 局部浸润麻醉。通常于患者病理改变或临床症状出现部位的对侧进行穿刺, 穿刺点选取颈部正中旁开约 2 cm, 在穿刺点局部做小切口, 切开皮肤及颈阔肌, 钝性分离, 使用特制 18 号穿刺针穿刺, 在 C 形臂 X 线动态透视下到达责任间隙, 期间微调针尖, 向病变椎间盘内注射染色剂造影。造影完成后, 通过穿刺针放置导丝, 移除穿刺针, 在 C 形臂 X 线透视下, 放入 3 级扩张管, 沿扩张管放置工作套管, 确定位置良好后。经工作套管放入椎间孔镜, 可见蓝染椎间盘组织。使用髓核钳摘除椎间盘组织。待突出椎间盘髓核组织清除干净后, 使用射频消融电极对出血部位进行止血, 对破损纤维环进行处理, 切口覆盖无菌辅料包扎固定。典型病例见图 1。

1.3.2 CDR 组 静脉全麻。磨钻处理上下椎体终板, 试模、安装合适 Discover 人工椎间盘。典型病例见图 2。

1.3.3 ACDF 组 选用上海三友 颈前路 Carmen 卡门同步适稳颈椎融合系统。静脉全麻, 然后将自体减压骨塞入 PEEK 融合器后置入减压椎间隙。选用颈前路低切迹锁定钛板固定。典型病例见图 3。

1.3.4 术后处理 术后 72 h 内静脉滴注抗生素、小剂量激素。APECD 组术后 2 h 后可携带颈托下地

活动; CDR 组和 ADCF 组术后 24 ~48 h 拔除引流管后佩戴颈托下床活动, 一般制动 4 ~6 周后可去除颈托进行适当的功能锻炼。

1.4 观察项目与方法

1.4.1 一般情况观察 记录手术时间、术中出血量、住院时间及并发症情况。

1.4.2 影像学观察 术前及末次随访在过伸和过屈位 X 线片上测量置换节段活动度。测量方法: 责任间隙上位椎体后缘连线 A 及下位椎体后缘连线 B 的夹角, 屈曲时 b1, 过伸时 b2, 责任间隙活动度 (b = b1 + b2), 若屈曲位 A 在 B 之前 b1 为正值, 相反为负值。过伸位 A 在 B 之后 b2 为正值, 相反为负值。

1.4.3 临床疗效观察 术前及末次随访采用日本骨科协会 (Japanese Orthopaedic Association, JOA) 评分评定神经功能改善情况, 并计算改善率, 改善率 75% 以上为优, 50% ~74% 为良, 25% ~49% 为可, 25% 以下为差。患者于治疗前及末次随访采用疼痛视觉模拟评分 (visual analogue scale, VAS) 评估疼痛情况。

1.5 统计学处理

采用 SPSS 15.0 软件进行统计学分析。定量资料均以均数 ± 标准差 ($\bar{x} \pm s$) 表示, 采用成组设计资料 t 检验或配对设计资料 t 检验; 计数资料组间比较采

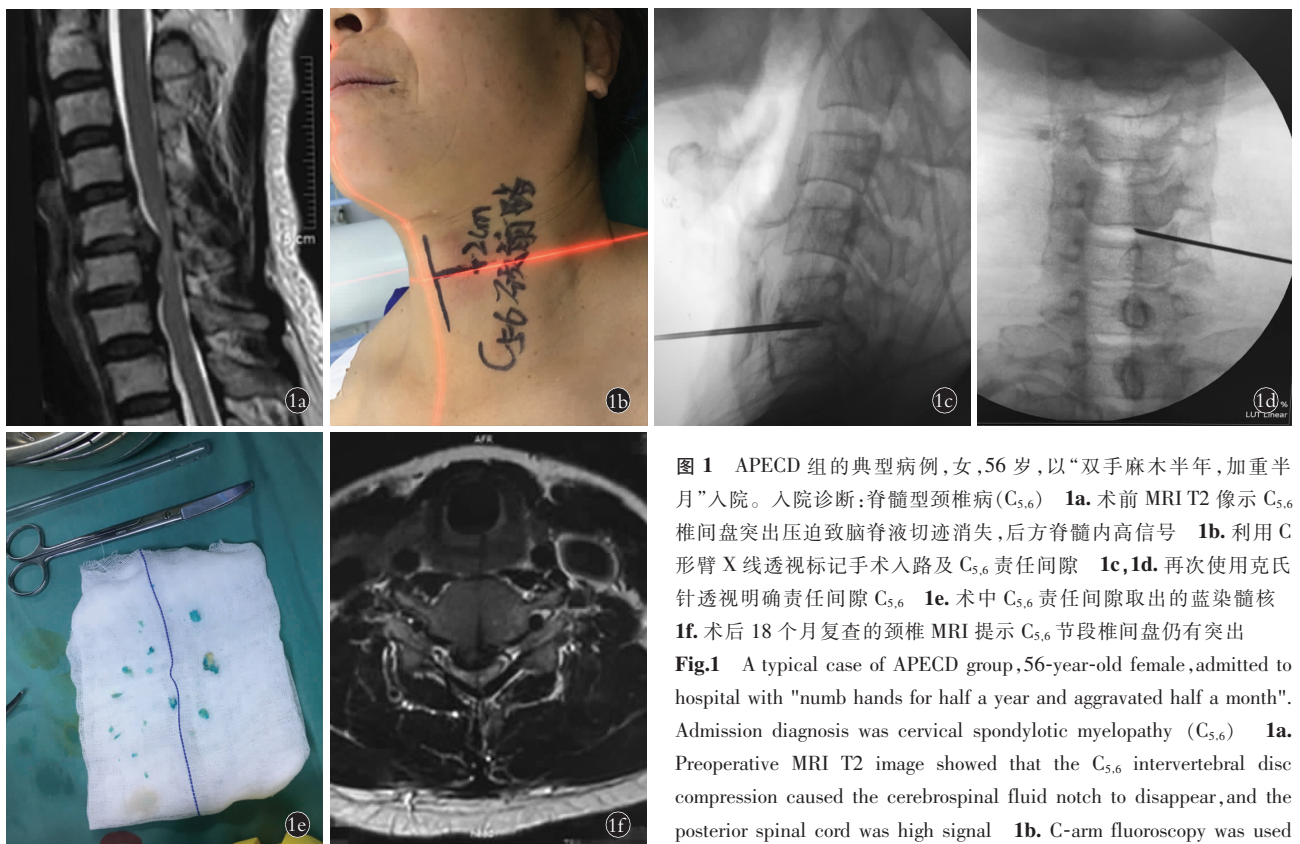

图 1 APECD 组的典型病例, 女, 56 岁, 以“双手麻木半年, 加重半月”入院。入院诊断: 脊髓型颈椎病 (C_{5,6}) **1a.** 术前 MRI T2 像示 C_{5,6} 椎间盘突出压迫致脑脊液切迹消失, 后方脊髓内高信号 **1b.** 利用 C 形臂 X 线透视标记手术入路及 C_{5,6} 责任间隙 **1c, 1d.** 再次使用克氏针透视明确责任间隙 C_{5,6} **1e.** 术中 C_{5,6} 责任间隙取出的蓝染髓核 **1f.** 术后 18 个月复查的颈椎 MRI 提示 C_{5,6} 节段椎间盘仍有突出

Fig.1 A typical case of APECD group, 56-year-old female, admitted to hospital with "numb hands for half a year and aggravated half a month". Admission diagnosis was cervical spondylotic myelopathy (C_{5,6}) **1a.** Preoperative MRI T2 image showed that the C_{5,6} intervertebral disc compression caused the cerebrospinal fluid notch to disappear, and the posterior spinal cord was high signal **1b.** C-arm fluoroscopy was used to mark surgical approach and C_{5,6} responsibility gap during operation

1c, 1d. Kirschner wire fluoroscopy was again used to clarify the responsibility gap C_{5,6} **1e.** Intraoperative blue-stained nucleus pulposus taken out between C₅ and C₆ **1f.** MRI of the cervical spine showed that the C_{5,6} still had protrusion at 18 months after surgery

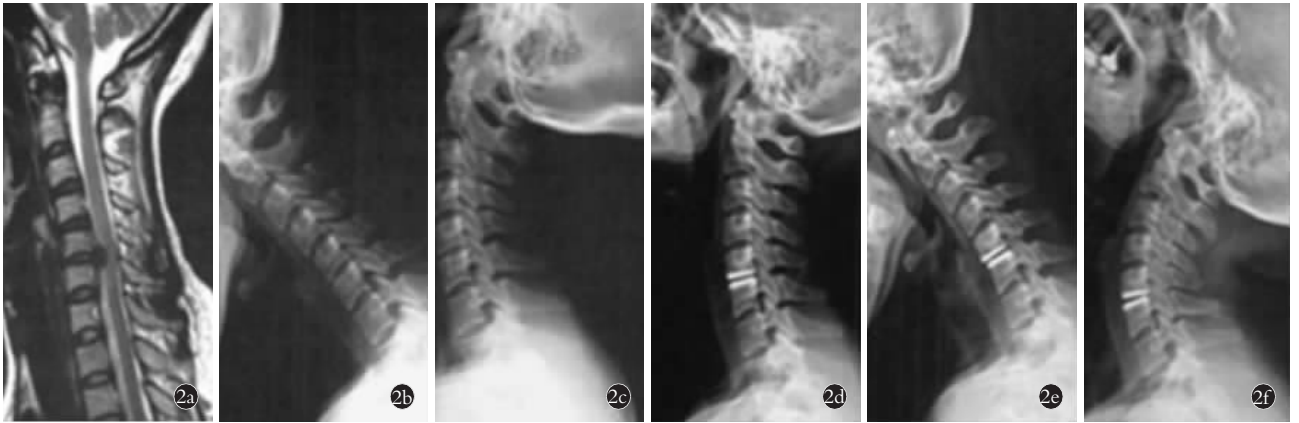

图 2 CDR 组典型病例,女,56 岁,以“双上肢麻木 3 个月,加重半月”入院。入院诊断:脊髓型颈椎病(C_{5,6}) **2a,2b,2c**. 术前 MRI 及过伸过屈位 X 线片示无失稳 **2d,2e,2f**. 术后 18 个月侧位及过伸过屈位 X 线片可见假体位置良好,颈椎活动度良好,较术前明显改善,未出现异位骨化
Fig.2 A typical case of CDR group,56-year-old female,admitted to hospital with "numb upper limbs numbness for three months,aggravated by half a month". Admission diagnosis was cervical spondylotic myelopathy (C_{5,6}) **2a,2b,2c**. Preoperative MRI and X-rays of hyperextension and hyperflexion showed no instability **2d,2e,2f**. At 18 months after operation,X-rays of lateral position and hyperextension and hyperflexion showed that the prosthesis was on good position and the cervical spine mobility was good,which was significantly improved compared with preoperatively,without heterotopic ossification

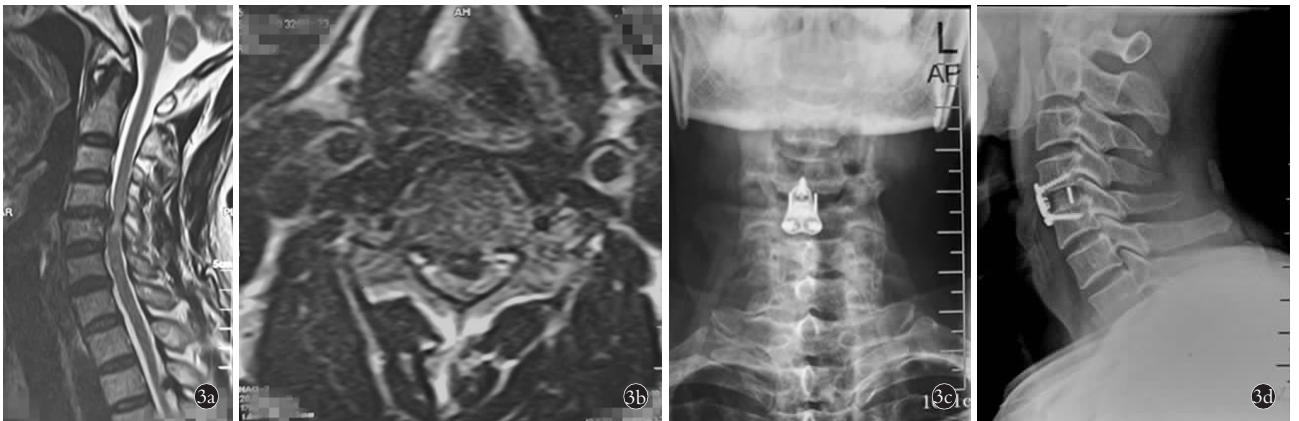


图 3 ACDF 组典型病例,男,51 岁,以“四肢麻木无力 3 个月,加重半月”入院。入院诊断:脊髓型颈椎病(C_{4,5}) **3a**. 术前 MRI T2 像提示 C_{4,5} 椎间盘呈黑椎间盘改变,突出致该节段脑脊液切迹缺失,相应节段后方脊髓伴高信号 **3b**. 术前 MRI 轴位像示 C_{4,5} 椎间盘右侧旁中央型突出压迫侧隐窝 **3c,3d**. 术后 18 个月末次随访颈椎正侧位 X 线 C₄-C₅ 椎体卡门一体系统内固定螺钉及融合器位置良好
Fig.3 A typical case of ACDF group,51-year-old male,admitted to the hospital with "numb limbs weakness for three months,aggravated by half a month". Admission diagnosis was cervical spondylotic myelopathy (C_{4,5}) **3a**. Preoperative MRI T2 image showed that the C_{4,5} intervertebral disc was black intervertebral disc change,and the protrusion caused the loss of cerebrospinal fluid notch in this segment. the spinal cord behind the corresponding segment was accompanied by high signal **3b**. Preoperative MRI of the axial image showed the right lateral central protrusion of the C_{4,5} intervertebral disc compressed the lateral recess **3c,3d**. At 18 months after operation,AP and lateral X-rays showed that the internal fixation screw and fusion device of C₄-C₅ vertebral body Carmen integrated system were in good position

用 χ^2 检验。以 $P < 0.05$ 为差异有统计学意义。

2 结果

2.1 一般情况

(1)手术时间:APECD 组为 (95.48 ± 13.85) min, CDR 组为 (58.50 ± 7.09) min,ACDF 组为 (76.00 ± 15.72) min,两两比较差异均有统计学意义 ($P < 0.05$)。(2)术中出血量:APECD 组为 (80.00 ± 20.22) ml, CDR 组为 (82.60 ± 7.20) ml,ACDF 组为 (121.54 ± 18.75) ml,3 组之间两两比较,CDR 组和 ACDF 组差

异有统计学意义 ($t=7.72, P < 0.05$)。(3)住院时间:APECD 组 (6.95 ± 1.50) d, CDR 组 (6.60 ± 0.80) d, ACDF 组 (6.54 ± 0.75) d,两两比较差异均无统计学意义 ($P > 0.05$)。

2.2 影像学及临床疗效的观察

本组患者均获得随访,随访时间 12~24 (17.57 ± 3.15) 个月。APECD,CDR,ACDF 组随访时间分别为 (17.30 ± 3.25) 、 (17.80 ± 3.16) 、 (17.85 ± 2.88) 个月,两两比较差异均无统计学意义 (APECD 与 CDR 组比

较, $t=1.0, P=0.343$; APECD 与 ACDF 组比较, $t=-0.4, P=0.687$; CDR 组与 ACDF 组比较, $t=1.0, P=0.343$)。APECD 组和 CDR 组末次随访时责任节段活动度均良好保留, 且有所改善 ($P<0.05$)。见表 2。3 组在 JOA、VAS 评分方面比较见表 3, JOA 改善率 APECD, CDR, ACDF 组分别是 $(65 \pm 15)\%$ 、 $(76 \pm 19)\%$ 、 $(74 \pm 8)\%$, APECD 组和 CDR 组改善率差异有统计学意义 ($\chi^2=4.103, P<0.05$)。3 组各出现 1 例术后轻度吞咽困难, 予以雾化吸入、给予胃肠动力药物、 β 受体阻滞剂等对症处理后 1 个月内症状基本缓解; 3 组各出现 1 例术后一过性不完全脊髓损伤, 均在 24 h 内恢复。3 组并发症发生率比较差异无统计学意义 ($P>0.05$)。APECD 组在中期随访(术后 4 个月和 6 个月)中出现 2 例患者症状复发, 复发率 8.7%, 其中 1 例严格保守治疗后好转, 未进行手术干预; 另外 1 例保守治疗 1 个月后, 症状改善不明显, 与患者及家属沟通后, 再次行 ACDF 手术进行彻底减压二次手术治疗(二次术后随访 18 个月, 末次随访 JOA 评分为 16 分, 较术前的 7 分改善率为 90%)。

表 2 APECD 组和 CDR 组颈椎间盘突出症患者术中和末次随访时责任节段活动度比较 ($\bar{x} \pm s, ^\circ$)

Tab.2 Comparison of range of motion with responsible segment in patients with cervical disc herniation between APECD group and CDR group before and at final follow-up ($\bar{x} \pm s, ^\circ$)

组别	例数	术前	末次随访	t 值	P 值
APECD 组	23	8.57±2.22	8.83±2.15	-2.313	0.030
CDR 组	10	7.70±2.69	10.10±2.02	-3.882	0.004

3 讨论

ACDF 手术是治疗颈椎间盘突出症的传统手术方式之一, 目前文献复习发现该术式有以下不足:

(1)牺牲了责任间隙的运动功能, 增加了邻节段椎间盘应力, 加快了退变速率, 远期出现新的症状。(2)植骨源限制, PEEK 融合器内填塞了异体骨, 增加了因植入异体骨导致骨不连、感染的概率^[1]。(3)传统颈前路钢板厚, 切迹高, 术后发生吞咽困难等颈前方不适感并发症较多。本文 ACDF 组为规避传统颈前路钢板的诸多不足采用了上海三友卡门同步适稳颈椎融合系统, 该系统钢板薄, 低切迹, 螺钉少, 对周围软组织刺激减少显著, 且钢板和融合器一体化设计, 避免了术后吞咽活动时致颈前不适, 同时一体化结构, 大大减少了植骨量, 避免了在单节段颈椎间盘突出患者手术中额外使用同种异体骨的使用率, 降低了术后切口感染的发生, 增加了椎间融合率。

CDR 和 APECD 术式均可以保留责任间隙运动功能, 减慢邻近节段退变速率^[2-3]。本文 CDR 组和 APECD 组在末次随访结果中证实了责任间隙活动度不仅保留且得到了改善。CDR 组手术操作时间明显短于其他两组; 但 CDR 术式对于中重度骨质疏松患者禁止使用, 因为假体上下的金属终板需要牢固的嵌入椎体, 椎体的骨质需要起到支撑高度的作用, 否则容易出现陷入椎体, 椎间高度丢失, 远期松动^[4]等并发症。CDR 术式^[2-5]因保留责任间隙活动度, 减少了邻近节段应力, 降低了退变速率。Bartels 等^[6]对所有 ACDF 组与 CDR 组比较的 RCT 文献进行了 Meta 分析, 没有足够的证据显示 CDR 在保留责任间隙活动度方面优于 ACDF。本文术后 ACDF 组和 CDR 组之间 JOA 改善率结果显示也无明显差异。

吴新等^[7]报道, APECD 利用了微创通道下椎间盘部分摘除联合射频消融技术治疗颈椎间盘突出术后患者效果满意, 本文 APECD 组患者术后 JOA 评分及中短期随访也证实了 APECD 的有效性和满意度。APECD 和射频消融纤维环成形联合手术的目的: (1)减轻椎间盘容积及压力, Sim 等^[8]和 Timmer-

表 3 各组颈椎间盘突出症患者术前与末次随访 JOA 和 VAS 评分比较 ($\bar{x} \pm s$, 分)

Tab.3 Comparison of JOA and VAS before operation and final follow-up among three groups with cervical disc herniation ($\bar{x} \pm s$, score)

组别	例数	VAS 评分		t 值	P 值	JOA 评分		t 值	P 值
		术前	末次随访			术前	末次随访		
APECD 组	23	6.78±0.83	2.57±0.65 ^{▲▲}	8.84	0	8.91±0.97	13.04±1.40 ^{▲▲▲▲}	-11.38	0
CDR 组	10	5.70±0.78	2.00±0.45 ^{□□}	11.04	0	11.50±1.20	14.00±1.14 ^{□□□□}	-6.94	0
ACDF 组	13	6.77±0.42	1.38±0.49 ^{▲▲}	29.84	0	8.54±0.93	14.00±0.96 ^{▲▲▲▲}	-11.38	0

注: ▲▲▲▲与□□□□比较, $t=0.44, P=0.036<0.05$; ▲▲▲▲与▲▲▲▲比较, $t=0.48, P=0<0.05$; □□□□与▲▲▲▲比较, $t=0.54, P=0.1>0.05$ 。▲▲与□□比较, $t=0.197, P=0<0.05$; ▲▲与▲▲比较, $t=0.193, P=0.02<0.05$; □□与▲▲比较, $t=0.014, P=0.19>0.05$

Note: ▲▲▲▲vs□□□□, $t=0.44, P=0.036<0.05$; ▲▲▲▲vs▲▲▲▲, $t=0.48, P=0<0.05$; □□□□vs▲▲▲▲, $t=0.54, P=0.1>0.05$ 。▲▲vs□□, $t=0.197, P=0<0.05$; ▲▲vs▲▲, $t=0.193, P=0.02<0.05$; □□vs▲▲, $t=0.014, P=0.19>0.05$

mann 等^[9]报道低温消融过程和热凝均可降低椎间盘体积从而进一步使盘内压力降低,使症状进一步减轻。(2)可以对椎间盘退变相关的炎症因子灭活^[10-12];射频消融通过射频能量影响椎间盘细胞外环境,通过下调局部炎性介质、减少鲁菲尼小体^[13]及疼痛感受器而缓解颈部疼痛、眩晕;同时上调组织修复因子刺激血管生成,激发愈合过程^[14]。本文 APECD 组患者手术随访疗效也可以佐证以上推论。但本文 APECD 组目前随访发现有复发的案例,应在手术中得到足够重视,与术中对剩余髓核、纤维环破口等处理技术有关。文献报道微创手术并不能显著提高患者神经功能和生活质量,与开放手术比较均可以取得较为满意的临床疗效,二者之间差异无统计学意义^[15-16]。

综上所述,上述 3 种手术方法治疗单节段颈椎间盘突出均可取得满意的临床疗效。APECD 术具有微创术中出血量少等优点,但有透视次数多,有复发的可能,长期随访 ACDF 术式有远期增加邻椎间盘退变的可能;而 ACDF 和 CDR 术式能够长时间维持颈椎生理曲度和椎间高度,较好保留了责任间隙活动度,避免了邻椎病的发生,且 CDR 组随访 JOA 改善率显著,是一种理想的手术方式。

参考文献

- [1] 丁琛,刘浩,胡韬,等.单节段人工颈椎间盘置换与前路融合术的对照研究[J].中华骨科杂志,2012,32(1):32-38.
DING C,LIU H,HU T,et al. Comparative study of single-segment artificial cervical disc replacement and anterior fusion[J]. Zhonghua Gu Ke Za Zhi,2012,32(1):32-38. Chinese.
- [2] 马迅,马刚,冯皓宇,等.人工颈椎间盘置换术适应证及疗效探讨[J].中华骨科杂志,2010,30(9):832-836.
MA X,MA G,FENG HY,et al. Discussion on the indications and effects of artificial cervical disc replacement[J]. Zhonghua Gu Ke Za Zhi,2010,30(9):832-836. Chinese.
- [3] Zhu Y,Tian Z,Zhu B,et al. Bryan cervical disc arthroplasty versus anterior cervical discectomy and fusion for treatment of cervical disc diseases:a Meta-analysis of prospective,randomized controlled trials[J]. Spine(Phila Pa 1976),2016,41(12):E733-E741.
- [4] Pointillart V. Cervical disc prosthesis in humans:first failures[J]. Spine(Phila Pa 1976),2001,26:E90-E92.
- [5] 李晋玉,贾育松,郑晨颖,等. Bryan 颈椎间盘置换在治疗颈椎病中对颈椎曲度和置换节段的影响[J].中国骨伤,2018,31(8):

751-756.

- LI JY,JIA YS,ZHENG CY,et al. Effect of Bryan cervical disc replacement on cervical curvature and replacement level in the treatment of cervical spondylosis[J]. Zhongguo Gu Shang/China J Orthop Trauma,2018,31(8):751-756. Chinese with abstract in English.
- [6] Bartels RH,Donk R,Verbeek AL,et al. No justification for cervical disk prostheses in clinical practice:a meta-analysis of randomized controlled trials[J]. Neurosurgery,2010,66(6):1153-1160.
- [7] 吴新,黄玮,黄雪花,等.经皮椎间孔镜下颈椎间盘髓核摘除术临床应用[J].新疆医学,2015,45(11):1625-1627.
WU X,HUANG W,HUANG XH,et al. Clinical application of cervical disc nucleus pulpectomy under percutaneous endoscope[J]. Xin Jiang Yi Xue,2015,45(11):1625-1627. Chinese.
- [8] Sim SE,Ko ES,Kim DK,et al. The results of cervical nucleoplasty in patients with cervical disc disorder:a retrospective clinical study of 22 patients[J]. Korean J Pain,2011,24(1):36-43.
- [9] Timmermann J,Hahn M,Krueger K. Short-term followup:micro-invasive therapy of the cervical herniated disk by percutaneous nucleotomy[J]. J Back Musculoskelet Rehabil,2011,24(1):89-93.
- [10] Peng B,Wu W,Hou S,et al. The Pathogenesis of discogenic low back pain[J]. J Bone Joint Surg Br,2005,87(1):62-67.
- [11] Yan DL,Li J,Zhu HD,et al. Percutaneous cervical nucleoplasty and percutaneous cervical discectomy treatments of the contained cervical disc herniation[J]. Arch Orthop Trauma Surg,2010,130(5):1371-1376.
- [12] 赵建华,梁棉,梁梁本,等.经皮穿刺椎间盘摘除术治疗颈椎间盘突出症[J].介入放射学杂志,2003,12(2):140-141.
ZHAO JH,LIANG M,LIANG ZB,et al. Percutaneous discectomy for cervical disc herniation[J]. Jie Ru Fang She Xue Za Zhi,2003,12(2):140-141. Chinese.
- [13] 彭宝淦,杨亮.颈性头晕的发病机制[J].武警医学,2017,28(5):433-436.
PENG BG,YANG L. The pathogenesis of cervical dizziness[J]. Wu Jing Yi Xue,2017,28(5):433-436. Chinese.
- [14] Narsh SK,Siddharth MS,Barry WLT,et al. Discogenic axial back pain:is there a role for nucleoplasty[J]. Asian Spin J,2013,7(4):314-321.
- [15] Yao N,Wang C,Wang W,et al. Full-endoscopic technique for anterior cervical discectomy and interbody fusion:5-year follow-up results of 67 cases[J]. Eur Spine J,2011,20(6):899-904.
- [16] 袁文.关于微创技术在颈椎前路手术中应用的若干思考[J].中国脊柱脊髓杂志,2015,25(6):481-483.
YUAN W. Thinking about the application of minimally invasive technology in anterior cervical spine surgery[J]. Zhongguo Ji Zhu Ji Sui Za Zhi,2015,25(6):481-483. Chinese.

(收稿日期:2020-02-06 本文编辑:王宏)