

## 参考文献

- [1] Macnab I. Negative discs exploration .An analysis of the causes of nerve-root involvement in sixty-eight patients [J]. J Bone Joint Surg Am, 1971, 53(5): 891-903.
- [2] 宋晋刚, 崔易坤, 尹振宇, 等. 不同微创手术方式治疗腰椎间盘突出出症的对比研究 [J]. 生物骨科材料与临床研究, 2018, 15(5): 45-48.  
SONG JG, CUI YK, YIN ZY, et al. Contrastive study of different minimally invasive surgery for lumbar intervertebral disc herniation [J]. Sheng Wu Gu Ke Cai Liao Yu Lin Chuang Yan Jiu, 2018, 15(5): 45-48. Chinese.
- [3] 李振宙, 侯树勋. 经皮内镜腰椎手术学 [M]. 北京: 人民卫生出版社, 2017: 92-93.  
LI ZZ, HOU SX. Percutaneous Endoscopic Lumbar Spine Surgery [M]. Beijing: People's Medical Publishing House, 2017: 92-93. Chinese.
- [4] 焦伟, 张伟, 尹稳, 等. 经皮脊柱内镜下 3 种入路治疗脱垂型腰椎间盘突出出症的比较 [J]. 中国矫形外科杂志, 2018, 26(19): 1758-1764.  
JIAO W, ZHANG W, YIN W, et al. Comparison of the clinical outcomes of percutaneous endoscopic lumbar discectomy through three approaches for migrated disc herniation [J]. Zhongguo Jiao Xing Wai Ke Za Zhi, 2018, 26(19): 1758-1764. Chinese.
- [5] 叶猛, 王力文, 王鸿晨. 椎间孔镜手术出现失误及并发症的原因与预防措施 [J]. 局解手术学杂志, 2017, 26(5): 362-365.  
YE M, WANG LW, WANG HC. Reasons and preventive measures of intraoperative errors and complications of transforaminal endoscopic surgery [J]. Ju Jie Shou Shu Xue Za Zhi, 2017, 26(5): 362-365. Chinese.
- [6] 陈仲强, 刘忠军, 党耕町. 脊柱外科学 [M]. 北京: 人民卫生出版社, 2013: 354.  
CHEN ZQ, LIU ZJ, DANG GD. Spine Surgery [M]. Beijing: People's Medical Publishing House, 2013: 354. Chinese.

(收稿日期: 2020-02-11 本文编辑: 王宏)

## 腰椎术后碎骨块神经压迫症的诊疗及原因分析

顾仕荣, 张明, 陈斌辉, 桑裴铭, 方海名

(宁波市医疗中心李惠利医院骨 2 科, 浙江 宁波 315000)

**【摘要】** 目的: 探讨腰椎术后碎骨块神经压迫症的诊疗、原因及预防。方法: 对 2012 年 2 月至 2019 年 3 月收治的 23 例腰椎术后碎骨块神经压迫症患者进行回顾性分析, 男 9 例, 女 14 例, 年龄 42~81 (62.60±5.70) 岁。手术方式: 腰椎椎间融合术 20 例, 脊柱内镜术 3 例。23 例患者术后均出现减压侧或对侧肢体的放射性疼痛, 发生时间为术后即刻至术后 2 周, 平均 (3.2±1.7) d。所有患者术后复查腰椎 CT 或 MRI 证实残留异位碎骨块, 同时双下肢血管彩超排除血栓形成。异位碎骨块来源: 椎间融合植骨块脱落或开窗融合产生的碎骨块残留 14 例, 断裂的上关节突头部 6 例, 脊柱内镜手术上关节突成形骨块残留 3 例。结果: 患者住院时间 10~37 (23.4±6.2) d。所有患者获得随访, 时间 6~25 (13.6±3.4) 个月。3 例患者术后当天或第 2 天行后路开放神经根探查碎骨块取出术, 术后疼痛症状缓解。20 例患者先行保守治疗, 13 例患者保守治疗后, 疼痛症状缓解后出院。7 例患者保守治疗失败, 其中 2 例保守失败患者期间做过神经根阻滞术。2 例患者行脊柱内镜下神经根探查骨块取出术, 5 例患者行后路开放神经根探查碎骨块取出术, 术后疼痛症状皆缓解。术前 CT、MRI 及术中碎骨块取出骨块形态及位置证实, 碎骨块最大可能来源椎间融合植骨块脱落或开窗融合产生的碎骨块残留 (14 例), 断裂的上关节突头部 (6 例), 脊柱内镜手术上关节突成形骨块残留 (3 例)。末次随访根据 Macnab 标准评价疗效, 结果优 20 例, 良 3 例。结论: 腰椎术后碎骨块神经压迫症采取合适的治疗手段处理, 可获得较好的临床效果, 术中及时取出可能造成残留的碎骨块, 关闭切口前仔细探查神经根, 可避免此类并发症。

**【关键词】** 腰椎; 碎骨块; 手术后并发症; 临床方案

中图分类号: R681.5

DOI: 10.12200/j.issn.1003-0034.2021.04.011

开放科学(资源服务)标识码(OSID):



**Diagnosis, treatment and etiology analysis of nerve compression by bone fragment after lumbar spine surgery** GU Shi-rong, ZHANG Ming, CHEN Bin-hui, SANG Pei-ming, and FANG Hai-ming. The Second Department of Orthopaedics, Lihuli Hospital of Ningbo Medical Center, Ningbo 315000, Zhejiang, China

**ABSTRACT Objective:** To explore the diagnosis, treatment, cause and prevention of nerve compression by bone fragment after lumbar spine surgery. **Methods:** The clinical data of 23 patients with nerve compression by bone fragment after lumbar spine surgery from February 2012 to March 2019 were collected retrospectively, including 9 males and 14 females, aged 42 to 81 years with an average of (62.60±5.70) years. The surgical methods included lumbar interbody fusion in 20 cases and spinal

通讯作者: 张明 E-mail: zmwsh@163.com

Corresponding author: ZHANG Ming E-mail: zmwsh@163.com

endoscopy in 3 cases. All 23 patients experienced radiating pain on the decompression side or the contralateral limb after operation. The time of occurrence was from immediately after operation to 2 weeks after operation, with an average of  $(3.2\pm 1.7)$  days. All patients underwent postoperative examination of lumbar spine CT or MRI to confirm residual ectopic bone fragments, and at the same time, bilateral lower extremity color Doppler ultrasound excluded thrombosis. Sources of ectopic bone fragments: 14 cases of residual bone fragments caused by intervertebral fusion bone graft loss or fenestration fusion, 6 cases of fractured upper articular process head, and 3 cases of upper articular process bone remaining during spinal endoscopic surgery. **Results:** The patient's hospital stay was 10 to 37 ( $23.4\pm 6.2$ ) days. All patients were followed up for 6 to 25 ( $13.6\pm 3.4$ ) months. Three patients underwent posterior open nerve root exploration for removing bone fragments on the same day or the second day after surgery, and the symptoms were relieved. Twenty patients underwent conservative treatment firstly, and 13 patients were discharged after pain relieved by conservative treatment, 7 patients failed conservative treatment, the 2 cases of failed 7 cases had undergone nerve root block surgery during conservative treatment. Two patients underwent spinal endoscopy nerve root exploration and bone mass removal, and five patients underwent posterior open nerve root exploration and bone fragmentation removal. All postoperative pain symptoms were relieved. Preoperative CT, MRI and intraoperative bone fragment removal confirmed the shape and location of the bone fragments. The most likely source of bone fragments was the loss of intervertebral fusion bone grafts or residual bone fragments resulting from fenestration fusion (14 cases), fractured upper articular process head (6 cases), and upper articular process bones remaining in endoscopic surgery (3 cases). According to the Macnab criteria in evaluating clinical outcome, 20 cases got excellent results and 3 good. **Conclusion:** After the lumbar spine surgery, the nerve compression by bone fragments is treated with appropriate treatments, and good clinical results can be obtained. Timely removal of residual bone fragments during operation and careful exploration of nerve roots before closing incision can avoid such complications

**KEYWORDS** Lumbar vertebrae; Bone fragmentation; Postoperative complications; Clinical protocols

近年来,腰椎退行性疾病的诊疗手段越来越多,其中脊柱内镜技术及腰椎融合术在腰椎间盘突出症、腰椎滑脱症及腰椎管狭窄症的运用较为普遍,也有各自独特的优势<sup>[1-3]</sup>,然而相关的神经根损伤,术后椎间盘残留,术后血肿,内固定失败等一系列并发症也较为熟悉<sup>[4-6]</sup>,而腰椎术后产生的碎骨块卡压神经导致相应临床症状的并发症单独报道较少,这类患者症状明显,影响手术的康复,多需要二次翻修,增加住院时间,常常伴发医疗纠纷。笔者回顾性分析 2012 年 2 月至 2019 年 3 月我院该类患者 23 例,对其治疗进行总结并对碎骨块产生原因进行分析,希望给此类并发症的处理及预防提供参考。

## 1 临床资料

本组 23 例,男 9 例,女 14 例,年龄 42~81 ( $62.60\pm 5.70$ )岁。疾病类型:腰椎间盘突出症 12 例,腰椎滑脱 7 例,腰椎管狭窄症 3 例,腰椎滑脱合并邻近节段狭窄症 1 例。手术节段:L<sub>5</sub>S<sub>1</sub> 节段 9 例,L<sub>4,5</sub> 节段 9 例,L<sub>4,5</sub>,L<sub>3,4</sub> 双节段 1 例,L<sub>4,5</sub>,L<sub>5</sub>S<sub>1</sub> 双节段 4 例。手术方式:腰椎椎间融合术 20 例,脊柱内镜术 3 例。23 例患者术后均出现减压侧或对侧肢体的放射性疼痛,发生时间为术后即刻至术后 2 周,平均  $(3.2\pm 1.7)$  d。所有患者术后复查腰椎 CT 或 MRI 证实残留异位碎骨块,同时双下肢血管彩超排除血栓形成。碎骨块的位置及来源:14 例碎骨块位于侧隐窝,压迫走行根,来源考虑椎间融合植骨块脱落或开窗融合手术过程产生的碎骨块残留;6 例碎骨块位于上关节突附近,压迫出口根,来源考虑断裂的上关节突头

部;脊柱内镜手术上关节突成形骨块残留 3 例,碎骨块皆游离高于上关节突,压迫出口根。

## 2 治疗方法

13 例患者单纯保守治疗:急性期给予糖皮质激素(每天 1 次甲基强龙 80 mg 静脉滴注),甘露醇减轻神经水肿,甲钴胺营养神经,阶梯式给予非甾体止痛药,加巴喷汀或普瑞巴林,盐酸曲马多口服治疗直至疼痛控制。

再次手术治疗 10 例:2 例患者行脊柱内镜下神经根探查骨块取出术;8 例患者行后路开放神经根探查碎骨块取出术,其中 2 例保守治疗失败再手术患者保守期间行神经根封闭阻滞术(利多卡因+复方倍他米松)。

再手术患者术后处理:术后常规静脉滴注抗生素 12 h,给予糖皮质激素治疗 2~3 d,甲钴胺营养神经,视疼痛程度阶梯式给予口服非甾体止痛药,加巴喷汀或普瑞巴林,盐酸曲马多口服治疗至疼痛控制。

## 3 结果

所有患者获得随访,时间 6~25( $13.6\pm 3.4$ )个月。住院时间 10~37( $23.4\pm 6.2$ ) d。3 例患者术后麻醉醒后患侧下肢放射状疼痛症状较术前严重,术后当即 CT 证实异位碎骨块卡压神经根,术后当天或第 2 天行后路开放神经根探查碎骨块取出术,术后疼痛症状缓解。12 例患者术后麻醉清醒后患侧下肢疼痛症状较术前好转,但仍存在放射性疼痛。5 例患者术后症状好转,术后活动后再次逐渐出现患肢放射性疼痛,3 例患者术后拔管后无症状患肢逐渐出现放

射性疼痛。患者术后 CT 或 MRI 证实异位碎骨块卡压神经根,该 20 例患者先行保守治疗,13 例患者保守治疗后,疼痛症状缓解后出院;7 例患者保守治疗失败,其中 2 例在保守治疗期间做过神经根阻滞术,术后症状缓解消失,术后 1~2 d 症状再次出现同术前。7 例患者至再手术保守治疗时间 4~26 (10.5±2.8) d,2 例患者行脊柱内镜下神经根探查骨块取出术,5 例患者行后路切开神经根探查碎骨块取出术,术后疼痛症状皆缓解。

术前 CT、MRI 及术中碎骨块取出骨块形态及位置证实,碎骨块最大可能来源椎间融合植骨块脱落或开窗融合手术过程产生的碎骨块残留 14 例,断裂的上关节突头部 6 例,脊柱内镜手术上关节突成形骨块残留 3 例。23 例患者异位骨块来源情况见表 1。

术后 6 个月采用视觉模拟评分法 (visual analogue scale, VAS) 对疼痛进行评分,结果见表 1。末次随访根据 Macnab<sup>[7]</sup> 标准对疗效进行评定,结果优

20 例,良 3 例。典型病例见图 1,2。

#### 4 讨论

##### 4.1 症状性异位碎骨块的治疗及再次手术的时机

治疗腰椎术后碎骨块神经压迫症首先排除术中神经根牵拉、血肿等刺激症状,术后及时行 CT 或者 MRI 证实是否有碎骨块卡压神经根,明确病因。根据碎骨块来源发现,椎间融合植骨块脱落或开窗融合产生的碎骨块残留大部分可以保守治疗,术前 CT 或 MRI 及术中证实此类碎骨块较小,大小约 2 mm×2 mm×3 mm,往往卡压移行根,神经根刺激症状卧床时大部分可忍受,但下床活动时症状加重明显。是否保守治疗主要跟碎骨块位置相关,4 例保守失败手术患者症状早期轻,保守治疗后逐渐加重,2 例患者出现足背伸肌力下降,碎骨块处于侧隐窝内,3 例处于神经根内外侧,1 例位于内下侧。主要考虑碎骨块随着活动移位至侧隐窝狭窄处造成神经根卡压。该类碎骨块来源患者前期给予糖皮质激素治疗 2~3 d,

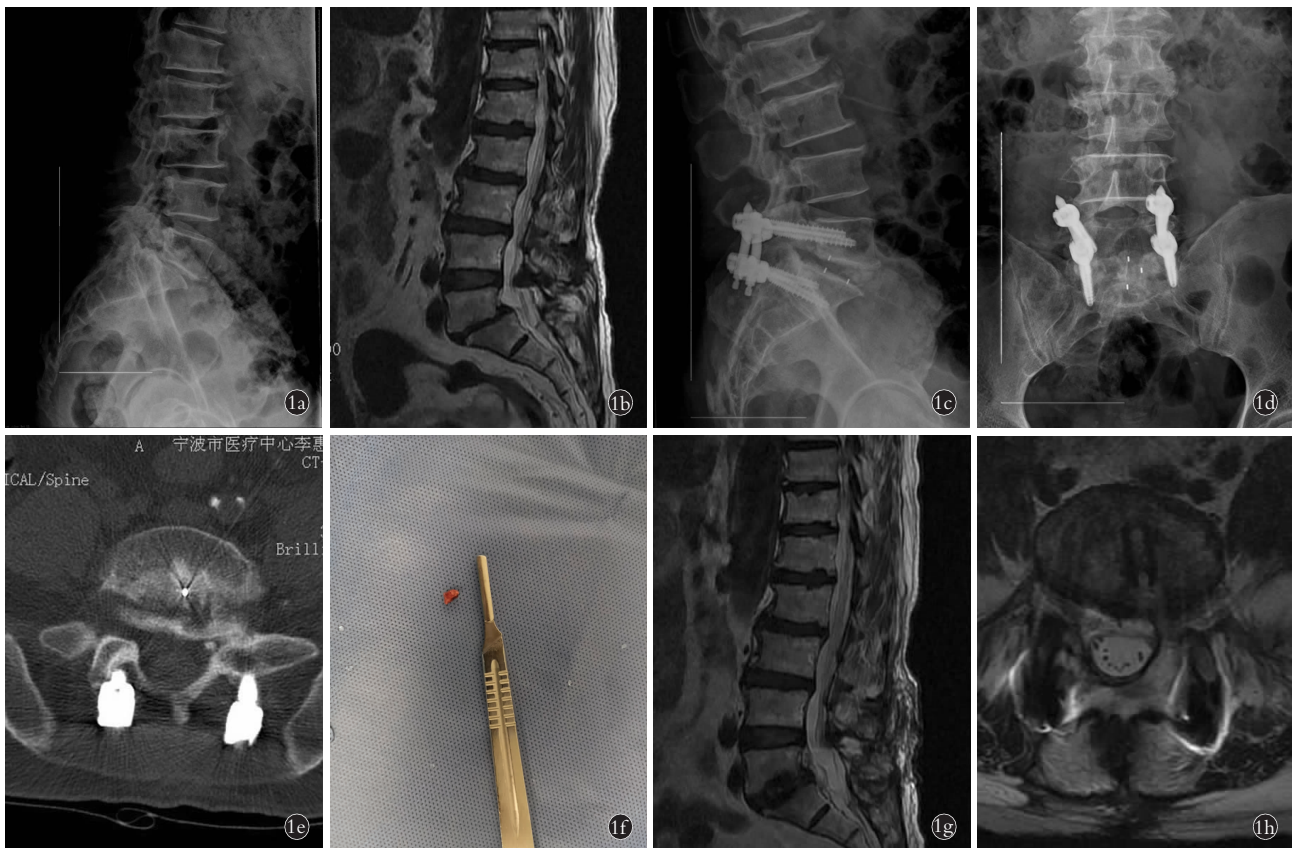

图 1 男性患者,81 岁,因右下肢间歇性跛行 1 年入院,诊断为 L<sub>5</sub> 椎体滑脱症 1a,1b。术前 DR 侧位片及 MRI 矢状面提示患者 L<sub>5</sub> 椎体滑脱 1c,1d。腰椎融合术后第 1 天 DR 正侧位片 1e。术后第 2 天 CT 轴状面示左侧侧隐窝深部碎骨块 1f。术后 2 周行第 2 次手术术中取出碎骨块 1g,1h。二次手术术后第 2 天复查 MRI 矢状面及轴状面示脊髓及神经根无受压

Fig.1 A 81-year-old male patient was admitted to hospital because of intermittent claudication of the right lower limb for 1 year and was diagnosed with spondylolisthesis of L<sub>5</sub> 1a,1b. Preoperative DR lateral radiograph and sagittal MRI showed spondylolisthesis of L<sub>5</sub> vertebral body 1c,1d. DR positive and lateral radiographs on the first day after surgery 1e. On the second day after operation, the axial plane of CT showed bone fragments in the left side recess 1f. Bone fragments were removed during the second operation 2 weeks after surgery 1g,1h. On the second day after the second operation, sagittal and axial MRI showed no compression of the spinal cord and nerve roots



表 1 腰椎术后碎骨块神经压迫症 23 例患者异位骨块来源和治疗方法及治疗前后 VAS 评分

Tab.1 Ectopic bone mass source, treatment method, pre- and post-treatment VAS in 23 patients with nerve compression by bone fragment after lumbar spine surgery

碎骨块来源	例数	治疗方法(例)		VAS 评分(x±s,分)	
		保守	手术	治疗前	治疗后 6 个月
椎间融合植骨块脱落或开窗融合产生	14	10	4	5.5±1.3	2.6±0.7*
碎骨块残留断裂的上关节突头部	6	2	4	7.3±1.8	1.9±1.3**
脊柱内镜手术上的上关节突头部关节突成形骨块残留	3	1	2	8.2±0.8	2.3±1.3***

注:与治疗前比较,\*t=10.173,P=0.000;\*\*t=12.589,P=0.000;\*\*\*t=16.452,P=0.000

Note:Compared with preoperative data,\*t=10.173,P=0.000;\*\*t=12.589,P=0.000;\*\*\*t=16.452,P=0.000

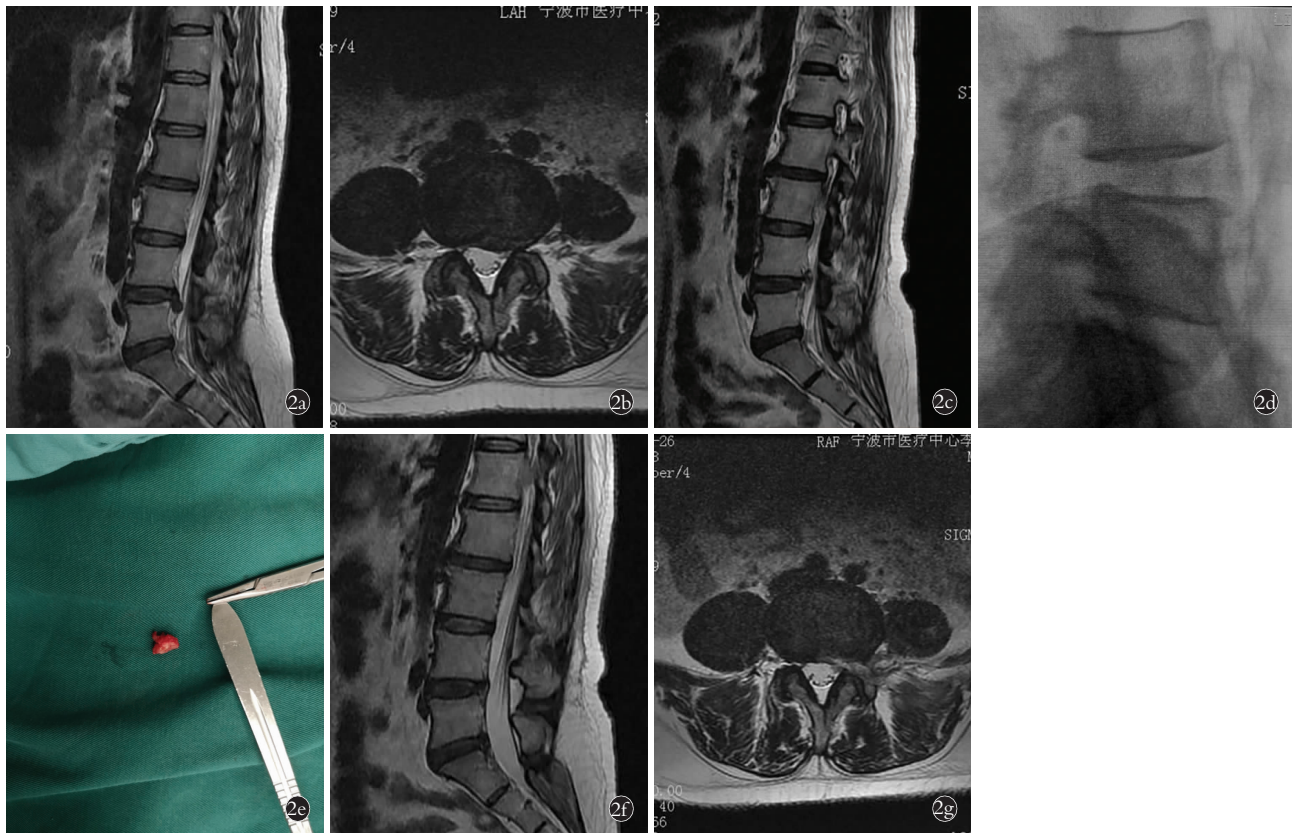


图 2 女性患者,43 岁,因右侧腰腿痛 1 周入院,诊断为腰椎间盘突出症 2a,2b. 术前 MRI 矢状面及轴状面提示 L<sub>4,5</sub> 椎间盘游离向下脱出 2c. 脊柱内镜术后第 2 天复查 MRI 矢状面提示 L<sub>4,5</sub> 右侧椎间盘上缘骨块 2d. 术后第 3 天二次手术透视 L<sub>4</sub> 椎弓根下缘骨块 2e. 二次手术术中取出碎骨块 2f,2g. 二次手术术后第 2 天复查 MRI 矢状面及轴状面示脊髓及神经根无受压

Fig.2 A 43-year-old female patient was admitted to hospital because of right lower back and leg pain for 1 week and was diagnosed with lumbar disc herniation 2a,2b. Preoperative MRI by sagittal plane and axial plane suggested isolation and downward prolapse of L<sub>4,5</sub> intervertebral disc 2c. On the second day after spine endoscopy,sagittal MRI showed bone mass on the upper edge of the right intervertebral disc on L<sub>4,5</sub> 2d. On the third day after surgery,intraoperative fluoroscopy revealed bone mass at the lower edge of L<sub>4</sub> pedicle 2e. Removal of bone fragments during the second operation 2f,2g. On the second day after second operation,sagittal and axial MRI showed no compression of the spinal cord and nerve roots

甲钴胺营养神经,视疼痛程度阶梯式给予口服非甾体止痛药,加巴喷汀或普瑞巴林,盐酸曲马多口服治疗,往往能获得较好的控制。当患者出现肌力下降,保守 1~2 个月药物控制不理想影响生活,碎骨块位置不佳处于侧隐窝深部神经根卡压较重,患者情绪较多不愿服药控制等情况则考虑积极手术治疗。术

前仔细分析碎骨块位置,位于侧隐窝深部脊柱内镜手术有手术盲区,不易发现及取出碎骨块,谨慎选择。3 例患者选择开放开窗减压神经根探测,该类患者神经根紧张,打开侧隐窝时最好选用磨钻,避免使用咬骨钳造成二次损伤。断裂的上关节突头部往往卡压出口根,症状往往不重,也是活动时加重,影响

日常活动。但该类卡压骨块较大,保守较难好转。与患者沟通后往往选择再次手术。手术方式根据骨块大小、位置,脊柱内镜及开放根据术者的技术及患者经济可承受能力,以及可能纠纷情况。脊柱内镜手术上关节突成形骨块残留骨块较大,环锯一次成形骨块未取出 2 例,多次成形少量骨块未取出 1 例。2 例手术患者取出骨块大小 5 mm×3 mm×2mm 及 4 mm×2 mm×3 mm,不规则,患者症状明显,逐渐加重,皆出现足背伸肌力下降,行积极开放手术,确保碎骨块安全完整取出。2 例患者保守期间采用神经根阻滞术,术后 1~2 d 皆复发,后期再次手术患者情绪较大,多次进手术室易产生医疗纠纷,尽量选用最可靠最有效的治疗手段彻底解决,患者往往有较好的恢复。

#### 4.2 异位碎骨块的来源及预防

Lee 等<sup>[8]</sup>报道椎间融合内固定手术中,椎管内碎骨块的卡压形成神经刺激症状,其中 14 例患者由于椎间融合植骨块脱落或开窗融合产生的碎骨块残留。笔者分析主要来源于开窗减压时对上关节突咬除骨块未及时取出;手术皆采用自体骨回植,椎间时骨粒较多未全部塞进椎间有部分掉落在神经根侧隐窝附近;融合器植入时融合器内部的碎骨块脱落掉入神经根附近;后期椎间隙植骨块的脱离或切口内游离碎骨块的走动,所以该类患者植骨时植入椎间前方深部,并用合适大小的融合器封住开口,在关闭切口前进行切口冲洗,并对神经根做探查,特别是侧隐窝内神经根探查后再关闭切口,可有效避免该类碎骨块的产生。上关节突头部附近骨块卡压 6 例,其中腰椎滑脱患者 4 例,主要考虑腰椎滑脱复位后上位神经根的探查不彻底,2 例患者考虑骨凿打断的上关节突尖部未取出,术中需完整避免骨块残留。脊柱内镜手术上关节突成形骨块残留 3 例,Choi 等<sup>[9]</sup>报道脊柱内镜成形属于盲区操作,或多或少会产生椎管内骨质残留。该类患者主要选用环锯成形,一次成形残留骨块较大,症状较重,往往需要再次手术,多次成形残留骨块稍小,但容易残留。赵刘军等<sup>[10]</sup>报道椎间孔成形不理想,成形管道角度改变及患者年龄骨质情况也是重要原因。选用合适的骨锉可减少此类骨块,同时需要术者熟练的脊柱内镜技术、合适

的成形角度及成形骨量。

腰椎术后碎骨块神经压迫症影响患者的康复,再次手术及较长的住院时间,容易造成医疗纠纷。采取合适的手段处理该类并发症,可获得较好的临床效果,术中及时取出可能造成残留的碎骨块,关闭切口前仔细探查神经根,可避免此类并发症。

#### 参考文献

- [1] Sinkemani A, Hong X, Gao ZX, et al. Outcomes of microendoscopic discectomy and percutaneous transforaminal endoscopic discectomy for the treatment of lumbar disc herniation: a comparative retrospective study[J]. *Asian Spine J*, 2015, 9(6): 833-840.
  - [2] Nellensteijn J, Ostelo R, Banelis R, et al. Transforaminal endoscopic surgery for symptomatic lumbar disc herniations: a systematic review of the literature[J]. *Eur Spine J*, 2010, 19(2): 181-204.
  - [3] Lonstein JE, Denis F, Perra JH, et al. Complications associated with pedicle screws[J]. *Bone Joint Surg Am*, 1999, 81(11): 1519-1528.
  - [4] Sairyo K, Matsuura T, Higashino K, et al. Surgery related complications in percutaneous endoscopic lumbar discectomy under local anesthesia[J]. *J Med Invest*, 2014, 61(34): 264-269.
  - [5] Gadraj PS, van Tulder MW, Dirven CM, et al. Clinical outcomes after percutaneous transforaminal endoscopic discectomy for lumbar disc herniation: a prospective case series[J]. *Neurosurg Focus*, 2016, 40(2): E3.
  - [6] Hsu CJ, Chou WY, Chang WN, et al. Clinical follow up after instrumentation-augmented lumbar spinal surgery in patients with unsatisfactory outcomes[J]. *J Neurosurg Spine*, 2006, 5(4): 281-286.
  - [7] Macnab I. Negative disc exploration. An analysis of the causes of nerve root involvement in sixty-eight patients[J]. *J Bone Joint Surg Am*, 1971, 53(5): 891-903.
  - [8] Lee BH, Hyun SJ, Kim KJ, et al. Clinical and radiological outcomes of posterior vertebral column resection for severe spinal deformities[J]. *J Korean Neurosurg Soc*, 2018, 61(2): 251-257.
  - [9] Choi G, Lee SH, Lokhande P, et al. Percutaneous endoscopic approach for highly migrated intracanal disc herniations by foramino-plastic technique using rigid working channel endoscope[J]. *Spine (Phila Pa 1976)*, 2008, 33(15): E508-E515.
  - [10] 赵刘军, 张吉辉, 徐宝山, 等. 经皮内镜术后症状性关节突关节骨块残留的多中心回顾性研究[J]. *中华骨科杂志*, 2018, 38(19): 1186-1194.
- ZHAO LJ, ZHANG JH, XU BS, et al. A multicenter retrospective clinical study on "symptomatic facet of residual bone mass", a rare complication of percutaneous transforaminal endoscopic discectomy[J]. *Zhonghua Gu Ke Za Zhi*, 2018, 38(19): 1186-1194. Chinese.

(收稿日期:2020-06-19 本文编辑:王宏)