

# 肌间隙入路通道下固定融合治疗复发性腰椎间盘突出症

曾忠友<sup>1</sup>, 张建乔<sup>1</sup>, 毛克亚<sup>2</sup>, 宋永兴<sup>1</sup>, 范时洋<sup>1</sup>, 俞伟<sup>1</sup>, 裴斐<sup>1</sup>, 王海峰<sup>1</sup>

(1. 武警部队骨科中心 武警海警总队医院骨二科, 浙江 嘉兴 314000; 2. 解放军总医院骨科, 北京 100853)

**【摘要】** 目的: 探讨肌间隙入路通道下单侧椎弓根螺钉联合对侧椎板关节突螺钉固定并椎间融合器植骨治疗复发性腰椎间盘突出的临床价值和安全性。方法: 回顾性分析 2012 年 6 月至 2017 年 12 月收治的 51 例复发性腰椎间盘突出的临床资料。男 32 例, 女 19 例; 年龄 34~64(51.11±7.28) 岁; L<sub>4,5</sub> 38 例, L<sub>5</sub>S<sub>1</sub> 13 例; 均有腰痛病史, 其中 3 例伴双下肢放射痛, 48 例伴一侧下肢放射痛。24 例患者采用正中切口入路单侧椎弓根螺钉联合对侧椎板关节突螺钉固定并椎间融合器植骨治疗(正中切口组), 27 例采用肌间隙入路通道下单侧椎弓根螺钉联合对侧椎板关节突螺钉固定并椎间融合器植骨治疗(肌间隙组)。记录两组患者手术时间、术中出血量、术后引流量和切口长度; 采用视觉模拟评分法(visual analogue scale, VAS)对术后 72 h 腰部切口疼痛进行评分, 采用 JOA 下腰痛评分系统评定术前及末次随访时两组患者腰椎功能; 通过影像学资料观察术前、术后 3~5 d 和末次随访时病变节段椎间隙高度的变化, 术前和末次随访时腰椎冠状面和矢状面 Cobb 角变化, 术前和术后 12 个月多裂肌面积和多裂肌脂肪组织沉积等级, 术后椎弓根螺钉和椎板关节突螺钉位置, 以及椎间融合情况; 比较两组患者并发症发生情况。**结果:** 两组患者手术时间比较差异无统计学意义( $P>0.05$ )。肌间隙组在切口长度、术中出血量和术后引流量方面优于正中切口组( $P<0.05$ )。术后 72 h 腰部切口疼痛 VAS 评分正中切口组 1.61±0.54, 肌间隙组 0.76±0.28, 两组比较差异有统计学意义( $P<0.05$ )。所有患者获得随访, 时间 12~84(43.50±15.84) 个月。末次随访时两组 JOA 评分均较术前明显改善( $P<0.05$ )。椎弓根螺钉位置不良率: 正中切口组 6.25%(3/48), 肌间隙组 9.26%(5/54), 两组差异无统计学意义( $P>0.05$ )。椎板关节突螺钉位置不良率: 正中切口组 12.50%(3/24), 肌间隙组 18.52%(5/27), 两组差异有统计学意义( $P<0.05$ )。两组患者术后 3~5 d 椎间隙高度较术前均有明显恢复( $P<0.05$ ), 而在末次随访时亦有较明显的丢失( $P<0.05$ )。末次随访时两组患者冠状面和矢状面平衡获得了很好的改善( $P<0.05$ )。两组术后 12 个月多裂肌面积和等级的对比显示: 正中切口显露对多裂肌损害明显, 而采用肌间隙入路通道下操作多裂肌损害较轻( $P<0.05$ )。椎间融合率: 正中切口组 91.7%(22/24), 肌间隙组 92.6%(25/27), 两组差异无统计学意义( $P>0.05$ )。并发症方面: 正中切口组术中椎弓根入点骨折 1 例, 术中硬脊膜撕裂 1 例, 术后神经根损伤 1 例; 肌间隙组术中椎弓根入点骨折 1 例, 术中硬脊膜撕裂 2 例, 术后神经根损伤 1 例, 切口表皮坏死 2 例, 切口愈合不良 1 例。两组神经根损伤均为椎弓根螺钉位置不正确所致, 发现后即予螺钉调整术, 神经根症状分别于术后 3、6 个月完全恢复。两组均未发生切口感染, 随访过程中无椎弓根螺钉与椎板关节突螺钉松动、移位、断裂或椎间融合器前后向移位。并发症发生率肌间隙组 25.93% 高于正中切口组的 12.50% ( $P<0.05$ )。**结论:** 采用肌间隙入路通道下单侧椎弓根螺钉联合对侧椎板关节突螺钉固定并椎间融合治疗复发性腰椎间盘突出症临床上具有可行性, 而且效果良好, 与正中切口显露相比, 明显缩小了切口、减少了创伤和出血量, 术后反应轻、恢复快, 较好地保护了多裂肌, 同时无严重并发症的发生, 值得临床上选择应用。

**【关键词】** 腰椎间盘突出症; 复发; 脊柱融合术

中图分类号: R681.4

DOI: 10.12200/j.issn.1003-0034.2021.04.003

开放科学(资源服务)标识码(OSID):



**Channel-assisted fixation and interbody fusion in treating recurrent lumbar disc herniation by muscle-splitting approach** ZENG Zhong-you\*, ZHANG Jian-qiao, MAO Ke-ya, SONG Yong-xing, FAN Shi-yang, YU Wei, PEI Fei, and WANG Hai-feng. \*The Second Department of Orthopaedics, Hospital of Coast Guard General Corps of Armed Police Forces, Jiaxing 314000, Zhejiang, China

**ABSTRACT Objective:** To explore the clinical value and safety of unilateral pedicle screw fixation combined with contralateral translaminar facet screw fixation and interbody fusion by muscle-splitting approach treatment of recurrent lumbar disc herniation. **Methods:** The clinical data of 51 patients with recurrent lumbar disc herniation treated from June 2012 to December 2017 were retrospectively analyzed. There were 32 males and 19 females, aged 34 to 64 years with an average of (51.11±

通讯作者: 曾忠友 E-mail: zjzengzy@126.com

Corresponding author: ZENG Zhong-you E-mail: zjzengzy@126.com

7.28) years. Lesions involved L<sub>4,5</sub> in 38 cases and L<sub>5</sub>S<sub>1</sub> in 13 cases. All patients had a history of lower back pain and radiation pain of lower limbs (3 bilateral and 48 unilateral) and underwent unilateral pedicle screw combined with contralateral translaminar facet screw fixation and interbody fusion, among which 24 patients were treated through median incision approach (median incision group); other 27 patients were treated through muscle-splitting approach with channel-assisted exposure (muscle-splitting approach group). Operation time, intraoperative blood loss, postoperative drainage and incision length of the two groups were recorded. Visual analogue scale (VAS) was used to score the pain of lumbar incision at 72 h after operation, and JOA low back pain scoring system was used to evaluate the lumbar function preoperatively and at final follow-up. Imaging data were analyzed, including the changes in the height of intervertebral space of diseased segment before operation, 3 to 5 days after operation, and at final follow-up; Cobb angle changes in the coronal and sagittal planes of lumbar spine preoperatively and at final follow-up; multifidus area and multifidus fatty tissue deposition grade before and 12 months after operation; postoperative pedicle screw and laminar process screw position and intervertebral fusion condition. The complications of the two groups were compared. **Results:** There was no statistical difference in operation time between two groups ( $P>0.05$ ). Muscle-splitting approach group was better than median incision group in light of incision length, intraoperative blood loss and postoperative drainage volume ( $P<0.05$ ). VAS score of lumbar incision pain at 72 h after operation was  $1.61\pm 0.54$  in median incision group and  $0.76\pm 0.28$  in muscle-splitting approach group ( $P<0.05$ ). All patients were followed up for 12 to 84 ( $43.50\pm 15.84$ ) months. At final follow-up, the JOA scores of the two groups were significantly improved compared with those before operation ( $P<0.05$ ). The rate of pedicle screw malposition was 6.25% (3/48) in median incision group and 9.26% (5/54) in muscle-splitting approach group, there was no statistically significant difference between two groups ( $P>0.05$ ). Rate of translaminar facet screw malposition in median incision group (12.50%) was significant less than the muscle-splitting approach group (18.52%) ( $P<0.05$ ). The height of the intervertebral space of the two groups was significantly restored 3 to 5 days after operation ( $P<0.05$ ), and there was also a significant loss of height at final follow-up ( $P<0.05$ ). At final follow-up, the balance of lumbar coronal plane and sagittal plane in two groups were improved very well ( $P<0.05$ ). The comparison of the area and grade of the multifidus muscle in two groups 12 months after operation showed that obvious damage to the multifidus muscle were present in the median incision, while the multifidus muscle was less damaged by muscle-splitting approach ( $P<0.05$ ). The fusion rate was 91.7% (22/24) in the median incision group and 92.6% (25/27) in muscle-splitting approach group ( $P>0.05$ ). In median incision group, there were 1 case of intraoperative pedicle entry point fracture, 1 case of intraoperative dural tear and 1 case of postoperative nerve root injury; in muscle-splitting approach group, there were 1 case of intraoperative pedicle entry point fracture, 2 cases of intraoperative dural tear, 1 case of postoperative nerve root injury, 2 cases of incision epidermal necrosis and 1 case of poor incision healing. Nerve root injuries in the two groups were caused by incorrect positions of pedicle screws, the screws were immediately adjusted upon discovery. The nerve root symptoms were completely recovered 3 and 6 months after surgery. No incision infection was occurred in two groups. During the follow-up, no pedicle screw and laminar facet screw were loosened, displaced, broken, or intervertebral fusion cage moved forward and backward. The complication rate of 25.93% in muscle-splitting approach group was higher than 12.50% in the median incision group ( $P<0.05$ ). **Conclusion:** Muscle-splitting approach is feasible for the treatment of recurrent lumbar disc herniation with pedicle screw fixation combined with contralateral translaminar facet screw fixation and interbody fusion. Compared with the median incision approach, the muscle-splitting approach has the advantages of small incision, less trauma, less bleeding, rapid recovery. Also it can protect multifidus and do not increase the incidence of serious complications. Thus, it can be used as a choice for fixation and fusion of recurrent lumbar disc herniation.

**KEYWORDS** Lumbar disc herniation; Recurrent; Spinal fusion

无论是采用开放或微创入路,髓核摘除术仍然是腰椎间盘突出症初次手术的主要方式<sup>[1-5]</sup>,具有技术成熟、操作简便、创伤小、效果确切等优点。然而,术后椎间盘复发是髓核摘除术不可避免且较为常见的并发症<sup>[1-5]</sup>。对于复发性腰椎间盘突出症,如经保守治疗无效或伴有持续性神经损害,多建议手术治疗。复发性腰椎间盘突出症的手术方式多样<sup>[5-9]</sup>,固定融合是效果最为确切的方式之一<sup>[5,7-8]</sup>。在腰椎的固定融合治疗中,单侧椎弓根螺钉联合对侧椎板关节突螺钉固定并椎间融合器植骨作为一种独立而有效的技术近年来出现较多的应用报道<sup>[10-16]</sup>,但以往

多采用正中切口骶棘肌剥离显露的方式,自学者们<sup>[17-19]</sup>将通道技术引进腰椎后路手术以来,已有肌间隙入路通道下单侧椎弓根螺钉联合对侧椎板关节突螺钉固定并椎间融合的报道<sup>[20-24]</sup>,包括笔者的应用<sup>[21-24]</sup>。由于大部分复发性腰椎间盘突出症病例既往经过开放切口髓核摘除手术,骶棘肌存在一定损害,且局部多有瘢痕组织增生,以及硬脊膜、神经根与周围组织的粘连,肌间隙入路通道下进行椎管减压、髓核摘除、椎间融合器植入是否具有可行性,临床意义如何?特别是对于已经遭受损害的骶棘肌是否具有保护作用?与正中切口入路相比有何优势?

本文回顾性分析 2012 年 6 月至 2017 年 12 月分别采用正中切口入路和肌间隙入路通道下单侧椎弓根螺钉联合对侧椎板关节突螺钉固定并椎间融合器植骨治疗的 51 例复发性腰椎间盘突出症,报告如下。

### 1 资料与方法

#### 1.1 病例选择

**1.1.1 入选标准** 腰椎间盘突出症术后原位复发;腰椎间盘突出症初次手术采用了开放切口椎板间开窗髓核摘除的方式;单节段病变;合并马尾神经损伤或神经根损伤进行性加重者需及时手术外,其余病例均经保守治疗 3 个月或以上效果不佳;获得 1 年或以上时间随访,且资料完整。

**1.1.2 排除标准** 腰椎局部严重的三维畸形;腰椎存在骨质疏松;椎弓根或椎板关节突发育不良;体重指数(Body Mass Index, BMI)>25 kg/m<sup>2</sup>;合并严重基础病变,无法耐受手术者。

#### 1.2 一般资料

本组 51 例,男 32 例,女 19 例;年龄 34~64 (51.11±7.28)岁;病史(7.85±2.36)个月;L<sub>4,5</sub> 38 例, L<sub>5</sub>S<sub>1</sub> 13 例;均有腰痛病史,其中 3 例伴双下肢放射痛,48 例伴一侧下肢放射痛。根据上述入选和排除标准,入选正中切口入路单侧椎弓根螺钉联合对侧椎板关节突螺钉固定并椎间融合器植骨治疗组(正中切口组)24 例,肌间隙入路通道下单侧椎弓根螺钉联合对侧椎板关节突螺钉固定并椎间融合器植骨治疗组(肌间隙组)27 例。两组患者一般资料见表 1。术前根据腰椎 CT 及腰椎正侧位 X 线片测量拟固定节段椎板关节突钉道长度、椎板厚度、椎板外斜角、椎板下倾角等参数<sup>[25]</sup>作为术中操作参考。

#### 1.3 治疗方法

患者均采用全麻,取俯卧位,保持腹部悬空。手术均由同一组医生完成,所用通道为 Mispine 系统,钉棒系统为钛合金产品,椎板关节突螺钉为钛合金空心结构;解剖型 Peek 材料融合器 23 例,香蕉型 Peek 材料融合器 28 例。人工骨为磷酸钙颗粒型,异种异体骨为干燥小牛骨。

**1.3.1 正中切口组手术步骤** 以病变节段为中心

经棘突做腰部正中纵行切口(或按原手术切口进入),逐层切开,沿棘突及椎板表面剥离一侧(有神经症状侧或病变严重侧)骶棘肌,使用自行设计的组配型横突拉钩<sup>[26]</sup>(专利号:ZL 2013 2 0442436.7)牵开骶棘肌。首先于病变节段上下椎体经椎弓根置入定位针,然后经标准 TLIF 入路行椎管减压、髓核摘除、椎间隙融合器床的制作、椎间隙深部植骨和融合器植入。融合器内植骨为自体骨,自体骨来源为关节突切除和椎管减压所获骨质(肌间隙组与此相同);椎间隙深部植骨中 2 例为自体骨,6 例为人工骨和自体骨混合,5 例为异种异体骨和自体骨混合,11 例为同种异体骨和自体骨混合。然后在自行设计的瞄准器<sup>[26]</sup>(专利号 ZL 2009 2 0120264.5)引导下对侧置入椎板关节突螺钉,具体操作方法已有多篇文章报道<sup>[27-29]</sup>,此处不具体描述。最后置入椎弓根螺钉,装棒并适当进行椎间压缩。切口彻底止血、大量生理盐水冲洗、逐层缝合。切口放置 1 根引流管。

**1.3.2 肌间隙组手术步骤** 以病变节段为中心,旁开棘突 2~3 cm(有神经症状侧或病变严重侧)做腰部纵行切口,锐性切开腰背筋膜,寻找并确定多裂肌,于多裂肌肌纤维之间用手指作钝性分离直达椎板和关节突表面,插入扩张套管,逐级扩张,置入带光源的通道并纵向撑开,同时使其底部呈喇叭状张口,将通道保持外倾并头倾方向固定。清除椎板、关节突表面残余软组织,充分显露椎板间隙及关节突关节,经 C 形臂 X 线机透视确定病变节段无误后,余下操作同正中切口组。融合器内植骨为自体骨,椎间隙深部植骨中 3 例为自体骨,6 例为人工骨和自体骨混合,6 例为异种异体骨和自体骨混合,12 例为同种异体骨和自体骨混合。

**1.3.3 术后处理** 术后常规预防性抗感染、小剂量激素、保护胃粘膜并卧床休息等处理。麻醉苏醒后即嘱患者主动进行双下肢踝关节背伸运动及被动进行双下肢直腿抬高运动。切口置放引流管的病例,其引流管根据引流量(24 h 引流量<50 ml)于术后 24~72 h 拔除。术后 1~4 d 佩带腰围下床活动,6 周后渐进性腰背肌、腹肌锻炼。

表 1 两组复发性腰椎间盘突出症患者术前一般资料比较

Tab.1 Comparison of preoperative general data of patients with recurrent lumbar disc herniation between two groups

组别	例数	性别(例)		年龄(x±s,岁)	病史(x±s,月)	病变部位(例)	
		男	女			L <sub>4,5</sub>	L <sub>5</sub> S <sub>1</sub>
正中切口组	24	15	9	52.20±7.01	8.20±3.51	18	6
肌间隙组	27	17	10	50.20±7.46	7.50±2.92	20	7
检验值		F=0.157		t=1.126	t=1.153	F=1.350	
P 值		0.275		0.638	0.514	0.661	

1.4 观察项目与方法

1.4.1 一般情况 观察两组患者切口长度、手术时间、术中出血量和术后引流量。

1.4.2 影像学观察 于术后 3~5 d、3 个月、6 个月、12 个月,随后每隔 12 个月行腰椎正侧位 X 线检查,术后 12 个月行腰椎过屈过伸位 X 线检查;术后 3~5 d 行腰椎 CT 平扫,术后 12 个月行腰椎 CT 平扫并矢状面、冠状面重建;43 例(其中正中切口组 21 例,肌间隙组 23 例)于术后 12 个月行腰椎 MRI 检查。

根据影像学检查比较手术前后病变节段椎间隙高度(病变节段椎间隙前缘高度和后缘高度的平均值)、腰椎冠状面及矢状面 Cobb 角(L<sub>1</sub> 椎体上终板平行线垂线与 S<sub>1</sub> 上终板平行线垂线的夹角)的变化,测量手术前后多裂肌面积和多裂肌脂肪组织沉积等级。多裂肌面积利用医疗工作站所安装的宁波明天医学影像系统不规则面积测量模块线上直接测量。多裂肌脂肪组织沉积采用 Goutallier 等<sup>[30]</sup>提出的等级标准:1 级,正常肌肉;2 级,脂肪组织散在分布于肌纤维间;3 级,脂肪组织与肌肉组织所占比例大致相等;4 级,脂肪组织占比超过肌肉组织。

同时观察椎弓根螺钉和椎板关节突螺钉位置、椎间融合情况,检查椎弓根螺钉和椎板关节突螺钉有无松动、断裂,以及椎间融合器有无前后向移位。(1)椎弓根螺钉位置评价按 Xu 等<sup>[31]</sup>提出的标准分为:I 度,螺钉位于椎弓根内;II 度,不超过螺钉直径的 50%部分穿透椎弓根;III 度,超过螺钉直径的 50%穿出椎弓根,其中 II 度和 III 度为螺钉位置不良。(2)椎板关节突螺钉位置评价分为<sup>[25]</sup>:I 型,螺钉位于椎板骨质内;II 型,螺钉部分穿透椎板;III 型,螺钉完全穿透椎板(表现为螺钉位于椎板表面或完全进入椎管),其中 II 型和 III 型为螺钉位置不良。(3)椎间融合评价标准:①椎间融合器无移位,融合器内无透亮线;②椎间融合器前方有骨小梁通过;③融合器与椎体终板间无透亮线并有骨小梁通过;④过屈过伸位 X 线片提示融合节段椎体无相对移位及终板角度变化小于 5°。其中符合①②④或者①③④认为椎间融合良好。

1.4.3 临床效果 于术后 72 h 采用视觉模拟评分法(visual analogue scale, VAS)<sup>[32]</sup>对腰部切口疼痛进行评分。术前、末次随访采用日本骨科学会(Japanese Orthopaedic Association, JOA)下腰痛评分系统(29 分法)<sup>[33]</sup>,对患者症状、体征、日常活动及膀胱功能进行评价。

1.4.4 并发症情况 观察术中椎弓根骨折或硬脊膜损伤、术中或术后马尾神经或神经根损伤,以及脑脊液漏等,术后切口感染或切口皮肤坏死、切口愈合不良,比较两组并发症发生率。

1.5 统计学处理

应用 SPSS 20.0 统计软件进行数据处理,两组患者的性别、病变部位、融合率、螺钉位置不良率等资料的比较采用卡方检验或 Fisher 精确概率计算法;两组病例的年龄、病史时间、切口长度、手术时间、术中出血量、术后引流量、VAS 评分、椎间隙高度、腰椎冠状面和矢状面 Cobb 角、多裂肌面积和 JOA 评分的比较采用独立样本 *t* 检验;同组病例术前、术后和末次随访时定量参数比较采用配对 *t* 检验。同组病例术前和术后多裂肌等级比较采用 Wilcoxon 符号秩检验,组间多裂肌等级比较采用 Wilcoxon 秩和检验。检验水准为  $\alpha=0.05$ 。

2 结果

两组病例均获得随访,时间 12~84 (43.50 ± 15.84) 个月。两组患者典型病例影像学资料见图 1, 2。

2.1 一般情况

肌间隙组在切口长度、术中出血量和术后切口引流量方面明显优于正中切口组( $P<0.05$ )。两组患者手术时间差异无统计学意义( $P>0.05$ )。见表 2。

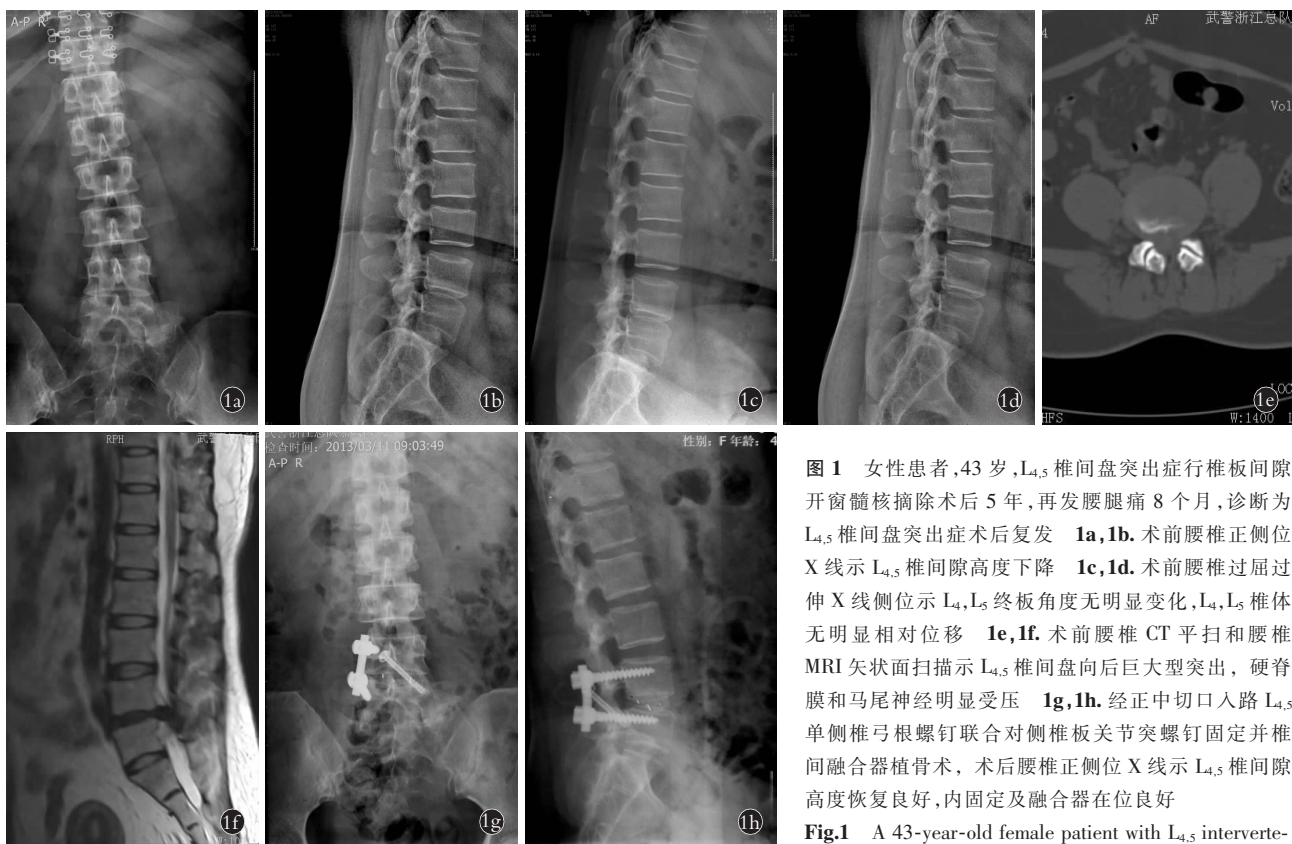
2.2 影像学结果

(1)椎弓根螺钉位置。正中切口组 I 度 45 枚, II 度 3 枚(螺钉部分进入椎管),螺钉位置不良率 6.25%;肌间隙组 I 度 49 枚螺钉, II 度 5 枚螺钉,螺钉位置不良率 9.26%,螺钉位置不良率两组差异无统计学意义( $t=1.523, P=0.061$ )。(2)椎板关节突螺钉位置。正中切口组 I 型 21 枚, II 型 2 枚, III 型 1 枚,

表 2 两组复发性腰椎间盘突出症患者切口长度、手术时间、术中出血量和术后切口引流量比较( $\bar{x} \pm s$ )

Tab.2 Comparison of the incision length, operation time, intraoperative blood loss and postoperative drainage volume of patients with recurrent lumbar disc herniation between two groups( $\bar{x} \pm s$ )

组别	例数	切口长度(cm)	手术时间(min)	术中出血量(ml)	术后切口引流量(ml)
正中切口组	24	4.81±0.57	86.00±8.35	232.00±38.86	158.00±56.85
肌间隙组	27	2.93±0.35	85.00±7.79	178.00±29.64	96.00±25.19
<i>t</i> 值		9.25	2.89	5.23	7.38
<i>P</i> 值		0.007	0.695	0.036	0.027



**图 1** 女性患者,43 岁,L<sub>4,5</sub> 椎间盘突出症行椎板间隙开窗髓核摘除术后 5 年,再发腰腿痛 8 个月,诊断为 L<sub>4,5</sub> 椎间盘突出症术后复发 **1a,1b**. 术前腰椎正侧位 X 线示 L<sub>4,5</sub> 椎间隙高度下降 **1c,1d**. 术前腰椎过屈过伸 X 线侧位示 L<sub>4,5</sub> 终板角度无明显变化,L<sub>4,5</sub> 椎体无明显相对位移 **1e,1f**. 术前腰椎 CT 平扫和腰椎 MRI 矢状面扫描示 L<sub>4,5</sub> 椎间盘向后巨大型突出,硬脊膜和马尾神经明显受压 **1g,1h**. 经正中切口入路 L<sub>4,5</sub> 单侧椎弓根螺钉联合对侧椎板关节突螺钉固定并椎间融合器植骨术,术后腰椎正侧位 X 线示 L<sub>4,5</sub> 椎间隙高度恢复良好,内固定及融合器在位良好

**Fig.1** A 43-year-old female patient with L<sub>4,5</sub> intervertebral disc herniation, 5 years after nucleus pulposus resection

tion through lamina fenestration, complaining recurring lower back and leg pain for 8 months, was diagnosed as recurrent L<sub>4,5</sub> intervertebral disc herniation after surgery **1a,1b**. Preoperative AP and lateral X-rays showed the height of L<sub>4,5</sub> intervertebral space decreased **1c,1d**. Preoperative lateral X-rays of lumbar spine hyperflexion and extension showed no significant change in the angle of the L<sub>4</sub> and L<sub>5</sub> endplates, and no significant relative displacement of the L<sub>4</sub> and L<sub>5</sub> vertebra **1e,1f**. Preoperative lumbar CT and sagittal MRI showed evident protrusion of L<sub>4,5</sub> intervertebral disc, and the dura mater and cauda equina were significantly compressed **1g,1h**. Unilateral pedicle screw fixation combined with contralateral translaminar facet screw fixation and interbody fusion was performed through median incision approach. Postoperative lumbar AP and lateral X-rays showed that the height of the L<sub>4,5</sub> intervertebral space was recovered, and the positions of internal fixation and fusion cage were good

螺钉位置不良率 12.50%;肌间隙组 I 型 22 枚, II 型 4 枚, III 型 1 枚,螺钉位置不良率 18.52%,两组差异有统计学意义( $t=3.161, P=0.041$ )。 (3) 病变节段椎间隙高度。组内比较:两组患者术后病变节段椎间隙高度均较术前有明显恢复( $P<0.05$ ),末次随访时、术后 3~5 d 与术前比较差异亦有统计学意义( $P>0.05$ ),说明两组椎间隙高度在随访过程中均出现较为明显的丢失。组间比较:手术前后两组椎间隙高度差异均无统计意义( $P>0.05$ )。见表 3。(4) 腰椎冠状面及矢状面 Cobb 角。末次随访两组患者腰椎冠状面及矢状面 Cobb 角与术前比较差异均有统计学意义 ( $P<0.05$ ),即腰椎冠状面和矢状面平衡获得了很好的改善;术前和末次随访组间比较差异均无统计学意义 ( $P>0.05$ )。见表 4。(5) 多裂肌面积和等级。两组病例术前、术后 12 个月多裂肌面积和等级见表 5。多裂肌面积方面:正中切口组术后 12 个月与术前比较差异有统计学意义( $P<0.05$ );肌间隙组术后 12 个月与术前比较差异无统计学意义( $P>0.05$ ),两组术前比较

**表 3** 两组复发性腰椎间盘突出症患者手术前后病变节段椎间隙高度比较( $\bar{x}\pm s, \text{mm}$ )

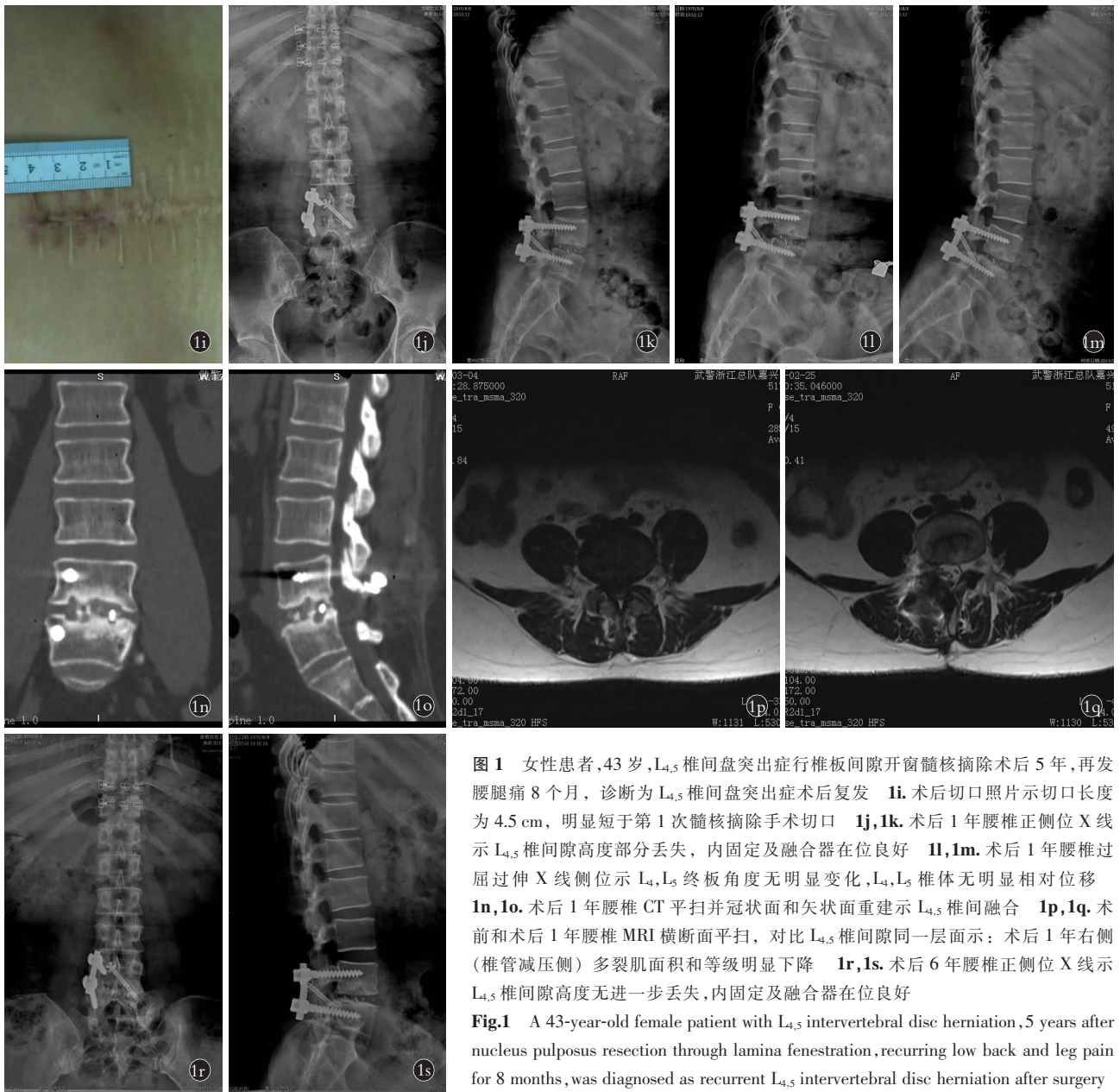
**Tab.3 Comparison of the lesion segmental intervertebral space height between two groups with recurrent lumbar disc herniation before and after operation( $\bar{x}\pm s, \text{mm}$ )**

组别	例数	术前	术后 3~5 d	末次随访
正中切口组	24	9.07±1.03	11.77±0.48 <sup>□</sup>	10.35±1.07 <sup>■</sup>
肌间隙组	27	9.10±1.12	11.89±0.65 <sup>△</sup>	10.51±1.11 <sup>▲</sup>
<i>t</i> 值		1.75	1.97	0.89
<i>P</i> 值		0.212	0.185	0.421

注:与术前比较,  $\square t=2.76, P=0.021$ ;  $\triangle t=2.82, P=0.016$ ;与术后 3~5 d 比较,  $\blacksquare t=1.32, P=0.041$ ;  $\blacktriangle t=1.25, P=0.045$

Note: Compared preoperative data,  $\square t=2.76, P=0.021$ ;  $\triangle t=2.82, P=0.016$ . Compared with postoperative 3 to 5 days,  $\blacksquare t=1.32, P=0.041$ ;  $\blacktriangle t=1.25, P=0.045$

差异无统计学意义( $P>0.05$ ),术后 12 个月比较差异有统计学意义( $P<0.05$ )。多裂肌等级方面:正中切口



**图 1** 女性患者,43 岁,L<sub>4,5</sub> 椎间盘突出症行椎板间隙开窗髓核摘除术后 5 年,再发腰腿痛 8 个月,诊断为 L<sub>4,5</sub> 椎间盘突出症术后复发 **1i**。术后切口照片示切口长度为 4.5 cm,明显短于第 1 次髓核摘除手术切口 **1j,1k**。术后 1 年腰椎正侧位 X 线示 L<sub>4,5</sub> 椎间隙高度部分丢失,内固定及融合器在位良好 **1l,1m**。术后 1 年腰椎过屈过伸 X 线侧位示 L<sub>4,5</sub> 终板角度无明显变化,L<sub>4,5</sub> 椎体无明显相对位移 **1n,1o**。术后 1 年腰椎 CT 平扫并冠状面和矢状面重建示 L<sub>4,5</sub> 椎间融合 **1p,1q**。术前和术后 1 年腰椎 MRI 横断面平扫,对比 L<sub>4,5</sub> 椎间隙同一层面示:术后 1 年右侧(椎管减压侧)多裂肌面积和等级明显下降 **1r,1s**。术后 6 年腰椎正侧位 X 线示 L<sub>4,5</sub> 椎间隙高度无进一步丢失,内固定及融合器在位良好

**Fig.1** A 43-year-old female patient with L<sub>4,5</sub> intervertebral disc herniation,5 years after nucleus pulposus resection through lamina fenestration,recurring low back and leg pain for 8 months,was diagnosed as recurrent L<sub>4,5</sub> intervertebral disc herniation after surgery

**1i**. The picture of the postoperative incision showed that the length of the incision was 4.5 cm,which was significantly shorter than the first surgical incision for nucleus pulposus removal **1j,1k**. One year after operation,the lumbar AP and lateral X-rays showed L<sub>4,5</sub> intervertebral height was partially lost and the positions of internal fixation and fusion cage were well **1l,1m**. One year after operation,the lumbar lateral X-rays of hyperflexion and extension showed no significant change in the angle of the L<sub>4</sub> and L<sub>5</sub> endplates,and no significant relative displacement of the L<sub>4</sub> and L<sub>5</sub> vertebrae **1n,1o**. One year after operation,the lumbar CT showed successful interbody fusion of L<sub>4,5</sub> **1p,1q**. Cross-sectional lumbar MRI before operation and 1 year after operation,comparing the same level of L<sub>4,5</sub> intervertebral space. Area and grade of the multifidus muscle on the right side (the side of spinal canal decompression) decreased significantly after 1 year **1r,1s**. Six years after operation,the lumbar AP and lateral X-rays showed no further lost on L<sub>4,5</sub> intervertebral height and the positions of pedicle screw and translaminar facet screw were satisfactory

组术后 12 个月与术前比较差异有统计学意义 ( $P < 0.05$ ),肌间隙组术后 12 个月与术前比较差异无统计学意义 ( $P > 0.05$ ),两组术前比较差异无统计学意义 ( $P > 0.05$ ),术后 12 个月比较差异有统计学意义 ( $P < 0.05$ )。

随访过程中出现终板切割并融合器部分陷入椎体内 9 例(正中切口组 4 例,肌间隙组 5 例),均未影

响植骨融合,未发现椎弓根螺钉与椎板关节突螺钉松动、移位、断裂或椎间融合器前后向移位。根据评价标准,除 4 例不能明确(椎间融合器内骨质稀疏,并可见透亮线,其中正中切口组 2 例,肌间隙组 2 例)外,其余均获得椎间融合,其中正中切口组融合率为 91.7%(22/24),肌间隙组融合率为 92.6%(25/27)两组差异无统计学意义( $t = 0.272, P = 1.524$ )。

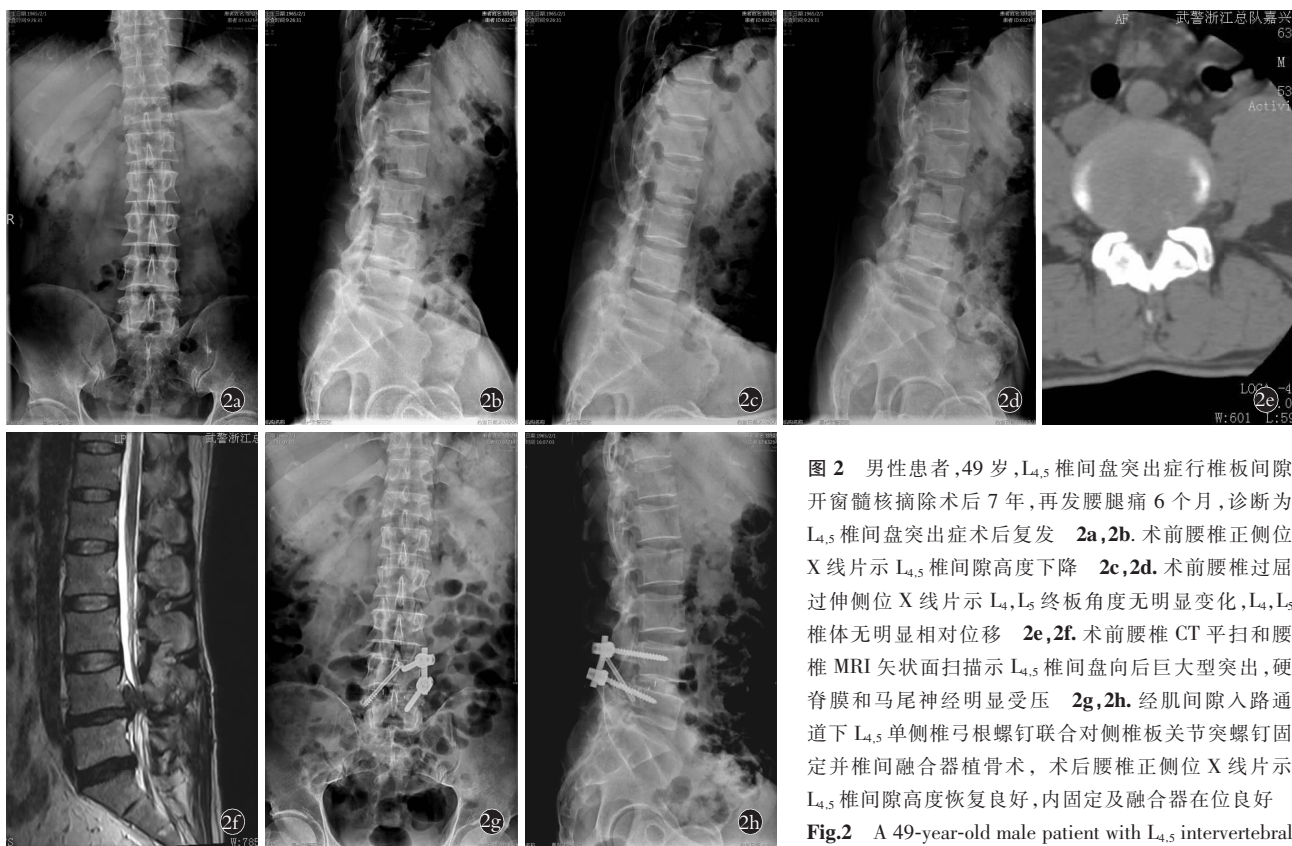


图 2 男性患者,49 岁,L<sub>4,5</sub> 椎间盘突出症行椎板间隙开窗髓核摘除术后 7 年,再发腰腿痛 6 个月,诊断为 L<sub>4,5</sub> 椎间盘突出症术后复发 2a,2b. 术前腰椎正侧位 X 线片示 L<sub>4,5</sub> 椎间隙高度下降 2c,2d. 术前腰椎过屈过伸侧位 X 线片示 L<sub>4</sub>,L<sub>5</sub> 终板角度无明显变化,L<sub>4</sub>,L<sub>5</sub> 椎体无明显相对位移 2e,2f. 术前腰椎 CT 平扫和腰椎 MRI 矢状面扫描示 L<sub>4,5</sub> 椎间盘向后巨大型突出,硬脊膜和马尾神经明显受压 2g,2h. 经肌间隙入路通道下 L<sub>4,5</sub> 单侧椎弓根螺钉联合对侧椎板关节突螺钉固定并椎间融合器植骨术,术后腰椎正侧位 X 线片示 L<sub>4,5</sub> 椎间隙高度恢复良好,内固定及融合器在位良好

through lamina fenestration, complaining recurring lower back and leg pain for 6 months, was diagnosed as recurrent L<sub>4,5</sub> intervertebral disc herniation after surgery 2a,2b. Preoperative AP and lateral X-rays showed the height of L<sub>4,5</sub> intervertebral space decreased 2c,2d. Preoperative lateral X-rays of lumbar spine hyperflexion and extension showed no significant change in the angle of the L<sub>4</sub> and L<sub>5</sub> endplates, and no significant relative displacement of the L<sub>4</sub> and L<sub>5</sub> vertebra 2e,2f. Preoperative lumbar CT and sagittal MRI showed evident protrusion of L<sub>4,5</sub> intervertebral disc, and the dura mater and cauda equina were significantly compressed 2g,2h. Unilateral pedicle screw fixation combined with contralateral translaminar facet screw fixation and interbody fusion was performed through muscle-splitting approach. Postoperative lumbar AP and lateral X-rays showed that the height of the L<sub>4,5</sub> intervertebral space was recovered, and the positions of internal fixation and fusion cage were good

表 4 两组复发性腰椎间盘突出症患者手术前后腰椎冠状面及矢状面 Cobb 角变化 ( $\bar{x} \pm s, ^\circ$ )

Tab.4 Comparison of Cobb angle changes in coronal and sagittal plane of patients with recurrent lumbar disc herniation between two groups before and after operation ( $\bar{x} \pm s, ^\circ$ )

组别	例数	腰椎冠状面 Cobb 角		腰椎矢状面 Cobb 角	
		术前	末次随访	术前	末次随访
正中切口组	24	2.37±1.14	1.18±0.85*	42.8±6.35	52.6±7.582**
肌间隙组	27	2.28±1.09	0.97±0.91 <sup>△</sup>	44.5±7.20	53.8±8.22 <sup>△△</sup>
t 值		0.87	1.63	1.33	1.24
P 值		0.712	0.551	0.108	0.137

注:与术前比较,\* $t=6.98, P=0.021$ ;<sup>△</sup> $t=7.95, P=0.015$ ;\*\* $t=3.52, P=0.041$ ;<sup>△△</sup> $t=3.36, P=0.043$

Note:Compared with peroperative data, \* $t=6.98, P=0.021$ ;<sup>△</sup> $t=7.95, P=0.015$ ;\*\* $t=3.52, P=0.041$ ;<sup>△△</sup> $t=3.36, P=0.043$

两组病例均未观察到固定部位邻近节段的明显退变

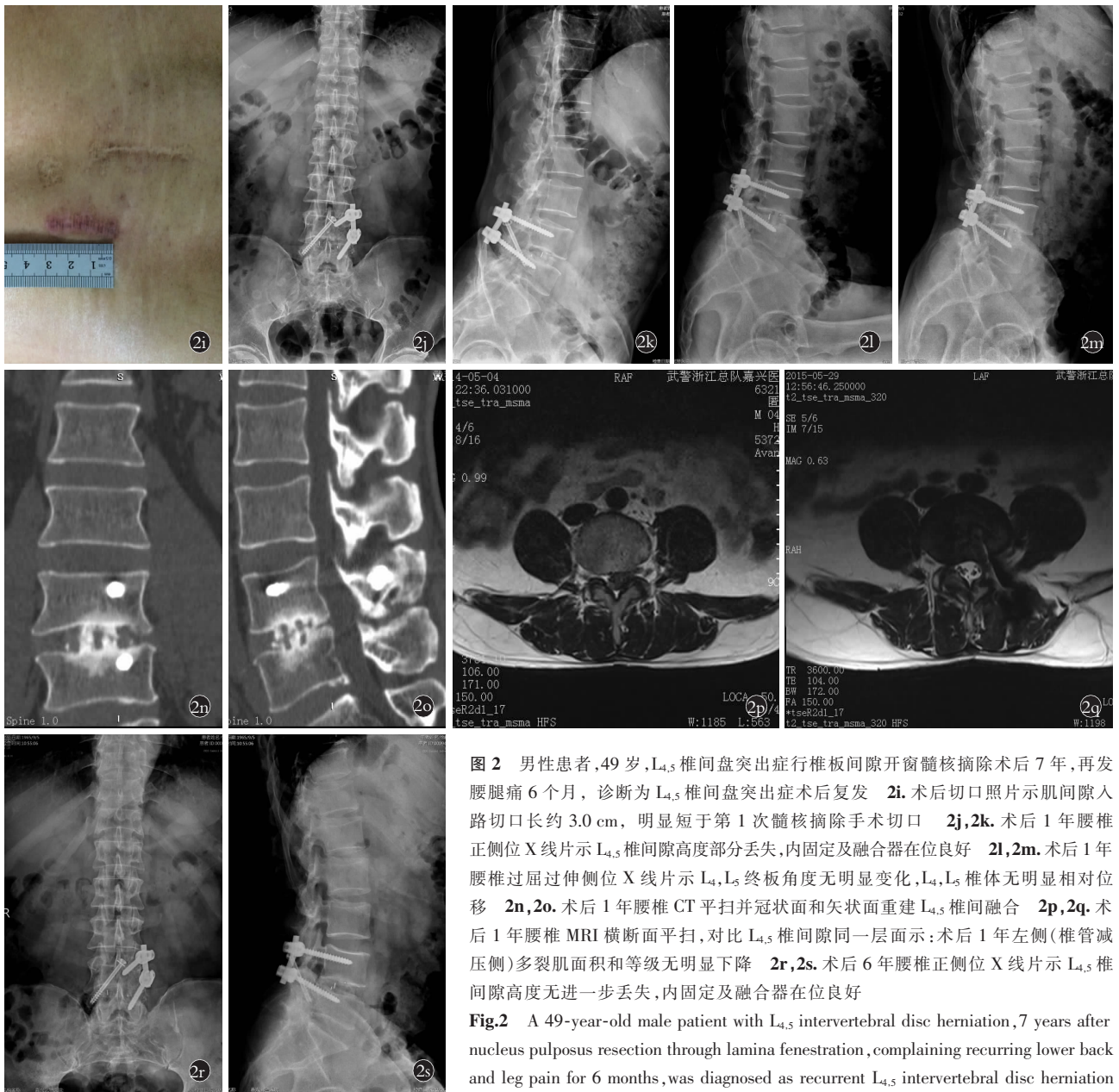
(包括椎间盘突出、椎间隙高度明显下降、明显的骨质增生和局部畸形),而在椎板关节突螺钉固定侧其关节突出现程度不等的骨融合现象。

### 2.3 临床效果

术后 72 h 腰部切口疼痛 VAS 评分:正中切口组 0~4 (1.61±0.54) 分;肌间隙组 0~2 (0.76±0.28) 分,两组差异有统计学意义 ( $t=6.584, P=0.007$ )。JOA 评分正中切口组由术前的 (12.03±2.25) 分提高到末次随访时的 (25.00±2.38) 分,两者比较差异有统计学意义 ( $t=6.138, P=0.011$ );肌间隙组由术前的 (12.22±2.30) 分提高到末次随访时的 (26.35±1.79) 分,两者比较差异有统计学意义 ( $t=6.925, P=0.008$ )。末次随访时两组 JOA 评分比较差异无统计学意义 ( $t=1.859, P=0.132$ )。

### 2.4 并发症情况

正中切口组术中椎弓根入点骨折 1 例,术中硬脊膜撕裂 1 例,术后神经根损伤 1 例;肌间隙组术中椎弓根入点骨折 1 例,术中硬脊膜撕裂 2 例,术后切



**图 2** 男性患者,49 岁,L<sub>4,5</sub> 椎间盘突出症行椎板间隙开窗髓核摘除术后 7 年,再发腰腿痛 6 个月,诊断为 L<sub>4,5</sub> 椎间盘突出症术后复发 2i. 术后切口照片示肌间隙入路切口长约 3.0 cm,明显短于第 1 次髓核摘除手术切口 2j,2k. 术后 1 年腰椎正侧位 X 线片示 L<sub>4,5</sub> 椎间隙高度部分丢失,内固定及融合器在位良好 2l,2m. 术后 1 年腰椎过屈过伸侧位 X 线片示 L<sub>4,5</sub> 终板角度无明显变化,L<sub>4,5</sub> 椎体无明显相对位移 2n,2o. 术后 1 年腰椎 CT 平扫并冠状面和矢状面重建 L<sub>4,5</sub> 椎间融合 2p,2q. 术后 1 年腰椎 MRI 横断面平扫,对比 L<sub>4,5</sub> 椎间隙同一层面示:术后 1 年左侧(椎管减压侧)多裂肌面积和等级无明显下降 2r,2s. 术后 6 年腰椎正侧位 X 线片示 L<sub>4,5</sub> 椎间隙高度无进一步丢失,内固定及融合器在位良好

**Fig.2** A 49-year-old male patient with L<sub>4,5</sub> intervertebral disc herniation,7 years after nucleus pulposus resection through lamina fenestration,complaining recurring lower back and leg pain for 6 months,was diagnosed as recurrent L<sub>4,5</sub> intervertebral disc herniation after surgery 2i. The picture of the postoperative incision showed that the incision of the muscle-splitting approach was about 3.0 cm,which was significantly shorter than the first surgical incision for nucleus pulposus removal 2j,2k. One year after operation,the lumbar AP and lateral X-rays showed L<sub>4,5</sub> intervertebral height was partially lost and the positions of internal fixation and fusion cage were well 2l,2m. One year after operation,the lumbar lateral X-rays of hyperflexion and extension showed no significant change in the angle of the L<sub>4</sub> and L<sub>5</sub> endplates,and no significant relative displacement of the L<sub>4</sub> and L<sub>5</sub> vertebrae 2n,2o. One year after operation,the lumbar CT showed successful interbody fusion of L<sub>4,5</sub> 2p,2q. Cross-sectional lumbar MRI before operation and 1 year after operation,comparing the same level of L<sub>4,5</sub> intervertebral space. Area and grade of the multifidus muscle on the left side (the side of spinal canal decompression) decreased significantly after 1 year 2r,2s. Six years after operation,the lumbar AP and lateral X-rays showed no further lost on L<sub>4,5</sub> intervertebral height and the positions of pedicle screw and translamina facet screw were satisfactory

口表皮坏死 2 例,切口愈合不良 1 例,神经根损伤 1 例。经影像学检查,2 例神经根损伤均为椎弓根螺钉位置不正确所致,明确后即予椎弓根螺钉调整术,神经根症状分别于术后 3、6 个月完全恢复。两组病例均未发生切口感染。并发症发生率:正中切口组 12.50%,肌间隙组 25.93%,肌间隙组高于正中切口

组( $t=5.772,P=0.010$ )。

### 3 讨论

#### 3.1 复发性腰椎间盘突出症的临床与病理特点

腰椎间盘突出症髓核摘除术后复发是临床上常见的现象<sup>[1-5]</sup>,根据两组病例,笔者总结髓核摘除术后复发具有以下临床和病理特点:初次手术至复发



表 5 两组复发性腰椎间盘突出症患者手术前后多裂肌面积和等级变化

Tab.5 Comparison of the area and grade of multifidus between two groups with recurrent lumbar disc herniation before and after operation

组别	例数	多裂肌面积( $\bar{x}\pm s, \text{mm}^2$ )		多裂肌等级(例)				
		术前	术后 12 个月	术前		术后 12 个月		
				2 级	3 级	2 级	3 级	4 级
正中切口组	24	985.00±137.52	718.00±121.22*	5	19	0	10	14
肌间隙组	27	972.00±128.21	906.00±115.36 <sup>△</sup>	6	21	1	22	4
检验值		$t=1.64$	$t=4.48$	$H=273$		$H=387$		
P 值		0.839	0.043	0.088		0.031		

注:与术前比较, \* $t=4.79, P=0.034$ ; <sup>△</sup> $t=2.41, P=0.083$ 。多裂肌等级:正中切口组, 术后 12 个月与术前相比,  $H=442, P=0.033$ ; 肌间隙组: 术后 12 个月与术前相比,  $H=294, P=0.124$

Note: Compared with peroperative data, \* $t=4.79, P=0.034$ ; <sup>△</sup> $t=2.41, P=0.083$ . Multifidus grade: compared 12 months postoperative with preoperative,  $H=442, P=0.033$  in median incision group and  $H=294, P=0.124$  in muscle-splitting group

时间不等, 多存在神经压迫, 特别是神经根的卡压; 由于经历过开放椎板间隙开窗髓核摘除手术, 骶棘肌存在不同程度的损害, 两组病例术前多裂肌等级 2 级为 11 例, 3 级为 40 例; 硬脊膜、神经根与黄韧带、后纵韧带及周围组织间存在明显的粘连。

### 3.2 肌间隙入路通道下的操作特点与临床意义

采用正中切口单侧椎弓根螺钉联合对侧椎板关节突螺钉固定并椎间融合方式, 与传统的正中切口两侧显露相比, 手术入路和显露方式是一致的, 前者仅仅是做一侧骶棘肌剥离, 因而具有上手快、手术视野广、操作方便等优点, 比较适合复发的腰椎间盘突出症的手术治疗。肌间隙入路通道下操作, 由于采用肌间隙钝性分离进入, 通道的应用可以实现切口的最大化显露, 而且视野恒定、照明良好, 同时显露的空间正好是手术的目标区, 操作直接。因而, 在手术切口、术中出血量、术后切口引流液、术后腰部切口疼痛方面, 两种手术入路差异有统计学意义, 肌间隙入路通道显露切口小、创伤小、出血少、术后腰部切口疼痛反应轻、恢复快, 而且, 肌间隙入路通道下操作并没有增加手术时间。但由于肌间隙入路术野相对较小, 特别是棘突基底显露不甚方便, 从而影响椎板关节突螺钉入点的判断, 因而, 与既往文献报道<sup>[22]</sup>相同, 肌间隙入路组椎板关节突螺钉位置不良率高于正中切口组。由于两组病例既往均经历过正中切口骶棘肌剥离椎板间隙开窗髓核摘除手术, 因而, 术前两组病例的多裂肌面积均有减少、等级下降。本次固定融合术后 12 个月, 正中切口组多裂肌面积进一步减少、等级下降较为明显, 与术前对比有统计学差异, 而肌间隙入路组多裂肌面积减少和等级下降均不明显, 与术前比较差异无统计学意义。虽然术前多裂肌面积和等级两组比较差异无统计学意义, 但术后 12 个月对比, 肌间隙组多裂肌面积和等级均好于

正中切口组, 说明正中切口入路进一步加重了多裂肌的损害, 而肌间隙入路通道的应用对于多裂肌发挥了较好的保护作用。两组病例病变节段椎间高度术后均获得较好的恢复, 但在随访过程中出现了椎间高度丢失, 但未影响椎间融合, 两组病例的椎间融合率分别为: 正中切口组 91.7%, 肌间隙组 92.6%, 两组比较差异无统计学意义。由于两组病例减压、融合、固定方式完全一致, 且术前两组病例在病变椎间高度、腰椎冠状面和矢状面 Cobb 角方面差异无统计学意义, 因此, 无论是术后椎间高度, 以及末次随访时的椎间高度、腰椎冠状面和矢状面 Cobb 角方面, 两组比较差异无统计学意义。随访过程中未出现内固定松动、断裂和融合器移位等现象。末次随访时, 两组病例 JOA 评分明显提高, 说明腰椎功能均获得很好的恢复, 两组比较差异无统计学意义。由于肌间隙入路通道显露下的操作是一个全新的手术入路、显露方式和操作空间, 存在学习曲线, 需要一个逐渐熟悉、适应的过程, 因而并发症方面, 肌间隙组并发症发生率高于正中切口组。但分析两组病例并发症的构成, 切口问题是导致肌间隙入路并发症较高的重要因素, 且多出现在早期开展病例, 经换药后均获得好转, 未出现严重后果, 而在神经损伤等严重并发症方面两组基本相同, 且未造成永久性损害。

### 3.3 注意事项与不足之处

对于腰椎间盘突出症术后的复发, 由于经历椎间盘髓核摘除, 如本组病例初次手术均采用开放的椎板间入路, 易导致硬脊膜、神经根和周围组织的粘连, 且复发病例多伴有神经根压迫。因此, 再次手术时, 无论是采用正中切口入路或肌间隙入路, 在行髓核摘除、神经减压或松解时均需避免对突出椎间盘、硬脊膜和神经根的直接操作, 建议先咬除上下残留

椎板、侧方关节突,以扩大骨窗,进入椎板与硬脊膜的正常间隙,然后仔细推移硬脊膜和神经根,显露病变椎间隙,采取由正常至病变部位的包抄方式。先行椎间隙处理,即清除椎间髓核、终板软骨,待椎间隙清除基本干净后,再探查并仔细分离突出或游离于椎管内的髓核,如硬脊膜或神经根与纤维环或髓核之间存在粘连,需仔细分离,而硬脊膜与后纵韧带之间的粘连或硬脊膜与神经根之间的粘连则无需松解,以免出现硬脊膜或神经根损伤。肌间隙入路通道下单侧椎弓根螺钉联合对侧椎板关节突螺钉固定并椎间融合治疗复发的腰椎间盘突出症,由于是在一个全新且较小的空间内操作,加之本病所具有的病理特点,可能延长学习曲线,增加手术风险,建议:(1)术者需具有丰富的腰椎开放手术经验。(2)度过肌间隙入路通道显露操作技术的学习曲线后再考虑在复发性腰椎间盘突出症中的应用。(3)术中操作要细致,避免对硬脊膜和神经根的粗暴显露、松解。(4)尽量使用高度合适、面积较大的融合器,如香蕉形融合器或一侧置入双枚普通融合器,以增加纤维环的张力、融合器的稳定和接触面积,有利于力学传导、减少椎间隙高度丢失、加速融合并促进融合质量的提高。不足之处:本研究病例数较少,随访时间亦不够长,有待加大样本量并加强随访。

总之,采用肌间隙入路通道下单侧椎弓根螺钉联合对侧椎板关节突螺钉固定并椎间融合治疗复发的腰椎间盘突出症,不仅具有可行性,而且临床效果良好,大大缩小了切口、减少了创伤、减少了出血,术后反应轻,恢复快,特别是对于多裂肌发挥了较好的保护作用,同时未增加严重并发症的发生,值得临床选择应用。

#### 参考文献

- [1] 郭继东,侯树勋,李利,等.椎板开窗髓核摘除术治疗腰椎间盘突出症 10 年以上随访的疗效评价[J].中国骨伤,2013,26(1):24-28.  
GUO JD,HOU SX,LI L,et al. Laminectomy and extraction of nucleus pulposus for the treatment of lumbar disc herniation;effect evaluation of over 10 year followed-up[J]. Zhongguo Gu Shang/Chinese J Orthop Trauma, 2013,26(1):24-28. Chinese with abstract in English.
- [2] Landi A,Grasso G,Mancarella C,et al. Recurrent lumbar disc herniation:Is there a correlation with the surgical technique? A multivariate analysis[J]. Craniovertebr Junction Spine, 2018,9(4):260-266.
- [3] Shin EH,Cho KJ,Kim YT,et al. Risk factors for recurrent lumbar disc herniation after discectomy[J]. Int Orthop, 2019,43(4):963-967.
- [4] Li Z,Yang H,Liu M,et al. Clinical characteristics and risk factors of recurrent lumbar disk herniation;a retrospective analysis of three hundred twenty-one cases[J]. Spine (Phila Pa 1976), 2018,43(21):1463-1469.
- [5] Dower A,Chatterji R,Swart A,et al. Surgical management of recurrent lumbar disc herniation and the role of fusion[J]. Clin Neurosci, 2016,23:44-50.
- [6] Mashhadinezhad H,Sarabi E,Mashhadinezhad S,et al. Clinical outcomes after microdiscectomy for recurrent lumbar disk herniation:a single-center study[J]. Arch Bone Jt Surg, 2018,6(5):397-401.
- [7] Benzakour A,Benzakour T. Lumbar disc herniation;long-term outcomes after mini-open discectomy[J]. Int Orthop, 2019,43(4):869-874.
- [8] Selva-Sevilla C,Ferrara P,Gerónimo-Pardo M. Cost-utility analysis for recurrent lumbar disc herniation;conservative treatment versus discectomy versus discectomy with fusion[J]. Clin Spine Surg, 2019,32(5):E228-E234.
- [9] Yüce I,Kahyaoglu O,Çavusoglu H,et al. Surgical outcome and efficacy of lumbar microdiscectomy technique with preserving of ligamentum flavum for recurrent lumbar disc herniations[J]. Clin Neurosci, 2019,63:43-47.
- [10] Jang JS,Lee SH. Minimally invasive transforaminal lumbar interbody fusion with ipsilateral pedicle screw and contralateral facet screw fixation[J]. Neurosurg Spine, 2005,3(3):218-223.
- [11] Fernández-Fairen M,Sala P,Ramírez H,et al. A prospective randomized study of unilateral versus bilateral instrumented posterolateral lumbar fusion in degenerative spondylolisthesis[J]. Spine(Phila Pa 1976), 2007,32(4):395-401.
- [12] Sethi A,Lee S,Vaidya R. Transforaminal lumbar interbody fusion using unilateral pedicle screws and a translaminal screw[J]. Eur Spine, 2009,18(3):430-434.
- [13] 曾忠友,严卫锋,陈国军,等.单侧椎弓根螺钉联合对侧椎板关节突螺钉固定并椎间融合治疗下腰椎病变的临床观察[J].中华骨科杂志,2011,31(8):834-839.  
ZENG ZY,YAN WF,CHEN GJ,et al. Clinical study of unilateral pedicle screw combined with contralateral translaminal facet screw fixation by percutaneous and interbody fusion to treat low lumbar vertebra diseases[J]. Zhonghua Gu Ke Za Zhi, 2011,31(8):834-839. Chinese.
- [14] 曾忠友,吴鹏,孙德弢,等.两种不同固定方式并椎间融合治疗腰椎双节段病变的临床对比研究[J].中国骨伤,2015,28(10):903-909.  
ZENG ZY,WU P,SUN DT,et al. The clinical comparative research of two different fixation and interbody fusion in the treatment of lumbar double segment lesions[J]. Zhongguo Gu Shang/Chinese J Orthop Trauma, 2015,28(10):903-909. Chinese with abstract in English.
- [15] Zeng ZY,Wu P,Yan WF,et al. Mixed fixation and interbody fusion for treatment single-segment lower lumbar vertebral disease: midterm follow-up results[J]. Orthop Surg, 2015,7(11):324-332.
- [16] Cao Y,Chen Z,Jiang C,et al. The combined use of unilateral pedicle screw and contralateral facet joint screw fixation in transforaminal lumbar interbody fusion[J]. Eur Spine, 2015,24(11):2607-2613.
- [17] Foley KT,Holly LT,Schwender JD. Minimally invasive lumbar fusion[J]. Spine (Phila Pa 1976), 2003,28(15 Suppl):S26-S35.
- [18] Schwender JD,Holly LT,Rouben DP,et al. Minimally invasive transforaminal lumbar interbody fusion (TLIF):technical feasibility

- lity and initial results[J]. Spinal Disord Tech, 2005, 18 (Suppl): S1-S6.
- [19] Holly LT, Schwender JD, Rouben DP, et al. Minimally invasive transforaminal lumbar interbody fusion: indications, technique, and complications[J]. Neurosurg Focus, 2006, 20(3): E6.
- [20] 毛克亚, 王岩. 单侧微创经椎间孔腰椎体间融合术采用椎弓根螺钉结合经椎板关节突螺钉混合内固定可行性研究[J]. 中华外科杂志, 2011, 49(12): 1067-1070.  
MAO KY, WANG Y. A feasibility research of unilateral incision minimally invasive transforaminal lumbar interbody fusion using pedicle screws and a translaminar screw hybrid fixation[J]. Zhonghua Wai Ke Za Zhi, 2011, 49(12): 1067-1070. Chinese.
- [21] 曾忠友, 宋永兴, 吴鹏, 等. 肌间隙入路通道下椎间融合术治疗腰椎病变的近期疗效[J]. 中华骨科杂志, 2015, 35(12): 1191-1199.  
ZENG ZY, SONG YX, WU P, et al. Early clinical results of channel-assisted combined fixation and interbody fusion for treating lumbar vertebra diseases by muscle-splitting approach[J]. Zhonghua Gu Ke Za Zhi, 2015, 35(12): 1191-1199. Chinese.
- [22] 曾忠友, 张建乔, 严卫锋, 等. 单节段腰椎病变通道下肌间隙入路三种固定方式的对比研究[J]. 中华骨科杂志, 2017, 37(8): 480-491.  
ZENG ZY, ZHANG JQ, YAN WF, et al. Three different fixation methods combined with lumbar interbody fusion for the treatment of single segmental lumbar vertebra diseases through muscle-splitting approach: a clinical comparison study[J]. Zhonghua Gu Ke Za Zhi, 2017, 37(8): 480-491. Chinese.
- [23] 曾忠友, 严卫锋, 宋永兴, 等. 两种手术入路联合固定并椎间融合治疗腰椎单节段病变的临床研究[J]. 中国骨伤, 2017, 30(5): 417-425  
ZENG ZY, YAN WF, SONG YX, et al. Two different surgical approaches combined fixation with lumbar interbody fusion for the treatment of single segmental lumbar vertebra diseases [J]. Zhongguo Gu Shang/China J Orthop Trauma, 2017, 30(5): 417-425. Chinese with abstract in English.
- [24] 王正安, 曾忠友, 张建乔, 等. 通道下联合固定并椎间不同融合器植骨治疗腰椎疾患的病例对照研究[J]. 中国骨伤, 2020, 33(4): 337-347.  
WANG ZA, ZENG ZY, ZHANG JQ, et al. Comparison of different cages interbody fusion and combined fixation for treating lumbar diseases through intermuscular approach[J]. Zhongguo Gu Shang/China J Orthop Trauma, 2020, 33(4): 337-347. Chinese with abstract in English.
- [25] 曾忠友, 江春宇, 宋永兴, 等. 下腰椎椎板、关节突的影像学测量与临床意义[J]. 中国临床解剖学杂志, 2009, 27(4): 420-422, 425.  
ZENG ZY, JIANG CY, SONG YX, et al. Imageology of the laminar and articular process of low lumbar laminar and its clinic significance[J]. Zhongguo Lin Chuang Jie Pou Xue Za Zhi, 2009, 27(4): 420-422, 425. Chinese.
- [26] 曾忠友, 吴鹏, 宋国浩. 组配型横突钩的研制与临床应用[J]. 脊柱外科杂志, 2015, 13(1): 28-32.  
ZENG ZY, WU P, SONG GH. Clinical application and manufacture of matched lumbar transverse process retractor device[J]. Ji Zhu Wai Ke Za Zhi, 2015, 13(1): 28-32. Chinese.
- [27] 曾忠友, 江春宇, 张建乔, 等. 腰椎椎板关节突螺钉瞄准器的研制[J]. 中国骨与关节损伤杂志, 2009, 24(4): 761-762.  
ZENG ZY, JIANG CY, ZHANG JQ, et al. Manufacture of lumbar vertebra translamina facet screw aiming device[J]. Zhongguo Gu Yu Guan Jie Sun Shang Za Zhi, 2009, 24(4): 761-762. Chinese.
- [28] 曾忠友, 陈国军, 汤永华, 等. 椎板关节突螺钉两种不同置钉方法的临床对比研究[J]. 中国临床解剖学杂志, 2011, 29(5): 581-584.  
ZENG ZY, CHEN GJ, TANG YH, et al. The comparison of two methods for placing translamina facet screw[J]. Zhongguo Lin Chuang Jie Pou Xue Za Zhi, 2011, 29(5): 581-584. Chinese.
- [29] Zeng ZY, Zhang JQ, Song YX, et al. Combination of percutaneous unilateral translaminar facet screw fixation and interbody fusion for treatment of lower lumbar vertebra diseases: a follow-up study [J]. Orthop Surg, 2014, 6(2): 110-117.
- [30] Goutallier D, Postel JM, Bernageau J, et al. Fatty muscle degeneration in cuff ruptures: pre- and postoperative evaluation by CT scan [J]. Clin Orthop Relat Res, 1994, 304: 78-83.
- [31] Xu RM, Nabil A, Ebraheim, Yianjia Ou, et al. Anatomy considerations of pedicle screw placement in the thoracic spine: Roy-Camille technique versus open-lamina technique[J]. Spine(Phila Pa 1976), 1998, 23(9): 1065-1068.
- [32] Glaser J, Stanley M, Sayre H, et al. A 10-year follow-up evaluation of lumbar spine fusion with pedicle screw fixation[J]. Spine(Phila Pa 1976), 2003, 28(13): 1390-1395.
- [33] Brantigan JW, Neidre A, Toohey JS. The lumbar I/F cage for posterior lumbar interbody fusion with the variable screw placement system: 10-year results of a food and drug administration clinical trial[J]. Spine(Phila Pa 1976), 2004, 4(6): 681-688.

(收稿日期: 2020-08-14 本文编辑: 王宏)