

- nese.
- [15] 矫秀,朱爱青. 血小板/淋巴细胞比值对髋关节炎严重程度预测的分析:横断面研究及预试验结果[J]. 中国组织工程研究, 2018,22(23):3687-3691.
JIAO X,ZHU AQ. Predictive analysis of severity of hip arthritis using platelet-to-lymphocyte ratio: study protocol for a cross-sectional study and preliminary results[J]. Zhongguo Zu Zhi Gong Cheng Yan Jiu, 2018, 22(23):3687-3691. Chinese.
- [16] 顾建明,冯啸,宫丽华,等. 人工全髋关节翻修术患者血清钴铬离子浓度与局部组织病理变化的关系[J]. 骨科临床与研究杂志, 2019,4(1):9-14.
GU JM,FENG X,GONG LH, et al. Correlation between serum cobalt chromium ion concentration and local histopathological ALVAL score of patients after revision total hip arthroplasty[J]. Gu Ke Lin Chuang Yu Yan Jiu Za Zhi, 2019, 4(1):9-14. Chinese.
- [17] 王辉,张涤非,金玉坤,等. 右美托咪定联合椎管内麻醉对老年髋关节置换术围手术期脑损伤、应激激素及 T 淋巴细胞亚群的影响[J]. 海南医学院学报, 2018, 24(17):1582-1586.
WANG H,ZHANG DF,JIN YK, et al. Effects of dexmedetomidine combined with intraspinal anesthesia on perioperative brain injury, stress hormones and T lymphocyte subsets in elderly patients undergoing hip replacement[J]. Hai Nan Yi Xue Yuan Xue Bao, 2018, 24(17):1582-1586. Chinese.
- [18] 周雁,李庭,种皓,等. 加速康复外科中术前糖预处理对患者的影响[J]. 中华创伤骨科杂志, 2018, 20(10):874-882.
ZHOU Y,LI T,ZHONG H, et al. Effect of preoperative carbohydrate treatment on patients in enhanced recovery after surgery[J]. Zhonghua Chuang Shang Gu Ke Za Zhi, 2018, 20(10):874-882. Chinese.
- [19] 汪卫,王勇平. 术前口服碳水化合物对高龄患者髋关节置换术后胰岛素抵抗的影响[J]. 中国医药导报, 2015, 12(4):63-66.
WANG W,WANG YP. Effects of preoperative oral carbohydrate on postoperative insulin resistance in elderly patients undergoing hip arthroplasty[J]. Zhongguo Yi Yao Dao Bao, 2015, 12(4):63-66. Chinese.
- [20] 王晓红,蒲娟,杨智茹,等. 快速康复外科联合心理护理对髋关节置换患者身心健康及康复进程的影响[J]. 中国健康心理学杂志, 2018, 26(11):1702-1706.
WANG XH,PU J,YANG ZR, et al. Effect of FTS combined with psychological nursing on the physical and mental health and rehabilitation process of patients undergoing hip replacement[J]. Zhongguo Jian Kang Xin Li Xue Za Zhi, 2018, 26(11):1702-1706. Chinese.
- [21] 陈旭东,张雯雯,王宏光,等. 术前糖预处理对减轻肝肿瘤切除术后胰岛素抵抗的临床疗效[J]. 解放军医学院学报, 2017, 38(10):950-953.
CHEN XD,ZHANG WW,WANG HG, et al. Clinical effectiveness of preoperative glucose pretreatment on insulin resistance after hepatic tumor resection[J]. Jie Fang Jun Yi Xue Yuan Xue Bao, 2017, 38(10):950-953. Chinese.

(收稿日期:2019-12-14 本文编辑:王玉蔓)

C₃ 扩大半椎板切除单开门椎板成形术治疗多节段颈脊髓压迫症

方明,陆建猛,王兴武,韦勇力,俞武良,陆旻昊

(宁波大学医学院附属医院脊柱外科,浙江 宁波 315000)

【摘要】 目的:探讨 C₃ 扩大半椎板切除单开门椎板成形术治疗多节段颈脊髓压迫症的临床疗效。方法:对 2014 年 9 月至 2018 年 5 月收治的 58 例多节段颈脊髓压迫症患者进行回顾性研究,其中男 34 例,女 24 例;年龄 46~78 岁,平均 64.4 岁;28 例采用 C₃ 扩大半椎板切除 C₄-C₇ 单开门椎板成形术(改良开门组),30 例采用传统后路 C₃-C₇ 单开门椎板成形术治疗(传统开门组)。比较两组患者的手术时间、术中出血、C₅ 神经麻痹及轴性症状(axial symptoms, AS)的发生情况;采用颈椎 MRI 横断面测量 C₃ 节段最狭窄处(包括 C_{3,4} 椎间盘水平)脊髓有效空间(space available for the spinal cord, SAC),评价影像学指标改善情况。观察两组患者手术前后的日本骨科学会(Japanese Orthopaedic Association, JOA)评分、颈部功能障碍指数(Neck Disability Index, NDI),并计算神经功能改善率(RR)。结果:两组患者术后均获得随访,时间 12~18 个月,其中改良开门组平均随访时间为(14.5±1.8)个月,传统开门组为(14.5±1.9)个月,两组比较差异无统计学意义(P>0.05)。两组患者在术中出血、C₅ 神经麻痹方面差异均无统计学意义(P>0.05);但手术时间[(119±10)min VS (126±12)min]、轴性症状发生率[7.1%(2/28) vs 26.6%(8/30)],差异有统计学意义(P<0.05)。改良开门组患者手术前后 C₃ 水平脊髓有效空间分别为(93.61±9.02)mm³和(153.5±12.76)mm³,术后较术前明显扩大(P<0.05);末次随访时改良开门组和传统开门组的 JOA 评分分别为 14.36±1.70 和 14.03±1.82, NDI 评分分别为 10.36±2.55 和 12.47±

通讯作者:陆建猛 E-mail:ningguxiansheng@163.com

Corresponding author: LU Jian-meng E-mail:ningguxiansheng@163.com

3.46, 两组差异有统计学意义 ($P < 0.05$), 但两组神经功能改善率 [(68.36±0.12)% VS (65.01±0.12)%] 比较差异无统计学意义 ($P > 0.05$)。结论: C₃ 扩大半椎板切除单开门椎板成形术不仅能够充分地解除脊髓压迫, 而且通过减少 C₂ 棘突肌肉止点的剥离, 在预防轴性症状等并发症方面亦取得了良好的效果, 是一种治疗多节段颈脊髓压迫症的有效方法。

【关键词】 颈椎; 椎体成形术; 脊髓压迫症

中图分类号: R826.64

DOI: 10.12200/j.issn.1003-0034.2020.08.010

开放科学(资源服务)标识码(OSID):



Analysis of clinical efficacy of C₃ expanded half lamina excision combined with unilateral open-door laminoplasty for multiple segmental cervical spinal cord compression syndrome FANG Ming, LU Jian-meng, WANG Xing-wu, WEI Yong-li, YU Wu-liang, and LU Min-hao. Department of Spinal Surgery, the Hospital Affiliated to Ningbo University Medical College, Ningbo 315000, Zhejiang, China

ABSTRACT Objective: To explore the clinical efficacy of C₃ expanded half lamina excision combined with unilateral open-door laminoplasty for multiple segmental cervical spinal cord compression syndrome. **Methods:** The clinical data of 58 patients with multiple segmental cervical spinal cord compression syndrome underwent surgical treatment between September 2014 and May 2018 were retrospectively analyzed. There were 34 males and 24 females with a mean age of 64.4 years old (ranged from 46 to 78 years old). Among them, 28 cases received the surgery of C₃ expanded half lamina excision combined with C₄-C₇ unilateral open-door laminoplasty (improved group), and 30 cases received a single C₃-C₇ unilateral open-door laminoplasty (traditional group). Operation time, intraoperative blood loss, complications including C₅ nerve root palsy and axial symptoms were compared between two groups. To evaluate the situation of the imaging indicators by measuring the space available for the spinal cord through cross-sectional MRI of cervical spine at the narrowest segment of C₃ (including intervertebral disc levels of C_{3,4}). Pre-and post-operative Japanese Orthopedic Association (JOA) score, Neck Disability Index (NDI) score, and improvement rate of neurological function, were recorded and analyzed between the two groups. **Results:** All the patients were followed up for 12 to 18 months with an average of (14.5±1.8) months for improved group and (14.5±1.9) months for traditional group, and no significant difference was found between the two groups ($P > 0.05$). There was no significant difference in intraoperative blood loss and C₅ nerve root palsy between the two groups ($P > 0.05$). The operation time (119±10) min vs (126±12) min and axial symptoms 7.1% (2/28) vs 26.6% (8/30) was significant difference between the two groups ($P < 0.05$). Preoperative and postoperative space available for the spinal cord of C₃ was (93.61±9.02) mm³ and (153.50±12.76) mm³ respectively, which was obtained obvious improvement in all patients ($P < 0.05$). At the final follow-up, JOA scores of improved group and traditional group were 14.36±1.70 and 14.03±1.82 respectively, and NDI scores were 10.36±2.55 and 12.47±3.46 respectively, there was significant difference between two groups ($P < 0.05$). However, there was no significant difference between two groups for the improvement rate (68.36±0.12)% VS (65.01±0.12)% of neurological function ($P > 0.05$). **Conclusion:** C₃ expanded half lamina excision combined with unilateral open-door laminoplasty is an effective method to treat multiple segmental cervical spinal cord compression syndrome, for it can not only fully relieved spinal cord compression, but also achieved good effect in preventing complications such as axial symptoms by reducing stripping of muscles from C₂ spinous process.

KEYWORDS Cervical vertebrae; Vertebroplasty; Spinal cord compression

颈椎后路单开门椎板成形术因操作简便安全, 近、远期疗效肯定, 已被广泛应用于临床。但部分患者术后出现了颈肩背部酸胀疼痛或僵硬、沉重等不适, 这些症状被称为轴性症状(axial symptoms, AS), 发生率 5.2%~80%, 严重时会影响患者的生活和工作。为此, 许多学者通过改良手术方案以降低轴性症状, 如保留 C₂ 和 C₇ 棘突附着肌肉、选择钢板固定椎板、控制开门角度、减少术后颈托佩戴时间、早期进行功能锻炼等, 以期减少轴性症状的发生。有文献报道^[1]C₃ 椎板切除联合椎板成形术在获得良好神经减压的同时, 可以维持颈后伸肌结构功能的完整性, 从而减少轴性症状的发生率。本文通过对 C₃ 椎板处理进行改良, 回顾性分析 2014 年 9 月至 2018 年 5 月收治的 58 例多节段颈脊髓压迫症患者, 探讨 C₃ 扩

大半椎板切除单开门椎板成形术治疗多节段颈脊髓压迫症的临床疗效与优势。

1 资料与方法

1.1 病例选择

病例均来自 2014 年 9 月至 2018 年 5 月在宁波大学医学院附属医院骨科住院行颈椎后路椎板成形术的患者。纳入标准: (1)影像学(CT、MRI)检查明确脊髓受累的颈椎病、颈椎管狭窄或后纵韧带骨化症, 其病变范围 ≥ 3 个节段且位于 C₃-C₇。(2)与脊髓压迫相符的症状和体征。(3)由同一位医师完成。排除标准: (1)病例资料不完整。(2)外伤、肿瘤、畸形等原因所致的颈髓受损。(3)过伸位颈椎曲度不良者。

1.2 一般资料

本组 58 例, 男 34 例, 女 24 例; 年龄 46~78 岁,

平均 64.4 岁;病程 3~35 个月,平均 14.1 个月;28 例采用 C₃ 扩大半椎板切除单开门椎板成形术(改良开门组),30 例采用传统后路单开门椎板成形术(传统开门组)。两组患者一般资料的比较差异无统计学意义($P>0.05$),见表 1。

1.3 治疗方法

1.3.1 C₃ 扩大半椎板切除单开门椎板成形术(改良开门组) 全麻后,患者俯卧位将颈椎维持在略屈曲位,消毒铺巾,取 C₂-T₁ 后正中纵行切口,逐层切开皮肤及皮下组织。保留 C₂ 棘突肌肉止点,C₃-C₇ 沿着棘突两侧钝性骨膜下剥离椎旁肌至颈椎关节突,C₃ 非减压侧可适当减少剥离范围,修剪 C₄-C₇ 棘突,术中感受颈椎稳定性,若存在不稳节段,予侧块螺钉固定,10 号丝线穿棘突备用;去除 C₃ 减压侧部分棘突及基底骨质,保留内侧皮质骨,门轴侧去除 C₄-C₇ 外侧骨质,再于开门侧去除 C₃-C₇ 双层骨皮质,将 C₄-C₇ 椎板向门轴侧掀开。颈椎管扩大至硬膜囊膨胀足够,用强生公司微型钛板将开门侧侧块与椎板固定,并拧入螺钉,不稳节段的椎板则用丝线固定于侧块螺钉内固定上。再用枪状咬骨钳切除开门侧 C₃ 半椎板、棘突基底部、C_{3,4} 黄韧带,术中根据减压情况决定潜行减压范围。止血冲洗后,留置 2 根引流管,逐层关闭切口。C₃ 椎板处理见图 1。

1.3.2 传统后路单开门椎板成形术治疗(传统开门组) 采取全麻,除 C₃ 行单开门椎板成形,其他节段开门减压及固定方式同改良开门组。

1.3.3 术后处理 术后果引流情况 1~3 d 拔除引流管,术后 3 d 颈托保护下地活动,颈托佩戴 8 周左右,在医师指导下循序渐加强主动功能锻炼。术后 2 周内行 X 线和 MRI、CT 检查。

1.4 观察项目与方法

(1)一般情况观察:观察手术时间、术中出血、C₅ 神经麻痹及轴性症状的发生情况。(2)临床疗效观察:通过日本骨科协会(Japanese Orthopedic Association,JOA)17 分法对手术前后神经功能进行评分,并计算神经功能改善率(RR), $RR=[(术后分-术前分)/(17-术前分)]\times 100\%$;根据颈椎功能障碍指数量表(Neck Disability Index,NDI)对患者神经功能改善情况进行评定;应用 image-pro plus 6.0 软件测量手术前后颈椎 MRI 横断面 C₃ 水平最狭窄处脊髓有效空间(包括 C₃₋₄ 椎间盘水平)。

1.5 统计学处理

采用 SPSS 17.0 软件进行统计分析,定量资料用均数±标准差($\bar{x}\pm s$)表示,两组手术前后数据比较采用配对 *t* 检验,两组间比较采用独立样本 *t* 检验;计数资料采用 χ^2 检验;以 $P<0.05$ 为差异有统计学意义。

表 1 两组颈椎患者一般资料比较

Tab.1 Comparison of general data of patients with cervical spondylosis between two groups

组别	例数	性别(例)		年龄($\bar{x}\pm s$,岁)	病变节段(例)		病程($\bar{x}\pm s$,月)	随访时间($\bar{x}\pm s$,月)
		男	女		3个	4个		
改良开门组	28	17	11	64.5±9.2	13	15	14.0±9.1	14.5±1.8
传统开门组	30	17	13	64.3±7.9	14	16	14.1±8.8	14.5±1.9
检验值		$\chi^2=0.09$		$t=0.12$	$\chi^2=0.00$		$t=0.05$	$t=0.13$
P值		0.75		0.90	0.98		0.95	0.89

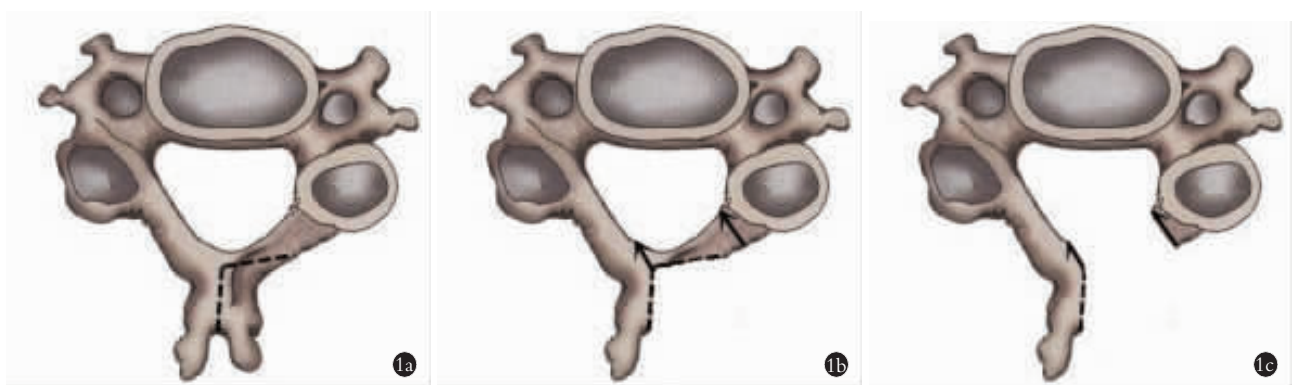


图 1 改良开门组 C₃ 椎板处理流程 1a. 沿虚线处去除部分棘突及基底骨质,保留内侧皮质骨 1b. 沿箭头方向去除半椎板及部分棘突基底部骨质 1c. 减压后形状

Fig.1 Treatment process of C₃ lamina in improved group 1a. Part of spinous process and basal bone were removed along the dotted line, while medial cortical bone was retained 1b. The semi-lamina and part of the basal bone were removed along the direction of the arrow 1c. The shape after decompression

2 结果

2.1 一般情况观察结果

本组患者手术顺利,术中均无硬膜、脊髓、神经根损伤,术后均未出现伤口感染。两组术中出血量及 C₅ 神经麻痹方面比较差异无统计学意义 ($P>0.05$),但手术时间比较差异有统计学意义 ($P<0.05$);两组均有轴性症状出现,改良开门组发生率低于传统单开门组 (7.1% vs 26.6%),经对症治疗后症状均消失 (见表 2)。改良开门组患者手术前后 C₃ 有效脊髓空间分别为 $(93.61 \pm 9.02) \text{ mm}^3$ 和 $(153.5 \pm 12.76) \text{ mm}^3$,术后较术前明显扩大 ($t=61.42, P<0.05$)。

2.2 临床疗效评定结果

两组患者术后均获得随访,时间 12~18 (14.5 ± 1.8) 个月。术前及末次随访 JOA 评分改良开门组分别为 9.29 ± 2.15 和 14.36 ± 1.70 ,传统开门组分别为 9.10 ± 2.26 和 14.03 ± 1.82 ,末次随访时两组患者 JOA 评分较术前均明显提高 ($t=26.41$ 和 $24.29, P<0.05$),改良开门组和传统开门组改善率分别为 $(68.36 \pm 0.12)\%$ 和 $(65.01 \pm 0.12)\%$,组间比较差异无统计学意义 ($t=0.99, P>0.05$)。通过 NDI 对神经功能改善进行评估,末次随访时 NDI 评分改良开门组 (10.36 ± 2.55) 较传统开门组 (12.47 ± 3.46) 改善更为明显 ($t=2.62, P<0.05$)。典型病例手术前后影像学资料见图 2。

3 讨论

3.1 颈椎后路椎板成形术颈部肌肉损伤与轴性症状的关系

颈椎后路椎板成形术是目前治疗多节段脊髓压迫症主要手段之一,其近、远期疗效肯定,但随之发生的某些手术并发症仍不可避免,如轴性症状。尽管许多学者对轴性症状发生的机制及预防做了大量的研究,但其发生机制复杂,至今尚无统一的认识。既往研究轴性症状发生率存在较大的差异,多数患者症状可在 3~6 个月后得到不同程度的缓解,但也有持续长达 10 年之久的病例。术后早期颈痛应与轴性疼痛相鉴别,后者分布较广,持续时间较长,对症治疗效果欠佳。为避免手术肌肉损伤和切口相关性疼痛的影响,本组患者均未进行术后早期的功能评估。

Mori 等^[2]发现轴性症状中常见的是僵硬,其次才是疼痛。本研究借鉴 Hosono 等^[3]对轴性症状分为轻、中、重 3 个等级,其中中、重度合称为轴性症状,这一更为准确的分类方法被多项研究^[4-5]所采用。Kato 等^[6]发现保留附着于 C₂ 和 C₇ 上的肌肉能显著减少轴性痛的发生率。Fujibayashi 等^[7]指出术后颈部肌力大小与轴性症状发生相关。以往研究表明 C₂ 棘突是颈半棘肌最重要的止点,对保持正常颈椎生理曲度及维持颈椎后方张力起着重要作用。当手术破坏颈半棘肌的止点,为维持平衡,颈后肌群会代偿性持续收缩和缩短作用力臂,最终发生疲劳、疼痛,引起颈项部的僵硬、疼痛等轴性症状。C₇ 棘突是项韧带的止点,同时也是小菱形肌和斜方肌的起点,是颈后肌肉韧带复合体的重要组成部分,多项回顾性研究^[8-10]也证实保留 C₇ 棘突能降低术后轴性症状的发生率。

3.2 C₃ 扩大半椎板切除单开门椎板成形术治疗多节段颈脊髓压迫症的疗效

C₃ 扩大半椎板切除单开门椎板成形术基于传统椎板成形术,仅通过对 C₃ 椎板处理进行改良,达到治疗多节段颈脊髓压迫症的目的。颈椎手术脊髓减压效果最为重要,本研究对两种术式的临床疗效进行对比,观察两组患者术后 JOA 评分的改善情况,结果提示术后 JOA 评分较术前均明显提高 ($P<0.05$),但两组改善率比较差异无统计学意义 ($P>0.05$),故在脊髓症状的缓解上疗效相当。采用颈椎 MRI 横断面测量 C₃ 节段最狭窄处脊髓有效空间的改善情况,术后结果提示改良开门组病例较术前明显扩大 ($P<0.05$),虽然容积增大无法跟传统开门组相比,但足以满足脊髓的减压,且在一定程度上限制了脊髓过度后移;国内有研究^[11]认为术前脊髓受压率、颈椎生理曲度及术后脊髓漂移程度与轴性症状发生相关,其中术后脊髓漂移程度是轴性症状发生的高危因素。两组在术中出血、C₅ 神经根麻痹方面效果相当,但手术时间改良开门组较传统开门组短,这可能与前者较后者减少了 C_{2,3} 的肌肉剥离,避免了此处的静脉丛出血,以及减少了 C₃ 椎板固定的时间有关。另外,改良开门组无须剥离 C₂ 棘突附着肌肉,

表 2 两组颈椎患者手术一般情况观察结果

Tab.2 Comparison of general operative conditons of patients with cervical spondylosis between two groups

组别	例数	手术时间 ($\bar{x} \pm s, \text{min}$)	术中出血 ($\bar{x} \pm s, \text{ml}$)	C ₅ 神经麻痹 (例)		轴性症状 (例)	
				无	有	无	有
改良开门组	28	119±10	172±56	27	1	26	2
传统开门组	30	126±12	199±65	29	1	22	8
检验值		$t=2.40$	$t=1.66$	$\chi^2=0.00$		$\chi^2=3.86$	
P 值		0.02	0.10	0.96		0.04	

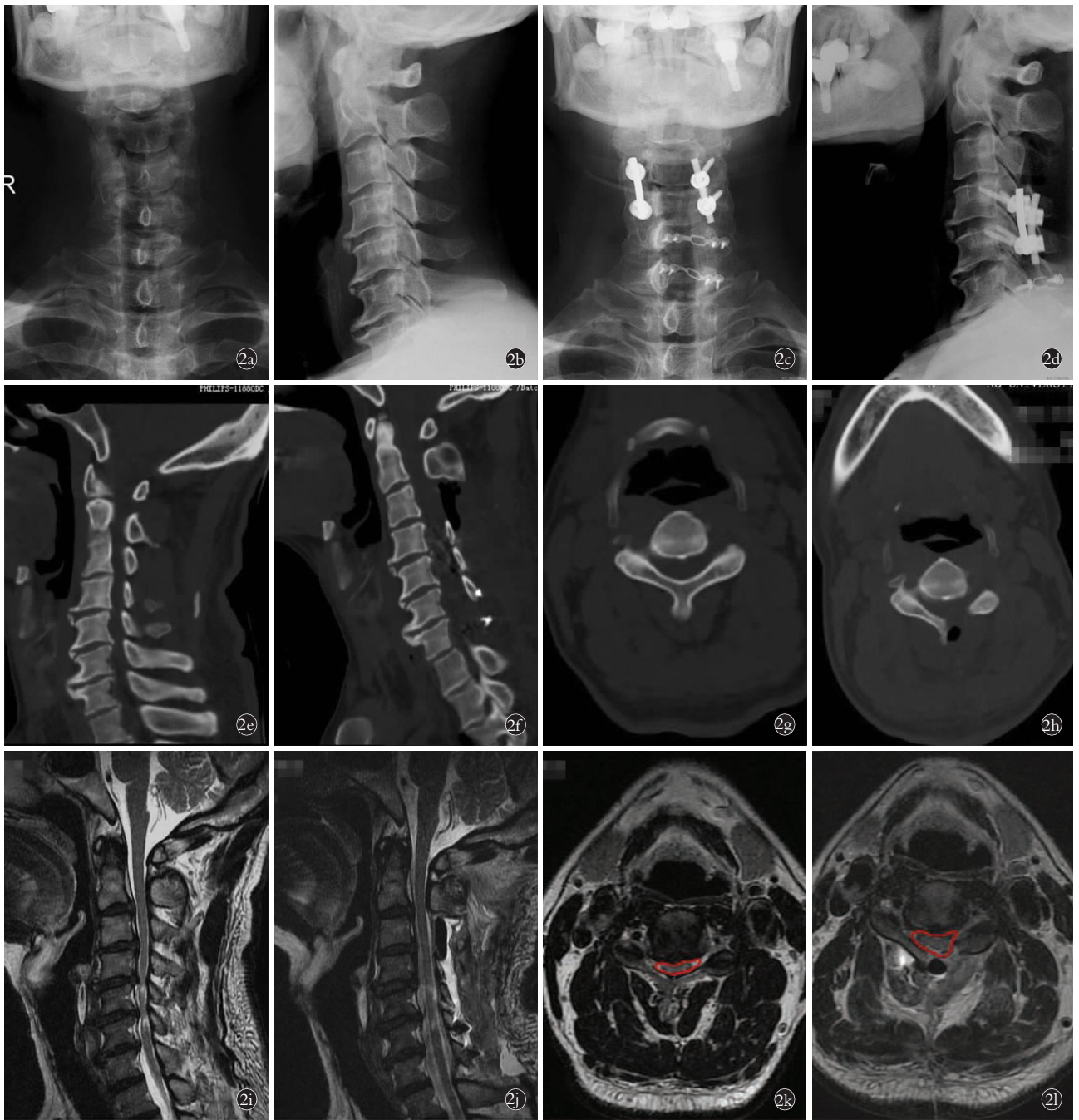


图 2 患者,男,61 岁,脊髓型颈椎病合并发育性颈椎管狭窄,行 C₃ 扩大半椎板切除单开门椎板成形术治疗 **2a,2b.** 术前颈椎正侧位 X 线片示颈椎增生、曲度变直 **2c,2d.** 术后 1 周颈椎正侧位 X 线片可见内固定影 **2e, 2f.** 术后 1 周颈椎 CT 矢状位重建示颈椎管较术前明显增大 **2g,2h.** 手术前后 C₃ 水平最狭窄处 CT 横断面平扫可见扩大半椎板切除后改变 **2i.** 术前 1 周颈椎 MRI 矢状位显示 C₃-C₇ 椎管狭窄,脊髓受压 **2j.** 术后 10 d 颈椎 MRI 矢状位显示颈脊髓减压良好 **2k.** 术前 1 周颈椎 MRI C₃ 水平最狭窄处横断面示椎管狭窄 **2l.** 术后 10 d 颈椎 MRI 示 C₃ 水平最狭窄处横断面可见椎管扩大

Fig.2 A 61-year-old male patient with cervical spondylosis myelopathy and developmental stenosis of cervical spine underwent C₃ expanded half lamina excision combined with unilateral open-door laminoplasty **2a,2b.** Preoperative AP and lateral X-rays of cervical spine showed cervical hyperplasia and curvature straighten **2c,2d.** AP and lateral X-rays of cervical spine showed internal fixation at one week after operation **2e, 2f.** Sagittal CT reconstruction of cervical spine showed the cervical spinal canal enlarged obviously at one week after operation **2g, 2h.** Preoperative and postoperative CT scan was performed at the narrowest C₃ level showed the change after expanded half lamina excision **2i.** Sagittal imaging of MRI showed spinal stenosis on C₃-C₇ and spinal cord compression at one week before surgery **2j.** Cervical sagittal imaging of MR showed spinal cord decompression completely at ten days after operation **2k.** Cross-sectional MRI of C₃ level at the narrowest place showed spinal canal stenosis one week before surgery **2l.** Cross-sectional MRI of C₃ level at the narrowest place showed spinal canal enlarged at ten days after operation

减少了主要颈椎后伸肌的剥离，有效减少了手术创伤及轴性症状的发生。在通过颈椎功能障碍指数量表对两组患者进行各项目评分中发现，术后两组患者颈椎功能较术前均有不同程度缓解，末次随访时改良开门组较传统开门组改善更为明显($P<0.05$)，表明改良开门组能够更好地提高患者的生活质量。椎板成形术最重要的是保留了颈椎后部结构的稳定性，包括静态稳定系统和动态稳定系统(颈部后伸肌群的调控)。其中起于胸椎横突的颈半棘肌，大部分止于 C₂ 棘突，是维持颈椎动态稳定最重要的结构。在行 C₃ 单开门的时候，颈半棘肌在 C₂ 棘突上的附着点需部分或完全剥离，是导致颈椎曲度丢失的部分原因。研究^[12]显示颈后路椎板成形术从 C₄ 开始较 C₃ 开始可以少丢失颈椎曲度。既往研究^[13-15]发现切断或剥离用于维持颈椎生理前凸的颈半棘肌，术后容易出现轴性症状和颈椎曲度丢失。

3.3 C₃ 扩大半椎板切除减压注意事项

改良 C₃ 扩大半椎板切除椎板成形术，术中无须剥离 C₂ 棘突附着肌肉，同时尽量减少非减压侧 C₃ 椎板附着肌肉的剥离；多节段颈脊髓压迫症患者往往累及 C₃ 节段，尤其多见于 C_{3,4} 椎间盘水平，因此对于 C₃ 节段能否有效减压至关重要。为达到有效减压，C₃ 扩大半椎板切除须包括 C₃ 半椎板、减压侧部分棘突，潜行去除 C₃ 棘突基底部分骨质，C_{3,4} 大部分黄韧带以及部分骨板，术中探查脊髓减压情况酌情增加去除 C₃ 基底部骨质，以及是否潜行减压 C_{2,3} 黄韧带及椎板。

总之，C₃ 扩大半椎板切除单开门椎板成形术治疗多节段颈脊髓压迫症的疗效肯定，在充分解除脊髓压迫的同时，有效减少了轴性症状等并发症的发生。本研究为回顾性研究，纳入的患者数量较少，资料收集有所限制，可能会造成研究的偏倚。

参考文献

[1] 张为,陈百成,申勇,等. C₃ 椎板切除单开门成形术对颈椎轴性症状的影响[J]. 中华骨科杂志, 2006, 26(8): 544-548.
ZHANG W, CHEN BC, SHEN Y, et al. Impact on cervical axial symptom of modified open-door laminoplasty with C₃ laminectomy [J]. Zhonghua Gu Ke Za Zhi, 2006, 26(8): 544-548. Chinese.

[2] Mori E, Ueta T, Maeda T, et al. Effect of preservation of the C₆ spinous process and its paraspinal muscular attachment on the pre-

vention of postoperative axial neck pain in C₃₋₆ laminoplasty [J]. J Neurosurg Spine, 2015, 22(3): 221-229.

[3] Hosono N, Sakaura H, Mukai Y, et al. The source of axial pain after cervical laminoplasty-C₇ is more crucial than deep extensor muscles [J]. Spine (Phila Pa 1976), 2007, 32(26): 2985-2988.

[4] Takeuchi K, Yokoyama T, Aburakawa S, et al. Axial symptoms after cervical laminoplasty with C₃ laminectomy compared with conventional C₃-C₇ laminoplasty: a modified laminoplasty preserving the semispinalis cervicis inserted into axis [J]. Spine (Phila Pa 1976), 2005, 30(22): 2544-2549.

[5] Tsuji T, Asazuma T, Masuoka K, et al. Retrospective cohort study between selective and standard C₃₋₇ laminoplasty. Minimum 2-year follow-up study [J]. Eur Spine J, 2007, 16(12): 2072-2077.

[6] Kato M, Nakamura H, Konishi S, et al. Effect of preserving paraspinal muscles on postoperative axial pain in the selective cervical laminoplasty [J]. Spine (Phila Pa 1976), 2008, 33(14): E455-E459.

[7] Fujibayashi S, Neo M, Yoshida M, et al. Neck muscle strength before and after cervical laminoplasty: relation to axial symptoms [J]. J Spinal Disord Tech, 2010, 23(3): 197-202.

[8] Skaura H, Hosono N, Mukai Y, et al. Medium-term outcomes of C₃₋₆ laminoplasty for cervical myelopathy: a prospective study with a minimum 5-year follow-up [J]. Eur Spine J, 2011, 20(6): 928-933.

[9] Kowatari K, Ueyama K, Sannohe A, et al. Preserving the C₇ spinous process with its muscles attached: effect on axial symptoms after cervical laminoplasty [J]. J Orthop Sci, 2009, 14(3): 279-284.

[10] Cho CB, Chough CK, Oh JY, et al. Axial neck pain after cervical laminoplasty [J]. Korean Neurosurg Soc, 2010, 47(2): 107-111.

[11] 朱小龙,徐卫星,丁伟国,等. 颈椎单开门椎板成形术后轴性症状的影响因素分析[J]. 中国骨伤, 2018, 31(11): 1022-1026.
ZHU XL, XU WX, DING WG, et al. Analysis of influencing factors the postoperative axial symptoms of cervical single open-door laminoplasty [J]. Zhongguo Gu Shang/China J Orthop Trauma, 2018, 31(11): 1022-1026. Chinese with abstract in English.

[12] Michael KW, Neustein TM, Rhee JM. Where should a laminoplasty start The effect of the proximal level on post-laminoplasty loss of lordosis [J]. Spine J, 2016, 16(6): 737-741.

[13] Lizuka H, Shimizu T, Tateno K, et al. Extensor musculature of the cervical spine after laminoplasty: morphologic evaluation by coronal view of the magnetic resonance image [J]. Spine (Phila Pa 1976), 2001, 26(20): 2220-2226.

[14] Takeshita K, Scichi A, Akmc T, et al. Can laminoplasty maintain the cervical Alignment even when the C₂ lamina is contained [J]. Spine (Phila Pa 1976), 2005, 30(11): 1294-1298.

[15] Schomacher J, Petzke F, Falla D, et al. Localised resistance selectively activates the semispinalis cervicis muscle in patients with neck pain [J]. Man Ther, 2012, 17(6): 544-548.

(收稿日期: 2020-01-14 本文编辑: 王宏)