

单节段胸腰椎Ⅲ期 Kümmell 病短节段和长节段强化固定的临床比较研究

邓轩赓,熊小明,万夏,石华刚,崔伟,陈星,梅国龙,宋偲茂,侯伟
(四川省骨科医院,四川 成都 610041)

【摘要】 目的:比较单节段胸腰椎Ⅲ期 Kümmell 病短节段和长节段固定的临床疗效,探讨更适宜的固定节段。方法:对 2013 年 7 月至 2016 年 12 月收治的 46 例单节段胸腰椎Ⅲ期 Kümmell 病患者的临床资料进行回顾性分析,46 例患者因不同的骨水泥钉棒固定方法分为短节段固定组(病椎上下各 1 椎)和长节段固定组(病椎上下各 2 椎)。其中短节段固定组 25 例,男 9 例,女 16 例,年龄(75.3±4.5)岁,腰椎骨密度 T 值(-3.1±0.3) g/cm³,随访时间(13.0±2.3)个月;长节段固定组 21 例,男 6 例,女 15 例,年龄(74.5±3.9)岁,腰椎骨密度 T 值(-3.2±0.3) g/cm³,随访时间(14.7±3.6)个月。比较两组患者的性别、年龄、随访时间、手术时间、术中出血量、骨水泥渗漏、邻椎骨折率,以及手术前后的疼痛 VAS 评分、ODI、后凸角变化。结果:术前两组患者年龄、性别、骨密度、疼痛 VAS 评分、ODI、后凸角比较差异无统计学意义,手术时间及术中出血量短节段固定组少于长节段固定组,术后 7 d 及末次随访时两组患者的疼痛 VAS 评分、ODI、后凸角较术前均有显著改善,组间比较差异无统计学意义。两组骨水泥渗漏(9/25 vs 11/21)及邻椎骨折发生(4/25 vs 3/21)差异无统计学意义。结论:长短节段固定均可有效缓解疼痛、纠正后凸、提高功能指数,取得较好临床疗效,但短节段骨水泥钉棒固定手术时间更短、术中出血更少,因此对于胸腰椎单节段Ⅲ期 Kümmell 病无需延长固定节段,短节段固定更符合临床需要,值得进一步研究。

【关键词】 Kümmell 病; 内固定; 椎体强化

中图分类号:R683.2

DOI: 10.3969/j.issn.1003-0034.2019.07.003

开放科学(资源服务)标识码(OSID):



Clinical comparative study of short-segment and long-segment fixation for single-segment thoracic and lumbar spine III stage Kümmell disease DENG Xuan-geng, XIONG Xiao-ming, WAN Dun, SHI Hua-gang, CUI Wei, CHEN Xing, MEI Guo-long, SONG Si-mao, and HOU Wei. Sichuan Orthopedic Hospital, Chengdu 610041, Sichuan, China

ABSTRACT Objective: By comparing the clinical efficacy of short-segment and long-segment fixation for single-segment thoracic and lumbar spine III stage Kümmell disease to explore a more suitable fixed segment for the disease. **Methods:** The clinical data of 46 patients with single-segment thoracic and lumbar spine III stage Kümmell disease treated from July 2013 to December 2016 were retrospectively analyzed. Forty-six patients were divided into short-segment fixation group (one vertebra above and below the diseased vertebra) and long-segment fixation group (two vertebrae on the upper and lower of the diseased vertebra) according to different methods of cement stick fixation. There were 25 patients in the short-segment fixation group, including 9 males and 16 females, with an average age of (75.3±4.5) years old, lumbar spine bone mineral density T-value of (-3.1±0.3) g/cm³, follow-up time of (13.0±2.3) months; there were 21 patients in long-segment fixation group, 6 males and 15 females, with an average age of (74.5±3.9) years old, lumbar spine bone mineral density T-value of (-3.2±0.3) g/cm³, follow-up time of (14.7±3.6) months. The gender, age, follow-up time, operation time, intraoperative blood loss, cement leakage, and the rate of adjacent vertebrae fractures were compared between two groups, as well as pain VAS score, ODI, and kyphosis angle before and after surgery. **Results:** There were no significant differences in age, gender, bone density, pain VAS score, ODI, and kyphosis between two groups before surgery. The operation time and intraoperative blood loss of short-segment fixation group were less than that of long-segment fixation group. The pain VAS score, ODI and kyphosis of the two groups were significantly improved at 7 days after the operation and at the latest follow-up, there was no significant difference between two groups. There were no significant differences in bone cement leakage (9/25 vs 11/21) and adjacent vertebrae fractures (4/25 vs 3/21). **Conclusion:** Both long-segment fixation and short-segment fixation can effectively relieve pain, correct kyphosis, improve func-

基金项目:四川省干部保健课题(编号:2018-612)

Fund program: Health Care for Cadres in Sichuan Province(No.2018-612)

通讯作者:邓轩赓 E-mail:tigerd@163.com

Corresponding author: DENG Xuan-geng E-mail:tigerd@163.com

tional index, and achieve better clinical results, but short-segment fixation has less operation time and less intraoperative blood. So single-segment thoracic and lumbar spine III stage Kümmell disease does not need to extend the fixed segment, short-segment fixation is more in line with clinical needs and worthy of further study.

KEYWORDS Kümmell disease; Internal fixation; Vertebral strengthening

Kümmell 病主要影像特征为椎体裂隙征, 椎体内骨质部分坏死或吸收, 裂隙内为液体或气体所占据^[1], 常常预示骨不愈合^[2], 多需个体化手术治疗^[3]。对于 Li 分期 III 期 Kümmell 病^[4]因残留骨质较少且因椎体后壁破裂、椎管占位, 常合并后凸需矢状位重建^[5], 内固定最大技术障碍就在于骨质疏松可能导致的内固定不稳定, 可以通过延长节段或骨水泥强化来获得固定稳定性。通过骨水泥强化钉棒固定是目前可靠的手术方式^[6], 但固定节段尚不明确, 目前无文献研究比较 III 期 Kümmell 病长短节段强化固定的临床疗效差异。本研究对 2013 年 7 月至 2016 年 12 月收治的且随访资料完整的 46 例胸腰单椎体 III 期 Kümmell 病进行回顾性分析, 聚焦于单椎体 III 期 Kümmell 病长节段和短节段强化固定临床疗效比较, 探索更适宜的手术治疗方案。

1 资料与方法

1.1 临床资料

本组 46 例, 术前腰椎骨密度 (Bone Mineral Density, BMD) T 值 > -4.0 g/cm³, 诊断标准同文献^[4]。采用短节段固定 (伤椎上下各 1 椎) 25 例 (短节段固定组), 长节段固定 (伤椎上下各 2 椎) 21 例 (长节段固定组)。

短节段固定组 25 例中 T₁₀-L₂ 节段 23 例, T₁₀ 以上 2 例, 随访时间 (13.0±2.3) 个月 (95% 可信区间 12.1~14.0 个月), 男 9 例, 女 16 例, 年龄 (75.3±4.5) 岁 (95% 可信区间 73.5~77.1 岁), 腰椎 BMD 检查 T 值 (-3.1±0.3) g/cm³。长节段固定组 21 例均为 T₁₀-L₂ 节段, 男 6 例, 女 15 例, 年龄 (74.5±3.9) 岁 (95% 可信区间 72.8~76.3 岁), 腰椎 BMD 平均 T 值 (-3.2±0.3) g/cm³, 随访时间 (14.7±3.6) 个月 (95% 可信区间 13.0~16.3 个月)。共同临床表现为疼痛以及因疼痛所致的活动受限, 另有 5 例站立位有双下肢

麻木和 (或) 无力感, 平卧休息症状可缓解 (短节段 3 例, 长节段 2 例)。两组胸腰单椎体 III 期 Kümmell 病患者一般资料比较差异无统计学意义 (见表 1)。

1.2 治疗方法

全麻, 手术入路为脊中线入路, 骨膜下剥离椎旁肌肉。短节段固定组固定节段为病椎上下各 1 个正常椎体, 长节段固定组固定节段为病椎上下各 2 个正常椎体。分别经椎弓根置入中空且前方带侧孔的骨水泥螺钉 (万向 "U" 形单芯椎弓钉)。短节段固定组病椎如椎弓根完整则同样置入骨水泥螺钉, 如椎弓根细小置钉困难则不置钉; 长节段固定组病椎均不置钉。置钉椎体强化通过中空骨水泥螺钉完成, 骨水泥 (可注射型骨水泥 III 型) 在牙膏期前推注, 干结前可继续旋入 1~2 丝以切断螺钉内外骨水泥联结。病椎未置钉的则在钉棒固定后通过椎体成形术强化椎体。

所有病例采用同种异体椎板、关节突间植骨融合, 椎管占位病例未行椎管减压。术后应用抗生素 48 h, 2~3 d 拔出引流管后在支具保护下下床活动, 术后 5~7 d 切口无异常后出院, 佩戴支具保护时间 3 个月, 骨质疏松治疗同指南^[7]。

1.3 观察项目与方法

观察两组患者的一般情况, 包括手术时间、术中出血量、治疗费用、术中骨水泥渗漏等情况, 比较术前、出院前 (术后 7 d) 及末次随访时的疼痛视觉模拟评分 (visual analogue scale, VAS), 伤椎上下 Cobb 角, Oswestry 功能障碍指数 (Oswestry Disability Index, ODI), 邻椎骨折 (adjacent vertebra fracture, AVF) 等情况。

1.4 统计学处理

采用 SPSS 22.0 统计软件进行统计学处理。两组患者年龄、术前骨密度、手术时间、术中出血量、治疗

表 1 两组胸腰单椎体 III 期 Kümmell 病患者一般资料比较

Tab.1 Comparison of general data of patients with single-segment thoracic and lumbar spine III stage Kümmell disease between two groups

组别	例数	性别 (例)		年龄 (x±s, 岁)	术前骨密度 (x±s, g/cm ³)	随访时间 (x±s, 月)
		男	女			
短节段固定组	25	9	16	75.3±4.5	-3.1±0.3	13.0±2.3
长节段固定组	21	6	15	74.5±3.9	-3.2±0.3	14.7±3.6
检验值		Z=-0.529		t=0.599	t=-0.701	t=-1.605
P 值		0.596		0.522	0.487	0.116

费用、随访时间、VAS 评分、ODI、Cobb 角等定量资料采用两独立样本 *t* 检验,计数资料如性别、骨水泥渗漏、邻椎骨折等采用非参数检验两独立样本 Mann-Whitney *U* 检验,VAS、ODI、Cobb 角组内术前与末次随访比较采用自身配对 *t* 检验,VAS、Cobb 角不同时间值比较采用一般线性模型重复测量法检验,双侧检验以 *P*<0.05 为差异有统计学意义。

2 结果

因病例延续期间内固定、医疗价格调整等因素,医疗费用计算基准不同,不一致性增加,未比较实际费用,同等情况下,长节段组较短节段组多出 2~4 枚螺钉和额外骨水泥的费用,费用差额 0.5~1 万。短节段固定组有 1 例病椎因置钉困难未置入椎弓根螺钉,长节段固定组有 1 例因切口局部脂肪液化愈合不良经清创缝合后延期 1 周出院。

两组患者手术时间、术中出血量、骨水泥渗漏、邻近椎体骨折情况见表 2。手术时间和术中出血量短节段固定组小于长节段固定组,但两组间术中骨水泥渗漏、邻椎骨折差异无统计学意义。除早期短节段固定组 1 例骨水泥肺栓塞外(高热、低氧血症,对症支持后缓解),其余渗漏均无症状,主要为椎体周围渗漏。邻椎骨折短节段固定组 4 例中 2 例接受了经皮椎体成形术(percutaneous vertebroplasty, PVP)治疗,2 例选择了非手术治疗。长节段固定组 3 例邻椎骨折 2 例选择 PVP 手术,1 例选择经皮后凸成形术

(percutaneous kyphoplasty, PKP)治疗。

随访期内两组均未出现内固定失效病例,术后 VAS、ODI 评分及 Cobb 角均有改善,组间比较差异无统计学意义(见表 3)。典型病例手术前后的影像学资料见图 1、2。

3 讨论

3.1 手术方式

对于 Kümmell 病治疗,文献报道较多。I 期及部分 II 期^[5],行 PVP 或 PKP 即可。也有作者报道了 PKP 治疗 III 期 Kümmell 病疗效满意^[8],对于单节段无神经损害的 Kümmell 病,还有作者比较了 PKP 和 PVP+后路固定(无融合,钉道无强化)疗效,经 2 年随访均安全有效,PKP 有更短的手术时间、更少的出血及并发症^[9]。

尽管如此,无论 PKP 还是 PVP 取得疗效的前提是骨水泥能与周围骨质有效“锚合”。对于 III 期 Kümmell 病,椎体骨折吸收或破坏较多,甚至椎体前方仅剩下上下终板,残留骨质与骨水泥难以有效锚定,可出现骨水泥块移位等情况^[10],或者稳定性无法有效重建^[11],配合内固定治疗可能更为可靠。

力学研究表明良好的骨小梁质量有助于后路螺钉的坚强固定,骨质疏松将增加内固定的失败率^[12],而临床常见 Kümmell 病患者常伴较重的骨质疏松^[1]。提高螺钉固定的稳定性,膨胀螺钉是一个选择^[13],但膨胀螺钉的稳定性取决于椎体内骨质对螺

表 2 两组胸腰单椎体 III 期 Kümmell 病患者手术时间、术中出血量、骨水泥渗漏、邻椎骨折情况

Tab.2 Comparison of operation time, intraoperative blood loss, bone cement leakage, adjacent vertebral fracture between two groups with single-segment thoracic and lumbar spine III stage Kümmell disease

组别	例数	手术时间($\bar{x}\pm s$, min)	术中出血量($\bar{x}\pm s$, ml)	骨水泥渗漏(例)	邻椎骨折(例)
短节段固定组	25	138.7±12.5	251.9±39.4	9	4
长节段固定组	21	166.5±10.1	336.0±41.9	11	3
检验值		<i>t</i> =-8.112	<i>t</i> =-6.984	<i>Z</i> =-1.104	<i>Z</i> =-0.159
<i>P</i> 值		0.000	0.000	0.270	0.873

表 3 两组胸腰单椎体 III 期 Kümmell 病患者 VAS, ODI, Cobb 比较 ($\bar{x}\pm s$)

Tab.3 Comparison of VAS, ODI, Cobb angle of patients with single-segment thoracic and lumbar spine III stage Kümmell disease between two groups($\bar{x}\pm s$)

组别	例数	VAS(分)			ODI(分)		Cobb(°)		
		术前	术后 7 d	末次随访	术前	末次随访	术前	术后 7 d	末次随访
短节段固定组	25	6.31±0.88	1.88±0.65*	1.08±0.27*	0.657±0.068	0.139±0.040	29.2±4.9	6.2±1.9*	7.4±1.8*
长节段固定组	21	6.38±0.97	1.90±0.62*	1.14±0.36*	0.627±0.066	0.138±0.042	31.0±4.1	7.1±1.6*	8.0±1.7*
<i>t</i> 值		0.073	0.011	0.514	1.493	0.101	-1.337	2.705	1.205
<i>P</i> 值		0.788	0.915	0.477	0.172	0.920	0.188	0.107	0.278

注:与术前比较, **P*<0.05

Note: Compared with preoperative data, **P*<0.05

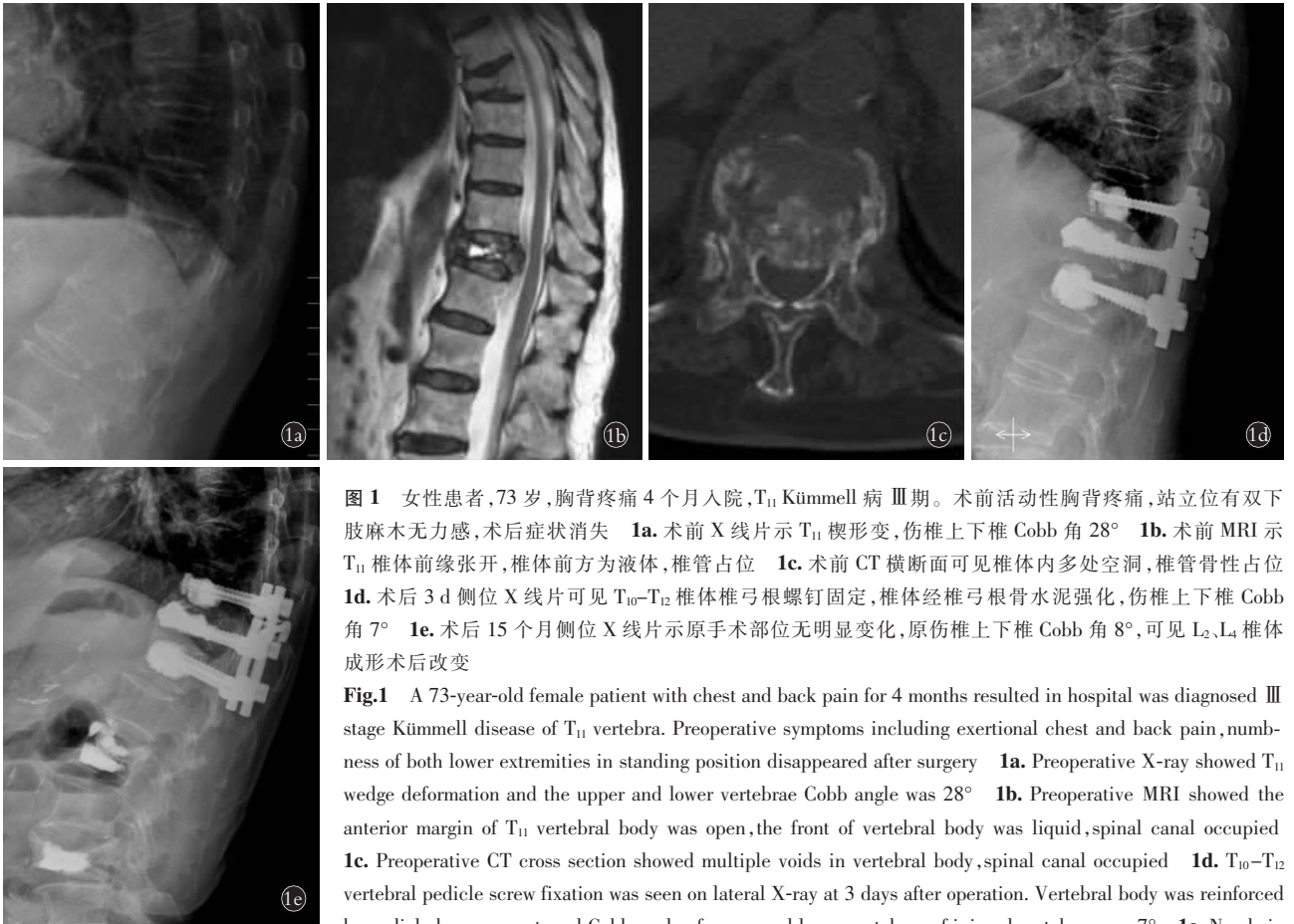


图 1 女性患者, 73 岁, 胸背疼痛 4 个月入院, T₁₁ Kümmell 病 III 期。术前活动性胸背疼痛, 站立位有双下肢麻木无力感, 术后症状消失 **1a**. 术前 X 线片示 T₁₁ 楔形变, 伤椎上下椎 Cobb 角 28° **1b**. 术前 MRI 示 T₁₁ 椎体前缘张开, 椎体前方为液体, 椎管占位 **1c**. 术前 CT 横断面可见椎体内多处空洞, 椎管骨性占位 **1d**. 术后 3 d 侧位 X 线片可见 T₁₀-T₁₂ 椎体椎弓根螺钉固定, 椎体经椎弓根骨水泥强化, 伤椎上下椎 Cobb 角 7° **1e**. 术后 15 个月侧位 X 线片示原手术部位无明显变化, 原伤椎上下椎 Cobb 角 8°, 可见 L₂、L₄ 椎体成形术后改变

Fig.1 A 73-year-old female patient with chest and back pain for 4 months resulted in hospital was diagnosed III stage Kümmell disease of T₁₁ vertebra. Preoperative symptoms including exertional chest and back pain, numbness of both lower extremities in standing position disappeared after surgery **1a**. Preoperative X-ray showed T₁₁ wedge deformation and the upper and lower vertebrae Cobb angle was 28° **1b**. Preoperative MRI showed the anterior margin of T₁₁ vertebral body was open, the front of vertebral body was liquid, spinal canal occupied **1c**. Preoperative CT cross section showed multiple voids in vertebral body, spinal canal occupied **1d**. T₁₀-T₁₂ vertebral pedicle screw fixation was seen on lateral X-ray at 3 days after operation. Vertebral body was reinforced by pedicle bone cement, and Cobb angle of upper and lower vertebrae of injured vertebrae was 7° **1e**. No obvious change in the original surgical site was found by lateral X-ray at 15 months after operation. Cobb angle of upper and lower vertebrae of the original injured vertebrae was 8°. L₂ and L₄ vertebroplasty postoperative changes was shown

ous change in the original surgical site was found by lateral X-ray at 15 months after operation. Cobb angle of upper and lower vertebrae of the original injured vertebrae was 8°. L₂ and L₄ vertebroplasty postoperative changes was shown

钉头侧张开的叶片支撑强度, 对于骨质疏松程度较重的椎体不太适宜。研究证实骨水泥钉强化螺钉在骨质疏松椎体内抗拔出强度可提高 1.5~2 倍^[14], 因此骨水泥强化固定对于骨质疏松椎体是一个有益的原则^[6], 对于 III 期 Kümmell 病内固定治疗采用骨水泥强化钉棒固定可满足内固定强度要求。

大多数 III 期 Kümmell 患者并不伴神经损害, 直接复位固定即可。有作者认为有神经损害的病例前路切除植骨支撑最为有效^[15], 可直接解除神经或脊髓压迫。有研究比较了前路和后路手术治疗 III 期 Kümmell 病, 认为后路手术时间和出血较好, 但在未强化的条件下螺钉松动、畸形丢失、假关节失等合并症高于前路^[16]。前路手术的优点是可以直接减压, 但缺点是针对骨质疏松病例内固定强度不足, 且创伤相对较大。事实上临床 Kümmell 病中出现持续的脊髓或神经病变病例比例很小, 部分表现为站立时有神经损害表现而卧位可改善或消失。神经症状产生原因多为椎管占位合并局部后凸所致椎管狭窄、脊髓或马尾受压, 一旦后凸矫正后椎管狭窄的情况会明显改善。本研究中伴神经损害 5 个病例均未直接

减压, 后凸矫正后神经症状消失。因为 Kümmell 病椎体内裂隙为空腔, 为液体或气体充填^[1], 因此在站立位椎体负重状态下高度丢失, 局部呈后凸状态。但在仰卧位或过伸位非负重状态下, 椎体前缘高度可部分或大部分恢复从而自动矫正后凸, 脊髓或硬膜囊的挤压多可解除。手术的原则是以最小的代价换取最大的收益, 因此前路手术不宜作为常规选择, 尤其是对于高龄患者。

3.2 固定方式

研究认为伤椎前方骨水泥强化有利于减少后凸和内固定失败率^[3,17], 椎体前方有效支撑可降低后方内固定应力, 有利于维持术区的稳定。本组病例前方或成形支撑或螺钉强化支撑, 配合后方融合, 因此更能有效维持术区稳定。也有改良经后路椎体切除半侧椎体支撑, 椎弓根螺钉内固定(未强化)的方式^[12], 但 1 年后螺钉已松动, 后凸角丢失, 尽管原作者认为这是一个可行方法, 但事实上随着时间推移(仅随访 1 年), 内固定失效可能将更严重, 预后可能不佳, 后方钉棒骨水泥强化后远期疗效可能会更好些。

对于固定节段, 节段越长, 应力越分散, 内固定

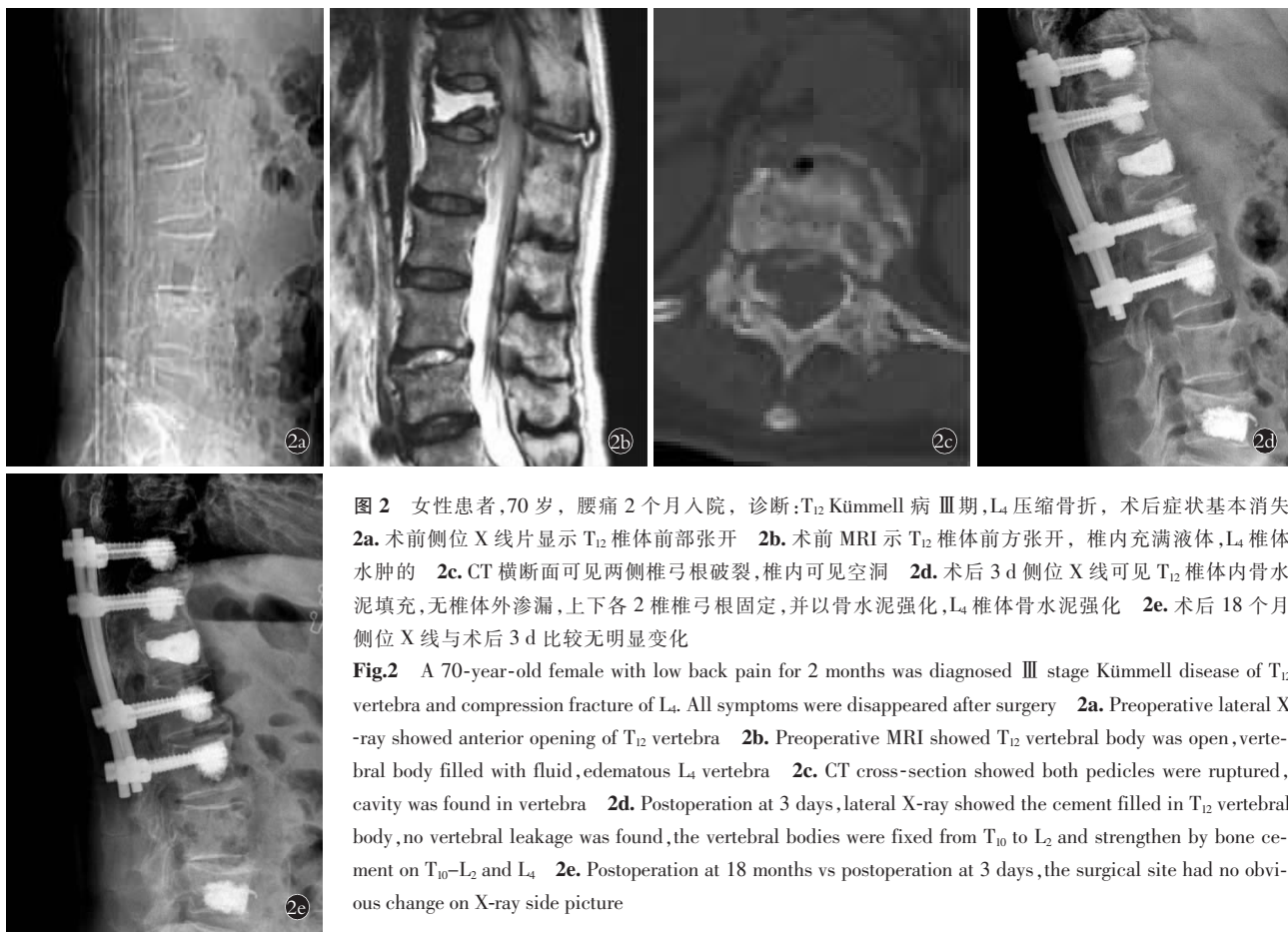


图 2 女性患者,70 岁,腰痛 2 个月入院,诊断:T₁₂ Kümmell 病 III 期,L₄ 压缩骨折,术后症状基本消失
2a. 术前侧位 X 线片显示 T₁₂ 椎体前部张开 2b. 术前 MRI 示 T₁₂ 椎体前方张开,椎内充满液体,L₄ 椎体水肿的 2c. CT 横断面可见两侧椎弓根破裂,椎内可见空洞 2d. 术后 3 d 侧位 X 线可见 T₁₂ 椎体内骨水泥填充,无椎体外渗漏,上下各 2 椎椎弓根固定,并以骨水泥强化,L₄ 椎体骨水泥强化 2e. 术后 18 个月侧位 X 线与术后 3 d 比较无明显变化

Fig.2 A 70-year-old female with low back pain for 2 months was diagnosed III stage Kümmell disease of T₁₂ vertebra and compression fracture of L₄. All symptoms were disappeared after surgery 2a. Preoperative lateral X-ray showed anterior opening of T₁₂ vertebra 2b. Preoperative MRI showed T₁₂ vertebral body was open, vertebral body filled with fluid, edematous L₄ vertebra 2c. CT cross-section showed both pedicles were ruptured, cavity was found in vertebra 2d. Postoperation at 3 days, lateral X-ray showed the cement filled in T₁₂ vertebral body, no vertebral leakage was found, the vertebral bodies were fixed from T₁₀ to L₂ and strengthened by bone cement on T₁₀-L₂ and L₄ 2e. Postoperation at 18 months vs postoperation at 3 days, the surgical site had no obvious change on X-ray side picture

稳定性越强。但由于 Kümmell 病患者年龄普遍偏大,节段越长,手术越大,对于患者手术安全性的影响也越大,相应手术费用也增加。本研究中长节段病例手术时间、出血(以及费用)均有增加,相应也增加了手术风险和医疗成本。有关 Kümmell 病的长短节段固定研究文献匮乏,在有关结核治疗的长节段和短节段固定对比研究中,认为长节段虽然手术时间、出血量均增加,但在后凸矫形和维持脊柱稳定性方面有优势^[18]。但在本组病例中,长节段和短节段在后凸矫形和维持脊柱稳定性方面并无明显差异。除骨水泥椎体强化增加了螺钉把持力外,还需注意患者的筛选、掌握置钉和水泥强化技术^[19],同时注意内固定不终止于后凸范围内^[20],才能避免矫形以及脊柱稳定性的丢失或内固定的失效。

3.3 手术风险及并发症

骨水泥渗漏是骨水泥手术的常见并发症,大部分无症状。渗漏原因可能为骨水泥推注压力较高或骨水泥推注时间太早所致。与椎体成形石膏期推注不同,通过螺钉强化需骨水泥拔丝后期推注,既能降低推注阻力也有助于避免骨水泥的过度弥散。另外术中保持警惕可能有助于降低风险^[21]。Kümmell 病本身就是骨水泥渗漏的一个高危因素,节段血管漏

随塌陷程度风险也相应增加^[22]。肺栓塞合并症在骨水泥椎体强化术中较为少见,多为骨水泥推注时机过早,骨水泥较为清稀,进入椎体周围血管至肺所致。本组惟一 1 例就是早期经验不足,骨水泥推注时机稍早,严格拔丝后期推注骨水泥后再未发生过。

在椎体压缩骨折中,邻椎骨折发生率文献变化较大(10%~45%),1 年内新发邻椎骨折率在高风险病例如高龄、低骨密度、既往陈旧骨折等^[23-24]相对较高,半年内发生率可达到 14.6%^[25],高龄患者甚至可达 22.9%^[26]。本研究两组患者均出现邻近椎体骨折。发病比分别为 4/25 和 3/21,本组病例邻椎骨折发生率并不高于椎体强化术后患者。

3.4 研究结论与不足

本研究也存在一些不足:研究非随机对照设计,病例数相对较少,骨质疏松程度不重,代表性有所欠缺;末次随访未复查 BMD,对于患者骨质疏松治疗结果不明,且随访时间相对较短,对术后更远期疗效判断证据尚不足。本研究中两组病例在疼痛、功能改善以及矫形的维持方面无明显差异,短节段固定在手术时间、出血量(及费用)方面更具优势。因此单节段 III 期 Kümmell 病,采用后路短节段骨水泥钉棒固定治疗疗效确切,无需延长固定节段,值得进一步研究。

参考文献

- [1] 赵立来,童培建,肖陆威,等. Kümmell 病的影像学诊断分析[J]. 中国骨伤, 2016, 29(5): 460-463.
ZHAO LL, TONG PJ, XIAO LW, et al. Diagnostic analysis of the radiologic characteristics in osteoporotic Kümmell's disease[J]. Zhongguo Gu Shang/China J Orthop Trauma, 2016, 29(5): 460-463. Chinese with abstract in English.
- [2] Libicher M, Appelt A, Berger I, et al. The intravertebral vacuum phenomenon as specific sign of osteonecrosis in vertebral compression fractures: results from a radiological and histological study[J]. Eur Radiol, 2007, 17(9): 2248-2252.
- [3] 俞海明,李毅中,姚学东,等. 迟发性骨质疏松性肢体塌陷的手术方式选择[J]. 中国骨伤, 2016, 29(7): 606-613
YU HM, LI YZ, YAO XD, et al. Surgical options for delayed osteoporotic vertebral collapse[J]. Zhongguo Gu Shang/China J Orthop Trauma, 2016, 29(7): 606-613. Chinese with abstract in English.
- [4] Li KC, Li AF, Hsieh CH, et al. Another option to treat Kümmell's disease with cord compression[J]. Eur Spine J, 2007, 16(16): 1479-1487.
- [5] Fabbriani G, Pirro M, Floridi P, et al. Osteoanabolic therapy: a non-surgical option of treatment for Kümmell's disease[J]. Rheumatol Int, 2012, 32(5): 1371-1374.
- [6] Hoppe S, Loosli Y, Baumgartner D, et al. Influence of screw augmentation in posterior dynamic and rigid stabilization systems in osteoporotic lumbar vertebrae: a biomechanical cadaveric study[J]. Spine (Phila Pa 1976), 2014, 39(6): E384-E389.
- [7] 中华医学会骨科学分会骨质疏松学组. 骨质疏松性骨折诊疗指南[J]. 中华骨科杂志, 2017, 37(1): 1-10.
The Osteoporosis Group of Orthopaedic Society of the Chinese Medical Association. Guidelines for the diagnosis and treatment of osteoporotic fractures[J]. Zhonghua Gu Ke Za Zhi, 2017, 37(1): 1-10. Chinese.
- [8] Chen GD, Lu Q, Wang GL, et al. Percutaneous kyphoplasty for Kümmell disease with severe spinal canal stenosis[J]. Pain Physician, 2015, 18(6): E1021-E1028.
- [9] Li HK, Hao DJ, Yang JS, et al. Percutaneous kyphoplasty versus posterior spinal fixation with vertebroplasty for treatment of Kümmell disease: A case-control study with minimal 2-year follow-up[J]. Medicine (Baltimore), 2017, 96(51): e9287.
- [10] Wang HS, Kim HS, Ju CI, et al. Delayed bone cement displacement following balloon kyphoplasty[J]. J Korean Neurosurg Soc, 2008, 43(4): 212-214.
- [11] Kim JE, Choi SS, Lee MK, et al. Failed percutaneous vertebroplasty due to insufficient correction of intravertebral instability in Kümmell's disease: a case report[J]. Pain Pract, 2017, 17(8): 1109-1114.
- [12] Liu FY, Huo LS, Liu S, et al. Modified posterior vertebralcaiyong column resection for Kümmell disease: case report[J]. Medicine (Baltimore), 2017, 96(5): e5955.
- [13] Wu ZX, Cui G, Lei W, et al. Application of an expandable pedicle screw in the severe osteoporotic spine: a preliminary study[J]. Clin Invest Med, 2010, 33(6): E368-E374.
- [14] Sarzier JS, Evans AJ, Cahill DW. Increased pedicle screw pullout strength with vertebroplasty augmentation in osteoporotic spines[J]. J Neurosurg, 2002, 96(3 Suppl): 309-312.
- [15] Sudo H, Ito M, Kaneda K, et al. Anterior decompression and strut graft versus posterior decompression and pedicle screw fixation with vertebroplasty for osteoporotic thoracolumbar vertebral collapse with neurologic deficits[J]. Spine J, 2013, 13(12): 1726-1732.
- [16] Nakashima H, Imagama S, Yukawa Y, et al. Comparative study of 2 surgical procedures for osteoporotic delayed vertebral collapse: anterior and posterior combined surgery vs posterior spinal fusion with vertebroplasty[J]. Spine (Phila Pa 1976), 2015, 40(2): E120-E126.
- [17] Uchida K, Nakajima H, Yayama T, et al. Vertebroplasty-augmented short-segment posterior fixation of osteoporotic vertebral collapse with neurologic deficit in the thoracolumbar spine: comparisons with posterior surgery without vertebroplasty and anterior surgery[J]. J Neurosurg Spine, 2010, 13(13): 612-621.
- [18] Liu Z, Zhang P, Zeng H, et al. A comparative study of single-stage transpedicular debridement, fusion, and posterior long-segment versus short-segment fixation for the treatment of thoracolumbar spinal tuberculosis in adults: minimum five year follow-up outcomes[J]. Int Orthop, 2018, 42(8): 1883-1890.
- [19] Hoppe S, Keel MJ. Pedicle screw augmentation in osteoporotic spine: indications, limitations and technical aspects[J]. Eur J Trauma Emerg Surg, 2017, 43(1): 3-8.
- [20] Alpantaki K, Dohm M, Korovessis P, et al. Surgical options for osteoporotic vertebral compression fractures complicated with spinal deformity and neurologic deficit[J]. Injury, 2018, 49(2): 261-271.
- [21] Janssen I, Ryang YM, Gempt J, et al. Risk of cement leakage and pulmonary embolism by bone cement augmented pedicle screw 2 fixation of the thoracolumbar spine[J]. Spine J, 2017, 17(6): 837-844.
- [22] Tomé-Bermejo F, Piñera AR, Duran-Álvarez C, et al. Identification of risk factors for the occurrence of cement leakage during percutaneous vertebroplasty for painful osteoporotic or malignant vertebral fracture[J]. Spine (Phila Pa 1976), 2014, 39(11): E693-E700.
- [23] Zhong BY, He SC, Zhu HD, et al. Risk prediction of new adjacent vertebral fractures after PVP for patients with vertebral compression fractures: development of a prediction model[J]. Cardiovasc Intervent Radiol, 2017, 40(2): 277-284.
- [24] Yang S, Liu Y, Yang H, et al. Risk factors and correlation of secondary adjacent vertebral compression fracture in percutaneous kyphoplasty[J]. Int J Surg, 2016, 36(Pt A): 138-142.
- [26] Bae JS, Park JH, Kim KJ, et al. Analysis of risk factors for secondary new vertebral compression fracture following percutaneous vertebroplasty in patients with osteoporosis[J]. World Neurosurg, 2017, 99: 387-394.
- [26] Takahara K, Kamimura M, Moriya H, et al. Risk factors of adjacent vertebral collapse after percutaneous vertebroplasty for osteoporotic vertebral fracture in postmenopausal women[J]. BMC Musculoskelet Disord, 2016, 17: 12.

(收稿日期: 2019-01-09 本文编辑: 王宏)