

论著

环枢关节错缝的 X 线表现

中国中医研究院骨伤科研究所(北京 100700)

周 卫 张 霁 蒋位庄 章永东 李 星 吴子明 马 达

摘要 通过对正常组和病例组环枢关节 X 线片的观察和分析,认为两侧齿突侧块间距的差值和齿突环椎轴线的偏离值大于 1mm,旋转开口位显示环枢运动异常,并伴有颈椎病的症状和体征者,可考虑为环枢关节错缝。

关键词 环枢关节 骨错缝 X 线片

在对颈椎病的治疗中,我们发现一组具有椎动脉型或交感型症状的病人,以眩晕、恶心、头痛、旋转受限等症状为主,常规保守治疗效果不佳。进一步检查后发现病人的环枢关节 X 线表现有改变,经手法调整环枢关节后,取得了快速、明确的疗效。我们把这组病人称为环枢关节错缝。为了搞清本病与正常人环枢关节 X 线表现的关系,本文对正常组和错缝组的环枢关节 X 线表现作了观察和分析。

材料和方法

正常组 45 例,男 23 例,女 22 例;年龄 22~45 岁。均为志愿者,无头、颈部任何症状和体征。病例组 35 例,男 8 例,女 27 例;年龄 24~51 岁。使用岛津 VS-10 800mA 和东芝 DC-15KB500mAX 线机,作以下体位摄片:(1)正位张口位;(2)左、右各旋转 10~15 度张口位;(3)颈椎侧位;(4)枕骨位(被摄者头部正中面对电动光圈中线,头尽量后仰,抬起下颌,使听眦线与垂直胶片成 45 度角,暗盒下缘放于枕后隆凸处)。所有 X 线片均以分度值为 0.02mm 游标卡尺,按统一标准逐项测量记录并作统计学处理。

结 果

1. 齿突与侧块间距(mm)

正常组:两侧间距相等 3 例,不相等 42 例,最大差值 2.0,差值 0~1.0 者 39 例,占总数 86.6%。平均差值为 0.59±0.9。错缝组:两侧间距均不相等,最大差值 3.78,最小差值 0.2,差值 1mm 以内者 14 例,占总数 40%。平均差值 1.26±0.12。手法治疗后,最大差值 1.70,最

小差值 0.02,差值 1mm 以内者 32 例,占总数 91.4%,平均差值 0.42±0.07。

2. 齿突轴线与环椎轴线(mm)

正常组:两线重迭者 4 例,偏移者 41 例,最大偏移值 1.76。偏移 0~1.0 者 38 例,占总数 84%。平均偏移值 0.47±0.07。错缝组:两线重迭者 8 例,最大偏移 3.14。偏移 1mm 以内者 21 例,占 60%。平均偏移值 0.87±0.14。治疗后两线重迭者 8 例,最大偏移 2.4。偏移 1mm 以内者 26 例,占 74.3%。平均偏移值 0.52±0.13。

3. 环枢关节间隙(mm)

正常组:两侧对称 9 例,不对称 36 例,平均差值 0.46±0.08,旋转 10~15 度开口位显示,左旋时右侧间隙增宽,右旋时左侧间隙增宽。错缝组:两侧对称 4 例,不对称 31 例,平均差值 0.44±0.07。治疗后两侧对称 7 例,不对称 28 例,平均差值 0.34±0.06。

4. 侧块宽度(mm)

正常组:两侧相等 3 例,不相等 42 例,平均差值 0.87±0.11。错缝组:治疗前后两侧侧块无 1 例相等,治疗前平均差值 0.91±0.14,治疗后 1.02±0.18。

5. 侧位环齿间距(mm)

正常组:最大间距 3.88,最小间距 0.64,平均值 1.64±0.1。错缝组:最大间距 4.12,最小间距 1.08,平均值 1.72±0.14。治疗后最大间距 4.20,最小间距 0.94,平均值 1.64±0.17。

6. 环枕关节枕骨位(双侧环椎横突孔中点连线与颅骨中轴线的夹角)

正常组:最大夹角 4.5 度,最小夹角 0 度,平均值 2.12 ± 0.27 度,错缝组:最大夹角 6 度,最小夹角 0 度,平均值 2.38 ± 0.36 度。治疗后最大夹角 6 度,最小夹角 0 度,平均值 2.17 ± 0.39 度。

测得的数据经统计学处理,结果见表 1。

表 1 环枢关节正常人组
与错缝组治疗前后 X 线对比 ($\bar{X} \pm S$)

	正常组(mm)	骨错缝组(mm)	
		治疗前	治疗后
齿突侧块间距*	0.59 ± 0.09	$1.26 \pm 0.12^{\Delta}$	$0.43 \pm 0.07^{\Delta}$
齿突环椎轴线*	0.47 ± 0.07	$0.87 \pm 0.14^{\Delta}$	$0.52 \pm 0.13^{\Delta}$
侧位环齿间距	1.64 ± 0.10	1.72 ± 0.14	1.64 ± 0.17
环枢关节间隙*	0.46 ± 0.08	0.44 ± 0.07	0.34 ± 0.06
侧块宽度*	0.89 ± 0.11	0.91 ± 0.14	1.02 ± 0.18

注:☆与正常组相比有显著差异。△与治疗前相比有显著差异,与正常组相比无显著差异。*数值为平均差值。

讨 论

1、由于环枢关节复杂的结构,使其在 X 线平片上出现许多独特的表现。关于环枢关节的解剖结构和 X 线平片之间的关系,前人已作了大量的工作^(1~4)。我们通过复习解剖,也进一步认识到,枢椎棘突两侧放射状排列的肌肉,使枢椎成为上颈段运动的应力中心⁽⁵⁾。环枢间的任何运动,都能使枢椎的齿突在环椎侧块中的位置发生变化。关于齿突与侧块之间关系也一直是文献讨论的主题之一,在本文正常组中,齿突侧块间距两侧相等的仅为 3 例,占 6.6%,两侧的平均差值为 $0.59 \pm 0.09\text{mm}$,其中差值在 1mm 以内的占 86.6%。齿突轴线与环椎轴线,两线完全重叠者 4 例,占 8.9%,两线偏移在 1mm 以内者占 84%,平均偏移 $0.47 \pm 0.07\text{mm}$,这些数据说明:(1)正常人的齿突在两侧侧块间并不是绝对居中,(2)绝大多数人的齿突偏移在 1mm 之内。

正位开口位反映了静态中的环枢关系,旋转 10~15 度开口位则可通过观察环枢椎的相互关系,了解其是否正常运动。从横断面看,环

椎两侧侧块的长轴呈“八”字型排列,当头部旋转向一侧时,X 线片显示对侧侧块的宽度变宽,齿突侧块间距变窄,同侧相反。由于环枢外侧平面关节在旋转的同时,带有轻度的前后滑移,使头转向一侧时,对侧的环枢平面关节间隙增宽,同侧变窄。在本文正常组中,95%以上呈这种变化,与张佐伦⁽⁶⁾的结论一致。

在正常组正位开口位中环椎两侧侧块的宽度只有 3 例相等,仅占 6.6%。因为 X 线片上显示的侧块宽度并不真正反映了侧块的解剖学的宽度,而只是间接的反映了侧块在排列上其长轴向内侧斜的程度或其肾形凹陷的程度,所以这种两侧结构上的不完全对称是正常的。

2、在所有 6 项测量中,错缝组治疗前与正常组相比,有二项具有显著差异:齿突侧块间距 ($P < 0.001$)和齿突环椎轴线 ($P < 0.05$),说明本组患者以枢椎的侧向移位为主。值得注意的是,在旋转 10~15 度开口位中,95%以上的患者出现环枢运动的异常。以枢椎右偏病人为例,左侧齿突侧块间距宽于右侧,并在头向右旋转 10~15 度时,左侧间距不象正常人那样变窄而是仍宽于右侧,而头向左旋转时环枢运动正常(图 1)。这现象提示,环枢关节向右转运动受到障碍,头的旋转由下颈椎代偿。

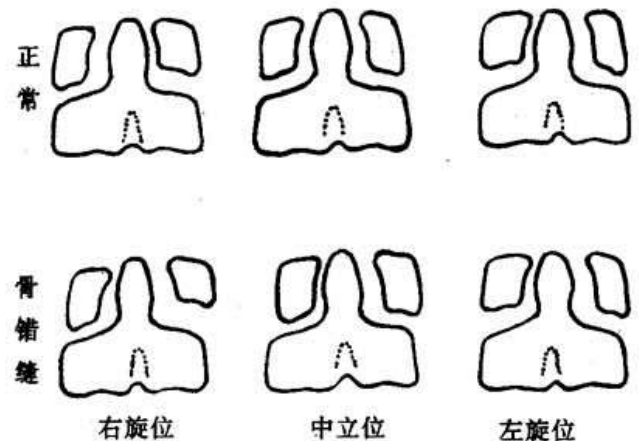


图 1 两组环枢关节在中立位和 10-15 度旋转位时的不同 X 线表现

3、正常组中齿突侧块间距差值最大者达 2mm,而错缝组中差值最小者仅 0.2mm,虽然

两组的平均差值有非常显著差异,但两组的绝对差值存在着交叉现象,所以对环枢关节错缝的诊断需要结合临床检查。我们认为可以参考以下几项:1. 患者有明显的头部或枕部疼痛,眩晕,恶心等症状;头颈转向某一侧时,症状加重;在枢椎的一侧椎板或横突处有明显压痛,并有高于对侧的隆起感。2. 开口位齿突侧块间距不等宽,差值 1mm 以上。3. 齿突与环椎轴线偏移 1mm 以上。4. 旋转 10~15 度开口位显示环枢间旋转运动异常。X 线平片对环枢关节错缝具有重要的参考价值,但不能作为唯一的诊断依据。另外需要指出的是,对那些有典型症状和体征者,即使齿突偏移小于 1mm 但旋转开口位显示环枢运动异常者,也应酌情行手法治疗。

X 线片可为手法的方向和方法提供明确的指示。

参考文献

1. 何灿熙. 成人颈椎枕、环、枢段 X 线观察. 中华放射学杂志 1978;12(2):95
2. 陈学仁. 等. 颈椎环枢脱位的 X 线诊断. 中华放射学杂志 1965;10(1):46
3. 王泽忠. 环枢关节脱位 X 线诊断问题的商讨. 临床放射学杂志 1984;3(4):211
4. Fielding J. W. et al Atlanto-Axial Rotatory Fixation. J Bone Joint Surg (Am) 1977;59:37
5. 周卫. 等. 环枢关节错缝与上颈段解剖的关系. 中国骨伤 1996;9(1):5
6. 张佐伦. 等. 环枢关节旋转半脱位的解剖变化及 X 线诊断. 中华骨科杂志 1990;10(1):24

(收稿:1995-12-28)

张力带固定与钢丝环扎治疗髌骨骨折疗效分析

西安医科大二附院(710004)

贺西京 李辉 王坤正 史明启 刘安庆 宋金辉 党晓谦

摘要 使用张力带固定、钢丝环扎与丝线环扎治疗髌骨骨折共 65 例,平均优良率 91.52%,但优良疗效者张力带组是 80%,钢丝及丝线环扎组分别是 56%及 56.5%。张力带内固定术后不需石膏外固定,利于膝关节早期功能锻炼与康复,疗效明显优于其它两种疗效($p < 0.05$),但术中操作要求准确细致。与钢丝环扎相比,丝线环扎荷包缝合具有可避免取出内固定的第二次手术的优点,两组疗效相似。

关键词 髌骨骨折 内固定

髌骨骨折是一种常见的关节内骨折,治疗方法也较多,本文就我院 1986 年~1992 年手术内固定治疗的 65 例髌骨骨折报告如下:

临床资料

本组共 65 例髌骨骨折,单纯骨折且移位轻者以及严重的粉碎性骨折不包括在本组病例之内。本组均为单侧骨折。其中男 42 例,女 23 例;平均年龄 41 岁(22~66 岁);横形骨折 13 例、粉碎骨折 52 例;记载详细的 41 例中 34 例骨折的远端破碎 2~4 块,手术在骨折后 4 小时~3 周内施行。

手术方法

持续硬膜外麻醉,术式分为 3 种,将病例随机分为 3 组。①钢丝环扎固定 25 例,术后长腿石膏固定 4 周,去石膏后不负重练习膝关节屈

伸,6 周后扶拐行走。②10 号粗丝线荷包缝合 14 例,术后处理如钢丝环扎法。③张力带固定法 26 例,术中复位后沿髌骨上下极分别钻入两枚克氏针,该针垂直穿过骨折线,然后用 20 号钢丝环形或“8”字形围绕克氏针加压固定骨折,术后不做外固定;3 天后开始练习膝关节伸屈活动。3 种方法均认真修补骨折处破裂的髌韧带及股四头肌肌腱扩张部的破裂口。髌骨下极小的破裂碎片若不在关节面则应予切除,仅固定大的主要骨折块。

结果

随访病例时间最长者 5 年,最短者 8 个月,平均 3.4 年。根据有关文献^[1]术后疗效分为 4 级。即优:膝关节无疼痛,伸屈活动范围正常或减少 10°以内,无肌萎缩,行走自如。良:膝关节

English Abstract

Radiographic findings of derangement of atlanto—axial joint

Institute of Orthopaedics and Traumatology, China Academy of TCM(100700)

Based on the radiographic study and analysis of atlanto—axial joint of normal and abnormal, we consider that the derangement of atlanto—axial joint can be diagnosed as: the difference of bilateral distance between the dens and the lateral mass is larger than 1mm, the difference of central sagittal line of dens and atlas is larger than 1mm; there is an abnormal movement of atlanto—axial joint on the X—ray film of open mouth with 15° rotation; and the patient bears the symptoms and signs of cervical spondylosis.

Key words Atlanto—axial joint Derangement of atlanto—axial joint X—ray film

(original article page 3)

Tension band and circular fixation in treating patellar fracture

Second Affiliated Hospital Of Xian University of Medical Science(710004)

Sixty five cases of fracture of patella were treated with tension band, circular fixation with stainless steel and circular fixation with silk thread, the average rate of excellent and good being 91.52%. In the excellent group, the tension band group was 80%, and the stainless steel and silk thread group being 56% and 56.5% respectively. Due to internal fixation with tension band do not need external fixation with plaster of paris, so it facilitates early knee joint exercise and rehabilitation. The therapeutic efficacy is superior than the other two methods ($P < 0.05$). It requires accurate and fine manipulation during operation. As compared with stainless steel circular fixation, silk thread circular fixation bears the advantage of avoiding another operation for withdrawing of the wire, though their therapeutic effect was in similarity.

Key words Fracture of patella Internal fixation

(original article page 5)

Clinical observation and animal experimental study on influence of electric effect in

bone remodelling

Academy of Science, Hubei Province (050081)

There is different explanation for the mechanism of the influence of electric effect in bone remodelling. Experimental study was carried on in observation of magnetic field in the influence of bone healing and electric current in bone remodelling. Through clinical observation and animal experiment, it indicates that electric effect can influence bone remodelling and promote bone healing.

Key words Electric effect Bone Bone remodelling

(original article page 8)

Transplantation of medial head of gastrocnemius muscle in treating old injury of posterior cruciate ligament

Guangdong Hospital of TCM, Guangdong College of TCM(510120)

since 1991, five cases (2 moderate instability, 3 severe instability) of old traumatic posterior cruciate ligament injury were treated with medial 1/3 to 1/2 of medial head of gastrocnemius muscle of the same side. Marked improvement of function (walking, quick working, going upstairs and downstairs, no instability) was found postoperatively, except there was a little bit sensation of instability (during rapid turning round or rapid stopping).

Key words Disposition of gastrocnemius muscle posterior cruciate ligament Injury of knee surgical operation Joint ligament

(original article page 10)

Treatment of avulsion fracture of tibial spine Luoyang Railway Hospital, Hunan province(471002)

In this article, 8 cases with an average of 14 years of age suffering avulsion fracture of tibial spine were reported. they were classified into 3 types, two of them were treated with conservative therapy; 6 of them, internal fixation with steel wire. Bony healing nearly normal joint function and satisfactory results were found in

all of these 8 followup cases. Classification and method of operation were introduced. Advantage of the operation, early diagnosis and mechanism of injury were discussed.

Key words Tibia Fracture peration
(original article page 11)

Improved Stimson's method in treating hip joint dislocation

Second College of Medical Science, Xi'an University of Medical Science(710004)

Seventy four cases of traumatic posterior dislocation of hip joint were reported in this article. Satisfactory clinical results were obtained after treatment with self--designed modified stimson manore duction. Method of reduction was introduced in detail, advantage of it was discussed.

Key words Traumatic posterior dislocation of hip joint Modified stimson's method
(original article page 12)

Characteristics of protrusion of L5S1 intervertebral disc (An analysis of 86 cases with symptoms and signs, myelogram, MRI, CT scanning

and operative findings)

General Hospital of Railway Construction Corporation of China(100043)

Eighty six operated cases of protrusion of lumbar intervertebral disc were reported. Among them, 29 cases (33.72%) were L5S1 level, next to L4, 5. The results show that the lower back pain in L5S1 level is more severe; for Laseque's sign, L5S1 level being $39.66^{\circ} \pm 18.46^{\circ}$; L4, 5, $49.90^{\circ} \pm 21.37^{\circ}$ ($P < 0.0284$). water soluble myelogram, MRI and CT scanning bear better diagnostic action though there were no difference statistically. But each examination bear their own benefit. There was significant difference between type and degree of two intervertebral disc space ($P < 0.013$, $P < 0.012$) being found in the operation. Lateral or extreme lateral position were found more in cases in level L5S1. It is realized that myelogram is the first choice, MRI or CT scanning should be added in doubtful cases. Lateral recess and nerve root canal should be carefully explored during operation.

Key words Protrusion of lumbar intervertebral disc L5S1 level
(original article page 29)

Zhongguo Gushang
China Journal of Orthopaedics
and Traumatology
(Bimonthly)
Chief Editor: Shang Tian-yu
Editorial Board 18 Beixincang
Dongzhimen, Beijing China
Subscriptions:
Domestic Local Post Offices
Overseas China International
Book Trading Corporation
(P. O. Box 399, Beijing)

中 国 骨 伤

(双月刊)

主编 尚天裕

主办单位

中国中西医结合学会

中国中医研究院

承办单位

中国中医研究院骨伤科研究所

协办单位

凤阳门皇汉中医诊所

山西省介休市正骨专科医院

编辑出版者

中国骨伤杂志编辑部

地址:北京东直门北新仓18号

邮政编码:100700

发 行 者

国内总发行:北京报刊发行局

订 购 处:全国各地邮局

国外总发行:中国国际图书贸易

总公司(北京 399 信箱)

印刷装订者

北京黄作印刷厂