

明胶海绵在经皮椎体后凸成形术中预防 Kümmell 病椎体前壁骨水泥渗漏的临床观察

张树良, 徐彬, 劳杨骏, 盛红枫

(浙江省立同德医院骨科, 浙江 杭州 310012)

【摘要】 目的: 评价经皮椎体后凸成形术(percutaneous kyphoplasty, PKP)术中应用明胶海绵预防 Kümmell 病患者椎体前壁骨水泥渗漏的效果。方法: 选取 2017 年 6 月至 2019 年 12 月期间 13 例临床诊断为 Kümmell 病的患者, 予以行 PKP 术治疗, 同时术中应用明胶海绵置入椎体前壁处预防骨水泥渗漏, 其中男 3 例, 女 10 例, 年龄(73.84±8.44)岁。采用视觉模拟量表(visual analogue scale, VAS)和 Oswestry 功能障碍指数(Oswestry Disability Index, ODI)分别对治疗前后患者的疼痛程度及胸腰椎功能进行评估, 并通过 X 线观察患者术后骨水泥渗漏情况。结果: 治疗前及治疗后 1 d、3 个月 VAS 评分分别为(7.31±0.83)分、(2.92±1.13)分、(1.69±1.11)分, 治疗后 1 d、3 个月 VAS 评分较治疗前降低($P < 0.05$), 患者术后疼痛明显缓解。治疗前、治疗后 3 个月 ODI 分别是(71.08±9.46)%、(17.85±7.82)%, 治疗后 3 个月的 ODI 较治疗前改善($P < 0.05$), 患者术后胸腰椎功能较术前明显改善。术后 X 线片示椎体前壁无骨水泥渗漏。结论: 明胶海绵可预防 Kümmell 病椎体前壁骨水泥的渗漏, 降低椎体前方主动脉等软组织的热损伤和机械损伤风险, 不影响患者术后疼痛的缓解和胸腰椎功能的恢复。

【关键词】 Kümmell 病; 后凸成形术; 骨水泥渗漏; 明胶海绵, 吸收性

中图分类号: R681.5

DOI: 10.12200/j.issn.1003-0034.2021.08.009

开放科学(资源服务)标识码(OSID):



Clinical observation of gelfoam in preventing cement leakage via the anterior vertebral wall in Kümmell's patients treated with percutaneous kyphoplasty ZHANG Shu-liang, XU Bin, LAO Yang-jun, and SHENG Hong-feng. Department of Orthopaedics, Tongde Hospital of Zhejiang Province, Hangzhou 310012, Zhejiang, China

ABSTRACT Objective: To evaluate the efficacy of gelfoam granules application in prevention of cement leakage via anterior vertebral wall in Kümmell's patients treated with percutaneous kyphoplasty (PKP). **Methods:** From June 2017 to December 2019, 13 patients with Kümmell disease were treated with PKP, and gelatin sponge was inserted into the anterior wall of vertebral body to prevent bone cement leakage. There were 3 males and 10 females, with an average age of (73.84±8.44) years. The visual analogue scale (VAS) was used to record the degree of pain before treatment and 1 day and 3 months after treatment; Oswestry Disability Index (ODI) was used to evaluate the thoracolumbar function before treatment and 3 months after treatment; X-ray was used to observe the bone cement leakage after operation. **Results:** The VAS scores were 7.31±0.83, 2.92±1.13 and 1.69±1.11 before treatment and 1 day and 3 months after treatment, respectively. The VAS scores on the 1st day and 3 months after treatment were lower than those before treatment ($P < 0.05$), and the postoperative pain was significantly relieved. The ODI before treatment and 3 months after treatment were (71.08±9.46)%, (17.85±7.82)%, respectively. The ODI at 3 months after treatment was improved compared with that before treatment ($P < 0.05$), and the postoperative thoracolumbar function was significantly improved compared with that before treatment. Postoperative X-ray showed no leakage of bone cement in the anterior wall of vertebral body. **Conclusion:** The application of gelfoam granules in PKP can effectively prevent the leakage of bone cement via the anterior vertebral wall of Kümmell patients, and reduce the risk of thermal and mechanical injury of soft tissues such as the aorta in front of the vertebral body, and does not affect the postoperative pain relief and the recovery of thoracolumbar function.

KEYWORDS Kümmell disease; Kyphoplasty; Bone cement leakage; Gelatin sponge, absorbable

目前国内外 Kümmell 病的主要治疗方式之一是经皮椎体后凸成形术(percutaneous kyphoplasty,

PKP)^[1-3]。由于大多数 Kümmell 病的特点是受累椎体前壁破裂^[4], Kümmell 病椎体内存在裂隙, 骨水泥发生渗漏的风险很高。有文献报道 PKP 治疗 Kümmell 病骨水泥渗漏率为 30.04%^[5], Kong 等^[6]发现超过 1/5 的 Kümmell 病患者发生了 PKP 术骨水泥渗漏。谢胜

通讯作者: 盛红枫 E-mail: tdhongfeng@126.com

Corresponding author: SHENG Hong-feng E-mail: tdhongfeng@126.com

荣等^[2]报道 PKP 术治疗 Kümmell 病时骨水泥渗漏率为 55.6%。因此 PKP 治疗 Kümmell 病在临床中的最大隐患是骨水泥渗漏^[7]。临床学者一直在研究可以降低骨水泥渗漏率的方法。有报道称明胶海绵能有效降低椎体骨折骨水泥渗漏的发生率^[8]；也有报道称明胶海绵在手术中的应用对减少骨水泥渗漏没有明显效果^[9]。笔者对 Kümmell 病患者在行 PKP 术时使用明胶海绵预防椎体前壁骨水泥的渗漏进行了尝试,对其临床效果进行了验证,希望对广大学者在以后应用明胶海绵预防骨水泥的渗漏时有所帮助。

1 临床资料

1.1 病例选择

纳入标准:(1)年龄 ≥ 60 岁,胸椎或腰椎骨质疏松性椎体骨折。(2)患者有腰背部疼痛症状,经过3个月以上的保守治疗无明显缓解,疼痛影响日常生活。(3)X线检查可见明确的椎体压缩性骨折;三维CT检查可见椎体内形态不规则的真空裂隙征,椎体前壁存在不规则裂口;MRI检查病变椎体T1像呈低信号,T2像呈高信号或低信号。排除标准:(1)年龄 < 60 岁。(2)单纯胸腰椎骨质疏松性椎体骨折。(3)伴有凝血功能障碍及其他出血性疾病者,如血友病。(4)椎管内有占位伴神经脊髓损伤症状者。(5)全身情况差不能耐受手术者。

1.2 一般资料

2017年6月至2019年12月符合病例选择标准,手术治疗 Kümmell 病患者13例,其中男3例,女10例;年龄60~78(73.84 \pm 8.44)岁。均为单节段椎体病变,共13椎,分别为T₁₂6例,T₁₁2例,L₁3例,L₂1例,T₇1例。

2 治疗方法

患者取俯卧位,均采用PKP。背部病椎手术区常规消毒铺无菌治疗巾,C形臂X线机准确透视定位,局部浸润麻醉。在C形臂X线机实时监控下,行椎弓根穿刺。右侧椎弓根穿刺点在2点钟位置,左侧椎弓根穿刺点在10点钟位置。正位透视穿刺针到达棘突中央,侧位透视穿刺针到达椎体前后径前1/3处时,拔出针芯,置入外套筒。定位满意后置入球囊,定位见球囊正位在棘突中央,侧位位于椎体矢状面中点偏前1/3处,定位满意后球囊加压扩张,造影剂充盈显影满意。根据术前三维CT冠状位、矢状位、轴位的测量数据计算椎体裂隙的体积及位置,结合注入造影剂后球囊撑开的体积,综合估计所需的海绵量,一般用量约为半块至1块明胶海绵(金陵药业股份有限公司,6cm \times 2cm \times 0.5cm)。准备可通过工作套管直径的明胶海绵颗粒,把颗粒状明胶海绵置入工作套管,使用推杆将颗粒状明胶海绵向前推,C形臂

X线机透视观察推杆前端到达的位置即为海绵所在位置。在透视监控下推杆到达裂口处,表明明胶海绵也被推至病椎前壁裂口处。然后,将搅拌好已呈拉丝状态的骨水泥推注进椎体,推注全程在C形臂X线机透视下进行,增加骨水泥推注压力而骨水泥未超出椎体前方皮质可判断前方裂口已被明胶海绵阻隔并堵住,待骨水泥弥散均匀后停止推注。术后继续服用抗骨质疏松药,患者术后1~5d出院。

3 结果

使用视觉模拟评分(visual analogue scale, VAS)对患者治疗前及治疗后1d、3个月的疼痛程度进行评价^[8],通过术后X线片观察骨水泥渗漏情况。13例患者治疗前VAS评分为7.31 \pm 0.83,治疗后1d为2.92 \pm 1.13,治疗后3个月为1.69 \pm 1.11,治疗后评分低于治疗前($F=108.061, P=0.000$),即治疗后患者疼痛程度较治疗前改善。术后X线检查未见椎体前壁骨水泥渗漏,但发现2例上方椎间隙渗漏,典型病例影像学资料见图1。围手术期至随访时未发现神经、血管损伤等不良事件。

4 讨论

4.1 Kümmell 病特点

Kümmell 病是一种特殊类型的老年骨质疏松性椎体压缩性骨折,伴有椎体塌陷,往往是椎体前方塌陷较椎体后方严重^[10],因而患者会出现后凸表现。受累椎体多发于胸腰椎交界处,以T₁₂椎体最常见^[11]。Kümmell 病最初影像学一般阴性,随着病情进展X线片表现为椎体压缩性骨折,逐渐出现椎体骨坏死,椎体内出现一空腔,疼痛也进行性加重。CT表现为椎体内出现不规则的真空裂隙,裂隙边缘硬化,这也是 Kümmell 病与普通骨质疏松椎体压缩性骨折的主要区别^[12]。如果裂隙内充满液体,MRI检查表现为T1像低信号,T2像高信号;如果气体填充进裂隙时,T1、T2均显示低信号,这些特征高度提示缺血性坏死,可出现典型的双线征^[13]。由于 Kümmell 病椎体内真空裂隙的存在导致行PKP术时骨水泥渗漏较普通骨质疏松性压缩骨折发生率高^[14]。骨水泥渗漏主要有3条路径,分别为沿椎体骨皮质破损渗漏、沿椎基底静脉渗漏和沿椎间静脉渗漏^[15],在前期的临床治疗中笔者注意到 Kümmell 病骨水泥更多在椎体前壁皮质破损处渗漏,谢胜荣等^[2]在 Kümmell 病临床研究中也发现骨水泥渗漏主要集中于椎体前方。Sun等^[16]研究发现椎体皮质破裂是骨水泥渗漏的独立危险因素,另外有研究显示 Kümmell 病椎体坏死和椎体塌陷主要发生在椎体前1/3^[11]。由于 Kümmell 病主要是椎体前壁破裂^[4],并且椎体内的真空裂隙的上下壁存在硬化,因此骨水泥多向前方渗漏。

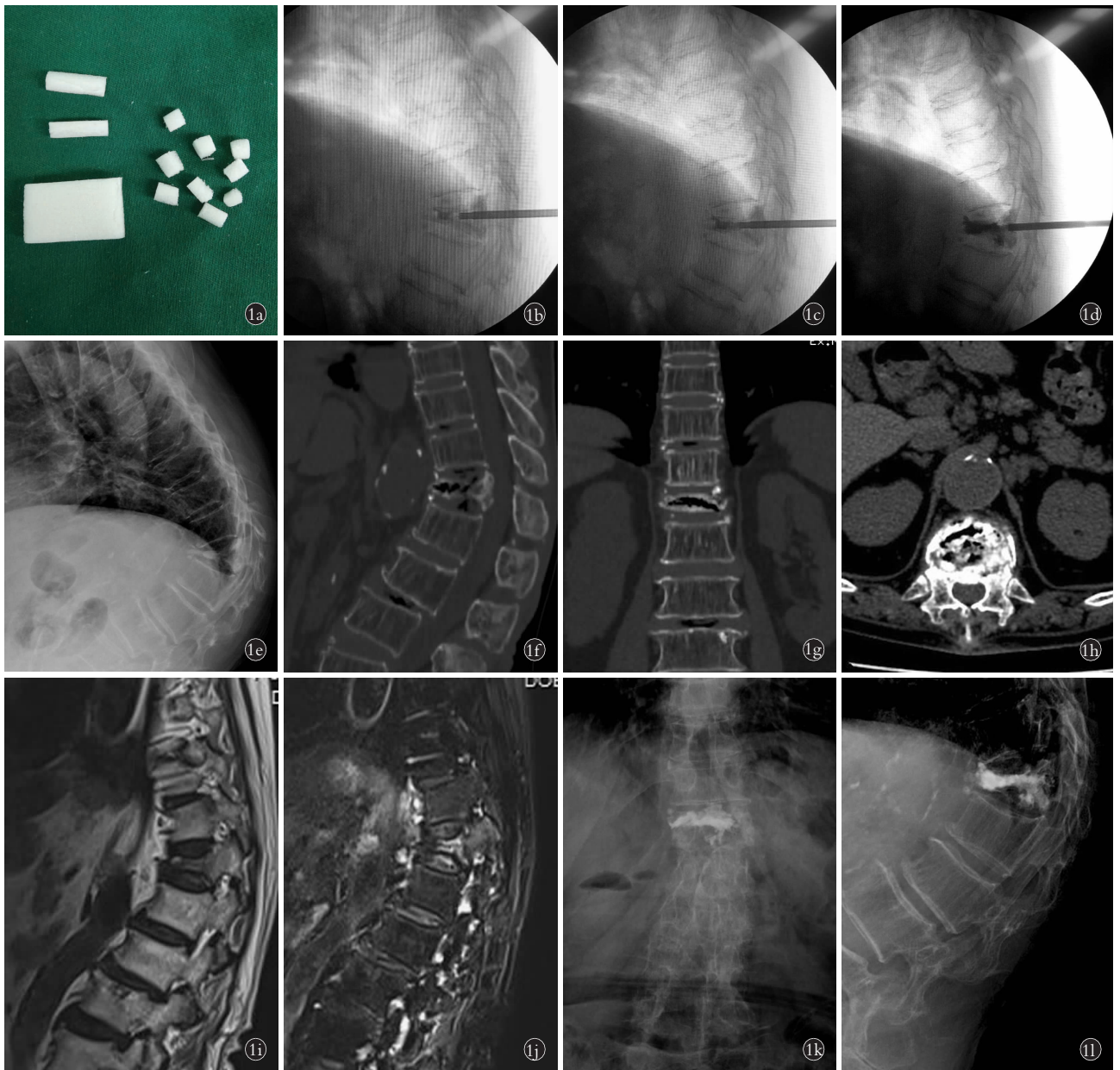


图 1 患者,女,75岁,T₁₂椎体 Kümmell 病 **1a.**制作的明胶海绵颗粒 **1b.**骨水泥前方被明胶海绵颗粒阻挡 **1c,1d.**骨水泥弥散向前推挤明胶海绵,但未渗漏出椎体前方皮质缺损处,少量向上方椎间隙渗漏 **1e.**X 线片显示 T₁₂椎体压缩性骨折,前柱压缩严重 **1f,1g,1h.**T₁₂椎体内见不规则的真空裂隙,裂隙上下边缘硬化,椎体前壁皮质破损,椎体前方紧贴主动脉 **1i,1j.**T₁₂椎体 MRI 显示 T1 低信号,T2 高信号,见双线征 **1k,1l.**T₁₂椎体 PKP 治疗后第 3 天 X 线片,前方未见骨水泥渗漏,上方椎间隙少量骨水泥渗漏

Fig.1 A 75-year-old female patients with Kümmell's disease of T₁₂ **1a.**Gelfoam was divided into small granules **1b.**Gelfoam granules formed a barrier in front of the bone cement **1c,1d.**The bone cement diffused forward the gelfoam granules, but it did not leak out the anterior cortical defect of the vertebral body, and a little cement leaked into the upper vertebral space **1e.**X-ray showed T₁₂ vertebral body compression fracture with severe vertebral anterior column collapse **1f,1g,1h.**CT scan of T₁₂ vertebral body demonstrated the vacuum cleft phenomenon, the upper and lower margins of the cleft were hardened, the anterior cortex of the vertebral body was damaged. The aorta was closely adjacent to the anterior wall of the vertebral body **1i,1j.**MRI showed low T1-weighted signal and T2-weighted signal of the vertebral cleft, and 'double line sign' was found **1k,1l.**X-ray films on the 3rd day post-operative T₁₂ vertebral body showed there was no cement leakage in front of the vertebral body, but a little cement leaked into the upper vertebral space

4.2 Kümmell 病预防椎体前壁骨水泥渗漏的必要性和方法

骨水泥聚化凝固时温度 100~110 °C^[17], 高温可造成骨水泥周围组织和神经的损伤坏死^[18]。Lai 等^[19]研究发现骨水泥在椎体内时对椎体周围组织不会产

生热损伤, 如果骨水泥泄漏至椎体外则可能导致神经、血管等软组织热损伤。以往更多预防椎管内的骨水泥渗漏, 以避免神经脊髓的压迫, 往往忽略了 Kümmell 病椎体前方的渗漏, 由于胸腰段椎体前方隔着前纵韧带与主动脉紧密相邻, 骨水泥渗漏至前

方产生的热效应容易对主动脉及邻近组织造成热损伤。既往研究显示骨组织在 50 ℃ 环境下 1 min 就会出现广泛的损伤^[20], 1 ml 的骨水泥外渗至骨骼肌中的聚合放热效应就会导致骨骼肌细胞坏死^[21]。由于胸腰段脊柱前方紧邻主动脉, 骨水泥前方渗漏后形成硬性突起, 主动脉节律性的搏动使前纵韧带和主动脉在硬性突起上反复摩擦, 也会引起前纵韧带和主动脉的机械性损伤。虽然临床尚未遇到出现相关并发症的患者, 但是预防椎体前壁骨水泥渗漏必须引起临床医生的重视, 应将其提到与预防椎管内渗漏同样的高度。目前广大学者尝试了预防骨水泥渗漏的很多方法。杨惠林等^[4]发现 PKP 采用分次灌注骨水泥技术治疗 Kümmell 病可有效降低骨水泥渗漏率。Duan 等^[22]报道治疗 Kümmell 病时椎体中使用骨填充网袋可以有效预防骨水泥的渗漏, 获得了很好的临床效果。徐林飞等^[23]将明胶海绵制成混悬液预注入椎体进行椎体成形术发现可以减少骨水泥渗漏率和渗漏量。还有学者报道使用明胶海绵碎屑可有效降低骨质疏松性椎体骨折患者 PKP 治疗后骨水泥渗漏的发生率^[8]。Bhatia 等^[24]研究也表明明胶海绵可以最大限度地减少骨水泥渗漏的发生。在临床实践中笔者发现明胶海绵对降低 Kümmell 病椎体前方骨水泥渗漏确实有效果。Nieuwenhuijse 等^[25]发现骨水泥的黏度是影响骨水泥渗漏的独立危险因素。Wang 等^[26]发表的临床研究认为高黏度骨水泥可显著减少骨水泥渗漏, 而明胶海绵就是通过增加骨水泥的黏度以减少水泥渗漏。Meng 等^[27]报道显示明胶海绵颗粒, 无论直径大小都可以增加骨水泥黏度, 并且颗粒直径越大, 骨水泥黏度越大, 混合明胶海绵后也不会降低骨水泥的抗压强度。所以本研究使用的明胶海绵颗粒在能通过工作套管的前提下, 要尽可能的大, 以增加骨水泥黏度减少渗漏。笔者把明胶海绵在 C 形臂 X 线机持续透视下置入椎体前壁处, 可以对椎体前壁裂缝和破孔起到封堵的作用, 阻挡骨水泥向前弥散减少前方渗漏。与此同时明胶海绵还可以在主动脉等软组织与骨水泥之间形成一层屏障, 能够遮挡骨水泥的热效应避免热损伤。在本研究中, 术中 C 形臂 X 线监视可见骨水泥被明胶海绵阻挡, 向前弥散缓慢, 有效避免了骨水泥渗漏和热损伤。

本研究中 Kümmell 病患者的术后 X 线片未发现椎体前壁骨水泥渗漏, 治疗后 VAS、ODI 功能障碍指数较术前明显好转, 患者临床症状显著改善, 效果安全可靠。可见在 Kümmell 病 PKP 术中应用明胶海绵可有效预防椎体前壁骨水泥渗漏, 不影响患者术后疼痛的缓解和胸腰椎功能的恢复。

笔者临床中对预防 Kümmell 病椎体前壁渗漏取得了阶段性的效果, 但对椎体上下间隙的渗漏还需进一步研究。本研究存在一定的局限, 缺乏骨水泥渗漏的定量数据指标; Kümmell 病比较少见, 本研究的临床病例较少, 下一步需要收集更多的病例进行大样本研究。

参考文献

- [1] Kim P, Kim SW. Balloon kyphoplasty: an effective treatment for Kümmell disease [J]. Korean J Spine, 2016, 13(3): 102.
- [2] 谢胜荣, 杨忠义, 杨浩森, 等. PKP 治疗 Kümmell 病骨水泥渗漏影像及临床疗效观察 [J]. 中国骨与关节损伤杂志, 2017, 32(9): 913-916.
XIE SR, YANG ZY, YANG HS, et al. Imaging and clinical observation of cement leakage in PKP for Kümmell disease [J]. Zhongguo Gu Yu Guan Jie Sun Shang Za Zhi, 2017, 32(9): 913-916. Chinese.
- [3] 赵立来, 童培建, 肖鲁伟, 等. 球囊扩张椎体后凸成形术治疗 Kümmell 病的疗效观察 [J]. 中国骨伤, 2013, 26(5): 429-434.
ZHAO LL, TONG PJ, XIAO LW, et al. Balloon kyphoplasty for the treatment of osteoporotic Kümmell disease [J]. Zhongguo Gu Shang/China J Orthop Trauma, 2013, 26(5): 429-434. Chinese with abstract in English.
- [4] 杨惠林, 王根林, 姜为民, 等. 分次灌注骨水泥技术治疗 Kümmell 病 [J]. 脊柱外科杂志, 2012, 10(1): 22-24.
YANG HL, WANG GL, JIANG WM, et al. Graded infusion of bone cement in balloon kyphoplasty for Kümmell's disease [J]. Ji Zhu Wai Ke Za Zhi, 2012, 10(1): 22-24. Chinese.
- [5] 路文超, 王宇鹏, 湛川. 椎体后凸成形治疗 Kümmell 病过程中发生的骨水泥渗漏 [J]. 中国组织工程研究, 2019, 23(2): 172-177.
LU WC, WANG YP, ZHAN C. Kümmell disease: bone cement leakage during kyphoplasty [J]. Zhongguo Zu Zhi Gong Cheng Yan Jiu, 2019, 23(2): 172-177. Chinese.
- [6] Kong L, Wang P, Wang L, et al. Comparison of vertebroplasty and kyphoplasty in the treatment of osteoporotic vertebral compression fractures with intravertebral clefts [J]. Euro J Orthop Surg Trauma, 2014, 24(S1): 201-208.
- [7] Georgy BA. Clinical experience with high-viscosity cements for percutaneous vertebral body augmentation: occurrence, degree, and location of cement leakage compared with kyphoplasty [J]. AJNR Am J Neuroradiol, 2010, 31(3): 504-508.
- [8] 何磊, 钱宇, 吕佐, 等. 明胶海绵碎屑预填注在椎体后凸成形术中预防骨水泥渗漏的作用 [J]. 中华骨科杂志, 2019, 39(19): 1173-1179.
HE L, QIAN Y, LYU Z, et al. Per-filling of gelatin sponge debris in preventing bone cement leakage during kyphosis [J]. Zhonghua Gu Ke Za Zhi, 2019, 39(19): 1173-1179. Chinese.
- [9] Oh J, Doh J, Shim J, et al. The effectiveness of gelfoam technique before percutaneous vertebroplasty: Is it helpful for prevention of cement leakage? A prospective randomized control study [J]. Korean J Spine, 2016, 13(2): 63-66.
- [10] Li H, Liang C, Chen Q. Kümmell's disease, an uncommon and complicated spinal disorder: A review [J]. J Inter Med Res, 2012, 40(2): 406-414.
- [11] 张磊磊, 李健. Kümmell 病的研究进展 [J]. 中国矫形外科杂志,

- 2015,23(9):816-819.
ZHANG LL, LI J. Progress in Kümmell disease [J]. Zhongguo Jiao Xing Wai Ke Za Zhi, 2015, 23(9):816-819. Chinese.
- [12] Park JW, Park J, Jeon HJ, et al. Kümmell disease treated with percutaneous vertebroplasty: Minimum 1 year follow-up [J]. Korean J Neurotrauma, 2017, 13(2):119.
- [13] 赵立来, 童培建, 肖鲁伟, 等. Kümmell 病的影像学诊断分析 [J]. 中国骨伤, 2016, 29(5):460-463.
ZHAO LL, TONG PJ, XIAO LW, et al. Diagnostic analysis of the radiologic characteristics in osteoporotic Kümmell's disease [J]. Zhongguo Gu Shang/China J Orthop Trauma, 2016, 29(5):460-463. Chinese with abstract in English.
- [14] 赵敏, 何承建. 经皮椎体成形术中应用明胶海绵预防骨水泥渗漏 25 例 [J]. 中国中医骨伤科杂志, 2019, 27(8):65-67.
ZHAO M, HE CJ. Gelatin sponge was used to prevent bone cement leakage in 25 cases of percutaneous vertebroplasty [J]. Zhongguo Zhong Yi Gu Shang Ke Za Zhi, 2019, 27(8):65-67. Chinese.
- [15] 刘滔, 张志明, 史金辉, 等. 骨水泥温度梯度灌注技术在经皮椎体后凸成形术中的应用 [J]. 中国脊柱脊髓杂志, 2015, 25(12):1073-1078.
LIU T, ZHANG ZM, SHI JH, et al. Temperature gradient cement injection technique in percutaneous vertebroplasty for osteoporotic vertebral compression fractures [J]. Zhongguo Ji Zhu Ji Sui Za Zhi, 2015, 25(12):1073-1078. Chinese.
- [16] Sun H, Jing X, Liu Y, et al. The optimal volume fraction in percutaneous vertebroplasty evaluated by pain relief, cement dispersion, and cement leakage: a prospective cohort study of 130 patients with painful osteoporotic vertebral compression fracture in the thoracolumbar vertebra [J]. World Neurosurgery, 2018, 114: e677-e688.
- [17] 贾崇哲, 唐海, 陈浩, 等. 聚甲基丙烯酸甲酯骨水泥的基础研究进展 [J]. 临床和实验医学杂志, 2017, 16(5):519-521.
JIA CZ, TANG H, CHEN H, et al. Progress of basic research on polymethyl methacrylate bone cement [J]. Lin Chuang He Shi Yan Yi Xue Za Zhi, 2017, 16(5):519-521. Chinese.
- [18] Belkoff SM, Molloy S. Temperature measurement during polymerization of polymethylmethacrylate cement used for vertebroplasty [J]. Spine (Phila Pa 1976), 2003, 28(14):1555-1559.
- [19] Lai PL, Tai CL, Chen LH, et al. Cement leakage causes potential thermal injury in vertebroplasty [J]. BMC Musculoskelet Disord, 2011, 12:116.
- [20] Eriksson RA, Albrektsson T, Magnusson B. Assessment of bone viability after heat trauma. A histological, histochemical and vital microscopic study in the rabbit [J]. Scand J Plast Reconstr Surg, 1984, 18(3):261-268.
- [21] 曹建飞, 张晟, 叶海明, 等. 骨水泥聚合反应与冷却对骨骼肌热损伤的关系 [J]. 实用骨科杂志, 2014, 20(6):524-527.
CAO JF, ZHANG S, YE HM, et al. Relationship between cooling and thermal injury on skeletal muscle induced by bone cement polymerization [J]. Shi Yong Gu Ke Za Zhi, 2014, 20(6):524-527. Chinese.
- [22] Duan ZK, Zou JF, He XL, et al. Bone-filling mesh container versus percutaneous kyphoplasty in treating Kümmell's disease [J]. Arch Osteoporos, 2019, 14(1):109.
- [23] 徐林飞, 胡侦明, 江维, 等. 明胶海绵预注射在椎体成形术中预防骨水泥渗漏的体外研究 [J]. 重庆医科大学学报, 2015, 40(2):207-211.
XU LF, HU ZM, JIANG W, et al. In vitro study on prevention of bone cement leakage with gelatin sponge pre-injection during percutaneous vertebroplasty operation [J]. Chong Qing Yi Ke Da Xue Xue Bao, 2015, 40(2):207-211. Chinese.
- [24] Bhatia C, Barzilay Y, Krishna M, et al. Cement leakage in percutaneous vertebroplasty [J]. Spine (Phila Pa 1976), 2006, 31(8):915-919.
- [25] Nieuwenhuijse MJ, Muijs SPJ, van Erkel AR, et al. A Clinical comparative study on low vs. medium viscosity PMMA bone cement in percutaneous vertebroplasty: viscosity associated with cement leakage [J]. Spine J, 2010, 10(Suppl):S118-S119.
- [26] Wang C, Ma J, Zhang C, et al. Comparison of high-viscosity cement vertebroplasty and balloon kyphoplasty for the treatment of osteoporotic vertebral compression fractures [J]. Pain Physician, 2015, 18(2):E187.
- [27] Meng B, Qian M, Xia S, et al. Biomechanical characteristics of cement/gelatin mixture for prevention of cement leakage in vertebral augmentation [J]. Euro Spine J, 2013, 22(10):2249-2255.

(收稿日期:2020-10-09 本文编辑:连智华)