

钉棒系统固定结合峡部植骨融合治疗青少年腰椎峡部裂远期疗效

闫鹏,刘金辉,崔京福,郑卫东,母心灵,高旭,马玉斐,杜鹃
(郑州市第一人民医院脊柱外科,河南 郑州 450000)

【摘要】 目的:探讨腰椎后路椎弓根钉固定结合峡部植骨融合治疗青年腰椎峡部裂远期疗效。方法:回顾性分析自 2006 年 1 月至 2014 年 7 月收治 16 例采用腰椎后路椎弓根钉固定结合峡部植骨融合术治疗的单纯腰椎峡部裂不伴有腰椎滑脱的青年患者,其中男 11 例,女 5 例;年龄 18~21 岁,平均 19.3 岁;病程 12~26 个月,平均 22 个月。所有患者存在活动后腰部疼痛,严重者下床活动困难,术前 CT 证实 L₅ 峡部裂 12 例, L₄ 峡部裂 4 例,并在术后影像学证实植骨融合后取出内固定。采用腰痛视觉模拟评分法对术前、术后各时间点进行评分,采用腰椎 CT 检查评估腰椎峡部融合情况,采用腰椎 MRI 检查评估固定节段及邻近节段腰椎间盘退变情况。结果:本组 16 例患者,13 例 26 例获得完整随访,平均 96 个月;手术时间 80~105 min,平均 95 min;术中出血量 150~300 ml,平均 225 ml。所有患者手术顺利完成,无手术相关并发症发生;患者术后各时间点 VAS 评分较术前改善($P<0.01$)。术后腰椎 CT 检查均获骨性融合,融合时间 6~14 个月,平均 12 个月;腰椎 MRI 检查无邻近节段退变及固定节段间盘变性、突出等改变,术后远期无症状复发及再发峡部裂。结论:采用腰椎后路椎弓根钉固定结合峡部植骨融合治疗青年腰椎峡部裂,该术式安全、有效,融合率高,减少对正常生理活动范围的干扰,长期疗效满意。

【关键词】 腰椎; 骨折; 脊柱融合术; 骨折固定术

中图分类号:R687

DOI:10.3969/j.issn.1003-0034.2019.12.018

开放科学(资源服务)标识码(OSID):



Long term outcome of posterior lumbar pedicle screw fixation combined with isthmus bone graft fusion in the treatment of lumbar spondylolysis in young patients YAN Peng, LIU Jin-hui, CUI Jing-fu, ZHENG Wei-dong, MU Xin-ling, GAO Xu, MA Yu-fei, and DU Juan. Department of Spinal Surgery, the First People's Hospital of Zhengzhou, Zhengzhou 450000, Henan, China

ABSTRACT Objective: To investigate the long-term effect of posterior lumbar pedicle screw fixation combined with isthmus bone grafting and fusion in young patients with spondylolysis. **Methods:** A retrospective study was carried out, consisting of 16 young patients with lumbar spondylolysis without spondylolisthesis treated by lumbar posterior pedicle screw fixation combined with isthmus bone grafting fusion from January 2006 to July 2014. There were 11 males and 5 females, aged from 18 to 21 years old, with an average age of 19.3 years old, and the course of disease ranged from 12 to 26 months, with an average of 22 months. All the patients suffered from lumbar pain and difficulty in getting out of bed. Preoperative CT confirmed 12 cases of L₅ isthmus fissure and 4 cases of L₄ isthmus fissure. Bone graft fusion was confirmed and internal fixation was removed after operation. Lumbar spondylolysis was evaluated by lumbago visual analogue scoring method at preoperative and postoperative time points. Lumbar isthmus fusion was evaluated by lumbar CT, and degeneration of fixed and adjacent segments of lumbar intervertebral disc was evaluated by lumbar MRI. **Results:** Of the 16 patients, 13 patients (26 sides) were followed up, with a mean duration of 96 months. The operation time ranged from 80 to 105 minutes, with an average of 95 minutes. The intraoperative bleeding volume ranged from 150 to 300 ml, with an average of 225 ml. All the patients were successfully operated without any complications related to the operation. VAS scores at each time point after operation were improved compared with those before operation ($P<0.01$). Postoperative CT scans of lumbar spine showed osseous fusion at 6 to 14 months, with an average of 12 months. There were no changes of adjacent segment degeneration, fixed segment disc degeneration and protrusion on lumbar spine MRI, and no symptomatic recurrence or recurrent spondylolysis in the long term. **Conclusion:** The posterior lumbar pedicle screw fixation combined with isthmus bone grafting and fusion is safe and effective in the treatment of young spondylolysis. The fusion rate is high and the interference of normal physiological range is reduced. The long-term effect is satisfactory.

KEYWORDS Lumbar vertebrae; Fractures; Spinal fusion; Fracture fixation

通讯作者:闫鹏 E-mail:179455419@qq.com

Corresponding author: YAN Peng E-mail: 179455419@qq.com

腰椎峡部裂是腰椎关节突间部的应力性骨折,多见于腰椎活动量大的青年,是由于反复应力刺激、偶发创伤事件或先天遗传因素所导致^[1-3]。单纯腰椎峡部裂大都没有临床症状,对于少部分腰椎活动性疼痛的患者来说系统且正规的保守治疗能使症状明显缓解,极少部分保守治疗无效的患者需手术治疗。以往对于单纯峡部裂不伴有腰椎滑脱的青年患者多采用峡部裂单纯植骨融合术结合石膏床固定、钩钉复位固定峡部植骨、经椎板空心加压螺丝张力带等等。手术目的是早期修复峡部断裂,恢复腰椎正常的生物力学结构,防止腰椎滑脱,稳定脊柱,以缓解疼痛。自 2006 年 1 月至 2014 年 7 月收治 16 例单纯峡部裂不伴有腰椎滑脱的青年患者,采用腰椎后路椎弓根钉固定结合峡部植骨融合手术方式,平均随访 8 年,临床疗效满意,现报告如下。

1 临床资料

自 2006 年 1 月至 2014 年 7 月收治 16 例青年峡部裂的患者,其中男 11 例,女 5 例;年龄 18~21 岁,平均 19.3 岁;病程 12~26 个月,平均 22 个月。均为单节段双侧峡部裂,其中 L₅ 峡部裂 12 例, L₄ 峡部裂 4 例。临床表现及影像学检查:(1)均有不同程度的活动后腰痛(病史平均 22 个月),反复发作。(2)均经过各种正规保守治疗无效,甚至加重(时间>6 个月)。(3)查体均有腰椎过伸过屈位时疼痛加重,无明显神经症状。(4)影像学检查包括腰椎正侧位、动力位 X 线、腰椎 CT 及 MRI,腰椎 CT 证实均有单节段双侧峡部裂,腰椎 X 线片未发现腰椎滑脱及动力位不稳定,腰椎 MRI 未发现腰椎间盘变性、突出改变。

2 治疗方法

全麻俯卧位,腰椎后路正中切口进入,依次切开皮肤、皮下组织、深筋膜,从正中向两侧剥离骶棘肌,

暴露峡部裂所在节段;C 形臂 X 线机下确认拟固定节段的椎板和关节突关节,注意电刀烧灼时务必保护好关节突关节的完整。双侧置入椎弓根螺钉后安装预弯棒,咬除峡部裂处瘢痕组织,用电动磨钻清除峡部断端硬化骨质。在髂后上棘处取松质骨充分植骨(植骨量尽可能多),取骨处用明胶海绵填充。安装连接棒,冲洗切口,留置引流管根,逐层缝合,术后常规预防感染治疗,术后 48 h 拔除引流管,术后 7 d 戴支具下床活动,14 d 后皮肤切口甲级愈合后拆线。术后定期复查腰椎 CT,当腰椎峡部裂植骨完全融合时及时取出内固定。

3 结果

3.1 疗效评价

所有患者在术后 1 周及 6、12、48 个月,末次随访时进行影像学检查,包括腰椎正侧位 X 线、腰椎 CT 及 MRI,评估内固定位置、融合及邻近节段退变情况。疼痛评分采用腰痛视觉模拟评分法(VAS)评估:0 分为无痛,1~3 分为轻度疼痛,4~6 分为中度疼痛,7~10 分为重度疼痛^[4]。

3.2 治疗结果

本组 16 例中 13 例获完整影像学随访,时间 48~143 个月,平均 96 个月。16 例手术时间 80~105 min,平均 95 min;术中出血量 150~300 ml,平均 225 ml。所有患者手术顺利完成,术后切口均甲级愈合,无手术相关并发症发生。完整随访的 13 例患者 VAS 评分,术前 6.93±0.96,术后 1 周 4.41±1.13,术后 6 个月 2.21±0.48,术后 12 个月 1.19±0.32,术后 8 年末次随访时 0.93±0.25。术后腰椎 CT 证实 13 例 26 侧均获骨性融合,融合时间 6~14 个月,平均 12 个月,无断钉断棒、内固定松动发生。腰椎 MRI 示无邻近节段退变及固定节段间盘变性、突出等改变,取出内固定后无症状复发。典型病例图片见图 1。

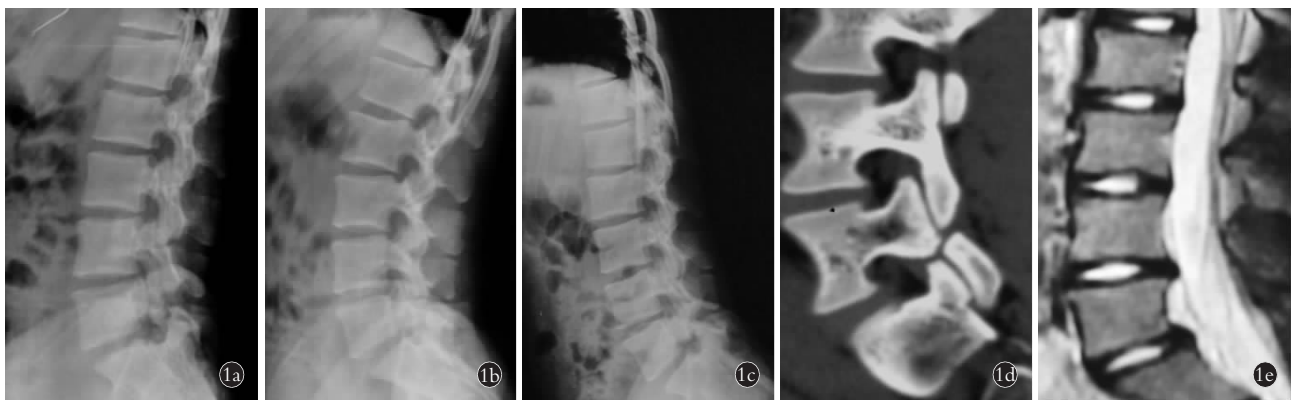


图 1 患者,男,18 岁,L₅ 峡部裂,腰椎无滑脱 1a. 术前侧位 X 线片 1b. 术前过伸位 X 线片 1c. 术前过屈位 X 线片 1d. 术前 CT 重建片 1e. 术前 MRI

Fig.1 Male, 18-year-old, L₅ narrow cleft, no lumbar spondylolisthesis 1a. Preoperative lateral X-ray 1b. Preoperative overextension X-ray 1c. Preoperative hyperflexion X-ray 1d. Preoperative CT reconstruction 1e. Preoperative MRI

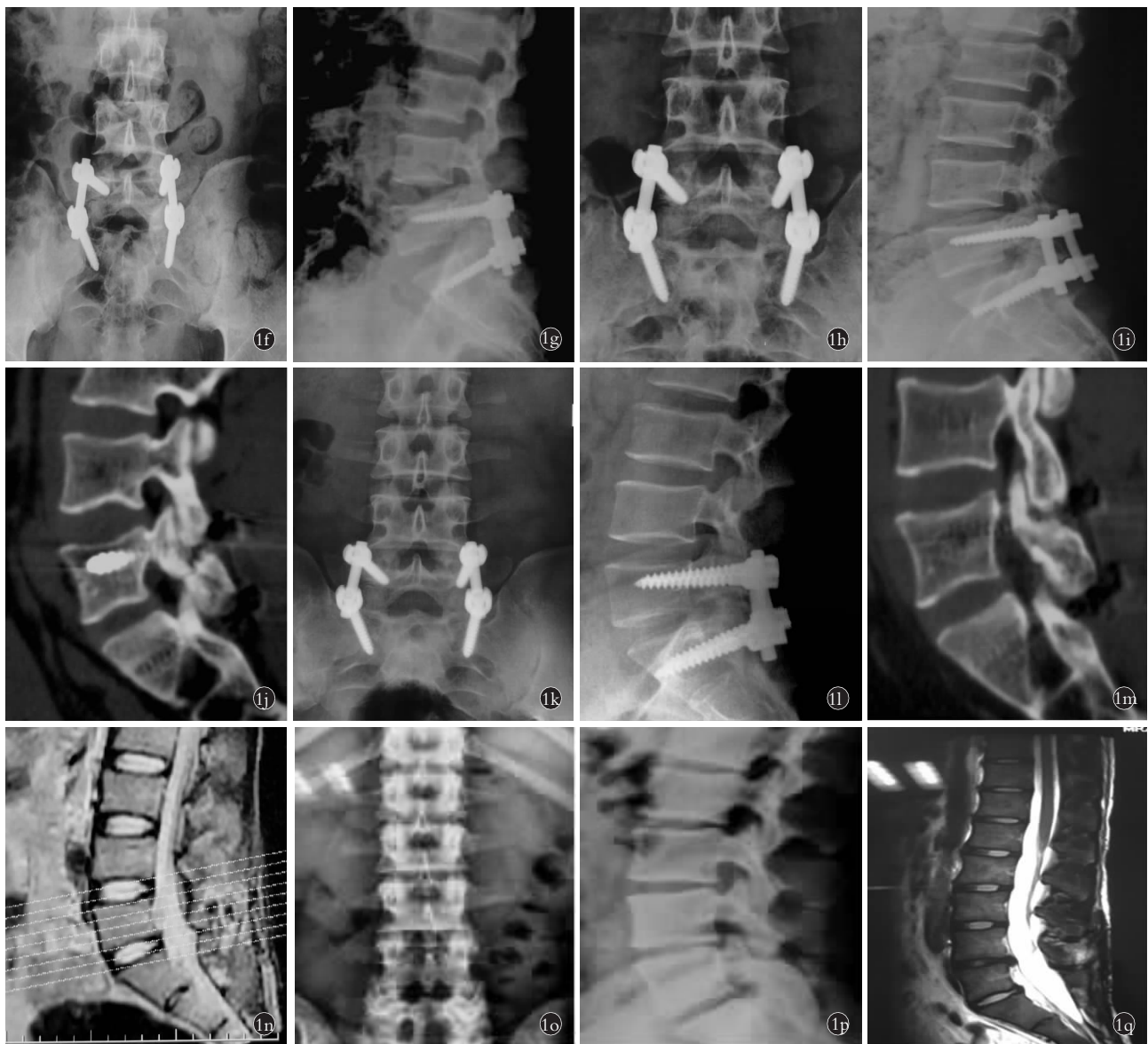

图 1 患者,男,18 岁,L₅ 峡部裂,腰椎无滑脱 1f. 术后 1 周正位 X 线片见内固定在位良好 1g. 术后 1 周侧位 X 线片见内固定在位良好 1h. 术后 6 个月正位 X 线片见内固定在位良好,螺钉无松动 1i. 术后 6 个月侧位 X 线片见内固定在位良好,螺钉无松动 1j. 术后 6 个月腰椎 CT 重建见峡部未完全融合 1k. 术后 12 个月腰椎正位 X 线片见内固定在位良好,螺钉无松动 1l. 术后 12 个月腰椎侧位 X 线片见内固定在位良好,螺钉无松动 1m. 术后 12 个月腰椎 CT 重建见峡部完全融合 1n. 术后 12 个月腰椎 MRI 无病变节段及相邻节段退变 1o. 术后 8 年,内固定已去除,腰椎稳定,序列正常 1p. 术后 8 年,内固定已去除,序列正常,无退变及峡部再发骨折 1q. 术后 8 年,腰椎 MRI 见 L₅S₁ 间盘信号正常

Fig.1 Male, 18-year-old, L₅ narrow cleft, no lumbar spondylolisthesis 1f. AP X-ray showed that internal fixation was in good position 1 week after operation 1g. Lateral X-ray film showed good internal fixation 1 week after operation 1h. AP X-ray showed good internal fixation and no loosening of screw 6 months after operation 1i. Six months after operation, lateral X-ray showed good internal fixation and no loosening of screw 1j. CT reconstruction of lumbar spine 6 months after operation showed incomplete fusion of isthmus 1k. AP X-ray film of lumbar spine 12 months after operation showed good internal fixation and no loosening of screw 1l. Lateral X-ray of lumbar spine 12 months after operation showed good internal fixation and no loosening of screw 1m. CT reconstruction of lumbar spine 12 months after operation showed complete isthmic fusion 1n. No lesion and adjacent segment degeneration of lumbar spine on MRI 12 months after operation 1o. Eight years after operation, the internal fixation was removed, the lumbar spine was stable and the sequence was normal 1p. Eight years after operation, the internal fixation was removed, the sequence was normal, no degeneration and recurrent isthmic fracture occurred 1q. Eight years after operation, the signal of L₅S₁ intervertebral disc was normal on lumbar MRI

4 讨论

椎弓峡部裂是指腰椎峡部单侧或双侧的骨质缺损,最常见于下腰椎,好发于参与某项运动或活动的

青少年。据统计,该病发病率为 3%~10%,10~20 岁发病率随年龄增加而增加,但 20 岁以后,发病率没有变化^[5]。椎弓峡部裂可以是无症状的,也可以伴有

脊柱不稳导致的背痛和神经根性疼痛。目前,腰椎峡部裂的病因尚有争议,涉及多种因素,包括解剖因素、先天遗传因素、疲劳性或慢性劳损因素、退变性因素及创伤性等^[6]。椎弓峡部裂主要累及 L₅ 椎体(95%)^[7-8],90%为双侧^[9],从而将腰椎分成两部分。上段由带椎弓根的椎体、横突和上关节突组成,下段由下关节突、椎板和棘突组成。峡部裂引起下腰痛的原因主要是由于峡部裂处的微动导致局部不稳而刺激该处的神经末梢所致。

椎弓峡部裂保守治疗包括休息、支具、物理治疗、临时限制活动、镇痛等,但对于一些经过 6 个月系统保守治疗无效的患者仍需采用手术治疗。以往对于此类患者,多采用单纯峡部缺损修复结合石膏床固定,但患者峡部植骨不融合率很高,且一部分患者不能忍受长期卧床。近年来,随着脊柱内固定器械的更新发展,出现了椎弓根钉-椎板钩系统及经椎板空心加压螺丝张力带等手术方式。这两种术式优势在于单节段内固定以及骨性愈合,减少对正常生理活动范围的干扰;恢复腰椎的正常解剖连续性和生理功能的同时,避免了相邻节段退变的产生或加剧已有的退变。赵喜滨等^[10]报道 19 例采用椎弓根钉-椎板钩系统固定治疗青年峡部裂,平均随访 22.3 个月,19 例椎弓根峡部均获得骨性融合,未见骨不连及内固定断裂,术后腰椎疼痛明显缓解。谭健等^[11]报道应用钉钩系统联合峡部植骨融合治疗青年峡部裂,最长随访 42 个月,优良率达 93.3%。朱敏等^[12]报道了 15 例 30 侧采用经椎板空心螺丝张力带治疗青年峡部裂,随访 12~36 个月,患者疼痛症状明显缓解,峡部裂处植骨骨性愈合,未见内固定松动及断裂。本组 16 例 32 侧患者采用腰椎后路椎弓根钉固定结合峡部植骨融合,术后 1 年复查腰椎 CT,均获得骨性融合,术后下腰痛症状缓解,内固定去除后长期随访中峡部融合满意,未再断裂、滑脱,无相邻节段退变等发生。

手术要点:术中置钉时特别注意保护关节突关节完整性,避免远期关节突关节自发融合及医源性不稳的发生;为获得确切的骨性融合,术中彻底充分去除峡部瘢痕组织及硬化骨;充分的自体骨植骨,尽可能多的植骨接触面以及植骨床与移植骨间的紧密接触,是提高植骨融合的关键;为避免青年患者腰背部僵硬、失去活动度,骨性融合后及时取出内固定。该手术方式的优点在于手术操作简单,椎弓根螺钉价格低廉,易于获取,安全经济,易于在基层医院推

广;椎弓根钉棒系统生物力学较其他内固定稳定,患者可早期下床活动。

综上所述,采用腰椎后路椎弓根钉固定结合峡部植骨融合治疗青年峡部裂,该术式安全、有效,长期疗效满意。

参考文献

- [1] Winter M, Jani L. Results of screw osteosynthesis in spondylolysis and low-grade spondylolisthesis[J]. Arch Orthop Trauma Surg, 1989, 108(2): 96-99.
- [2] Wiltse LL, Widell EH Jr, Jackson DW. Fatigue fracture: the basic lesion is isthmic spondylolisthesis[J]. J Bone Joint Surg Am, 1975, 57(1): 17-22.
- [3] Sakai T, Goda Y, Tezuka F, et al. Characteristics of lumbar spondylolysis in elementary school age children[J]. Eur Spine J, 2016, 25: 602-606.
- [4] Crichton N. Visual analogue scale (VAS)[J]. J Clin Nurs, 2001, 10(5): 706.
- [5] Lemoine T, Fournier J, Odent T, et al. The prevalence of lumbar spondylolysis in young children: a retrospective analysis using CT[J]. Eur Spine J, 2018, 27(5): 1067-1072.
- [6] Andrade NS, Ashton CM, Wray NP, et al. Systematic review of observational studies reveals no association between low back pain and lumbar spondylolysis with or without isthmic spondylolisthesis[J]. Eur Spine J, 2015, 24(6): 1289-1295.
- [7] Sakai T, Sairyu K, Suzue N, et al. Incidence and etiology of lumbar spondylolysis: review of the literature[J]. J Orthop Sci, 2010, 15: 281-288.
- [8] Grogan JP, Hemminghytt S, Williams AL, et al. Spondylolysis studied with computed tomography[J]. Radiology, 1982, 145: 737-742.
- [9] Teplick JG, Lafley PA, Berman A, et al. Diagnosis and evaluation of spondylolisthesis and/or spondylolysis on axial CT[J]. AJNR Am J Neuroradiol, 1986, 7: 479-491.
- [10] 赵喜滨, 徐万龙, 袁宏. 椎弓根钉-椎板钩系统固定治疗青年腰椎峡部裂的疗效分析[J]. 北京医学, 2012, 34(10): 878-880. ZHAO XB, XU WL, YUAN H. Curative effect of treating the adolescent lumbar spondylolysis by a pedicle screw-lamina hook system[J]. Bei Jing Yi Xue, 2012, 34(10): 878-880. Chinese.
- [11] 谭健, 李平元, 欧军, 等. 峡部植骨融合联合节段内钉-钩系统内固定术治疗青年腰椎峡部裂[J]. 中国现代医学杂志, 2014, 24(19): 92-95. TAN J, LI PY, OU J, et al. Interarticular bone graft fusion and intrasegmental fixation with pedicle screw-lamina hook system in treatment of young lumbar spondylolysis[J]. Zhong Guo Xian Dai Yi Xue Za Zhi, 2014, 24(19): 92-95. Chinese.
- [12] 朱敏, 徐永清, 丁晶, 等. 经椎板空心加压螺丝张力带治疗青年腰椎峡部裂[J]. 中国矫形外科杂志, 2011, 19(21): 1830-1831. ZHU M, XU YQ, DING J, et al. Treatment of young lumbar spondylolysis with hollow compression screw tension belt[J]. Zhongguo Jiao Xing Wai Ke Za Zhi, 2011, 19(21): 1830-1831. Chinese.

(收稿日期: 2019-03-23 本文编辑: 连智华)