

- [7] Chen YJ, Chen WH, Chen HT, et al. Repeat needle insertion in vertebroplasty to prevent re-collapse of the treated vertebrae [J]. Eur J Radiol, 2012, 81(3): 558-561.
- [8] Jensen ME, Evans AJ, Mathis JM, et al. Percutaneous polymethylmethacrylate vertebroplasty in the treatment of osteoporotic vertebral body compression fractures: technical aspects [J]. Am J Neuro-radiol, 1997, 18: 1897-1904.
- [9] Yeom JS, Kim WJ, Choy WS, et al. Leakage of cement in percutaneous transpedicular vertebroplasty for painful osteoporotic compression fractures [J]. J Bone Joint Surg Br, 2003, 85(1): 83-89.
- [10] 隋福革, 李恒, 赵丛然, 等. 经皮椎体后凸成形术治疗骨质疏松性椎体压缩骨折的并发症分析 [J]. 中国脊柱脊髓杂志, 2012, 22(11): 984-988.  
SUI FG, Li H, ZHAO CR, et al. Analysis of complications of kyphoplasty for osteoporotic vertebral compression fractures [J]. Zhongguo Ji Zhu Ji Sui Za Zhi, 2012, 22(11): 984-988. Chinese.
- [11] Lavelle WF, Cheney R. Recurrent fracture after vertebral kyphoplasty [J]. Spine J, 2006, 6(5): 488-493.
- [12] Hey HW, Tan JH, Tan CS, et al. Subsequent vertebral fractures post cement augmentation of the thoracolumbar spine: Does it correlate with level-specific bone mineral density scores [J]. Spine (Phila Pa 1976), 2015, 40(24): 1903-1909.
- [13] Yoo CM, Park KB, Hwang SH, et al. The analysis of patterns and risk factors of newly developed vertebral compression fractures after percutaneous vertebroplasty [J]. J Korean Neurosurg Soc, 2012, 52(4): 339-345.
- [14] Lin WC, Lee YC, Lee CH, et al. Refractures in cemented vertebrae after percutaneous vertebroplasty: a retrospective analysis [J]. Euro Spine J, 2008, 17(4): 592-599.
- [15] 叶林强, 梁德, 姚珍松, 等. 靶向椎体成形术与传统椎体成形术治疗骨质疏松性椎体压缩骨折的疗效比较 [J]. 中华创伤杂志, 2017, 33(3): 247-252.  
YE LQ, LIANG D, YAO ZS, et al. Efficacy comparison between targeted and conventional percutaneous vertebroplasty of osteoporotic vertebral compression fractures [J]. Zhonghua Chuang Shang Za Zhi, 2017, 33(3): 247-252. Chinese.

(收稿日期: 2019-01-12 本文编辑: 王宏)

## 三维 CT 及影像学分型在骨质疏松骨折椎体成形术中的应用

王成胜<sup>1</sup>, 刘爱国<sup>1</sup>, 刘成洲<sup>1</sup>, 田军<sup>2</sup>

(1. 临朐县人民医院, 山东 临朐 262600; 2. 山东省医学影像学研究所, 山东 济南 250000)

**【摘要】** 目的: 探讨三维 CT 及影像学分型在骨质疏松性椎体压缩骨折(OVCFs)患者经椎体成形术(PVP)治疗中的应用。方法: 选取 2016 年 4 月至 2018 年 3 月在山东省临朐县人民医院住院行 PVP 治疗的 90 例 OVCFs 患者作为研究对象, 其中男 31 例, 女 59 例; 年龄 63~84(72.33±10.12)岁。对患者进行骨矿物质密度测量以确认骨质疏松症的存在, 并且进行成像检查以确认椎体骨折的存在。术前通过 MRI 抑脂像确定骨折的区域, 并进行三维建模, 计算骨折区域的体积。于 PVP 术后对骨折区域内的骨水泥进行三维 CT 成像, 应用计算机辅助设计软件, 计算骨水泥在骨折区的体积比, 然后分组研究。骨水泥在骨折区的体积比<50%的患者为对照组(41 例); 骨水泥在骨折区的体积比≥50%的患者为观察组(49 例)。观察两组患者术前、术后 1 d、术后 3 个月的疼痛视觉模拟评分(VAS)、Oswestry 功能障碍指数(ODI), 记录两组患者的骨水泥用量。结果: 所有患者顺利完成手术, 对照组发生骨水泥渗漏 3 例, 观察组 4 例, 患者均无明显临床症状。术后持续观察并随访 3 个月, 无邻近椎体骨折、感染、骨水泥移位等并发症出现。两组患者骨水泥用量及骨水泥渗漏比较差异无统计学意义( $P>0.05$ )。两组患者术前 VAS 和 ODI 评分比较差异无统计学意义( $P>0.05$ ); 术后 1 d 两组患者的 VAS 和 ODI 评分均显著降低( $P<0.05$ ), 并且观察组下降更明显( $P<0.05$ ); 术后 3 个月 ODI 和 VAS 评分两组差异无统计学意义( $P>0.05$ ), 可能与术后 3 个月左右椎体骨折已基本愈合, 疼痛不再明显有关。结论: PVP 可明显改善 OVCFs 的临床症状, 骨折区域的骨水泥填充情况是影响 PVP 术后近期疗效的关键。

**【关键词】** 骨质疏松性椎体压缩骨折; 计算机辅助三维成像; 骨水泥分布

中图分类号: R683.2

DOI: 10.3969/j.issn.1003-0034.2019.07.010

开放科学(资源服务)标识码(OSID): 

**Application of three-dimensional CT and image classification in percutaneous vertebroplasty for osteoporotic vertebral compression fractures** WANG Cheng-sheng, LIU Ai-guo, LIU Cheng-zhou\*, and TIAN Jun. \*Linqu People's Hospital

通讯作者: 刘成洲 E-mail: liuchengzhou@126.com

Corresponding author: LIU Cheng-zhou E-mail: liuchengzhou@126.com

of Shandong, Linqu 262600, Shandong, China

**ABSTRACT Objective:** To explore the application of three-dimensional CT and image classification in the treatment of osteoporotic vertebral compression fracture(OVCFs) by percutaneous vertebroplasty(PVP). **Methods:** A total of 90 patients with OVCFs who were treated with PVP in Linqu People’s Hospital of Shandong Province from April 2016 to March 2018 were selected as subjects. There were 31 males and 59 females, aged from 63 to 84 years old. Bone mineral density measurements were performed in all patients to confirm the presence of osteoporosis and imaging examinations were performed to confirm the presence of vertebral fractures. The fracture area was determined by MRI fat suppressed image before operation and three-dimensional modeling was performed to calculate the volume of fracture area. Three dimensional CT imaging of bone cement in fracture area was performed after PVP and the volume ratio of bone cement in fracture area was calculated by computer aided design software, by which patients were divided into groups for study. Forty-one patients whose volume ratio of bone cement in fracture area less than 50% are control group and the rest of 90 patients are observation group. Visual analogue scale (VAS) and Oswestry Disability Index (ODI) were collected in two groups before operation and 1 day, 3 months after operation. The amount of bone cement was recorded after operation. **Results:** All operations were successful. There were 3 cases of cement leakage in control group and 4 cases in observation group. All patients had no obvious clinical symptoms. After continuous observation and follow-up for 3 months, no complications such as adjacent vertebral fracture, infection, bone cement displacement were found. There was no significant difference in bone cement doses and bone cement leakage between two groups ( $P>0.05$ ). There was no significant difference in preoperative VAS and ODI between two groups ( $P>0.05$ ). All VAS and ODI obviously decreased( $P<0.05$ ) at 1 day after operation and in observation group the decrease was more significant ( $P<0.05$ ). At 3 months after operation there was no significant difference between two groups. This may have been due to basically healing of vertebral fractures at 3 months after surgery and the pain was no longer significantly related. **Conclusion:** PVP can significantly improve clinical symptoms of OVCFs and bone cement filling in fracture area is the key to the short-term effect of PVP.

**KEYWORDS** Osteoporotic vertebral compression fractures; Computer-assisted three-dimensional imaging; Bone cement distribution

骨质疏松患者易发生骨折，其中脊柱骨折最为常见，又称之为骨质疏松性椎体压缩骨折(osteoporotic vertebral compression fractures, OVCFs)。以往对于 OVCFs 多采用卧床休息等保守治疗，但这样反而会加重骨质疏松的进程。有统计显示<sup>[1]</sup>，老年人卧床 1 周丢失的钙量占全身总钙量的 1%，相当于正常人 1 年丢失的钙量。近年来，随着显微外科的不断发展，经皮椎体成形术(percutaneous vertebroplasty, PVP)已成为目前治疗 OVCFs 的首选方法<sup>[2]</sup>。它通过将骨水泥注入骨折椎体的方法，增加椎体强度，迅速缓解疼痛，使患者早期即可下床活动。然而，并非所有患者都能获得满意疗效，对于骨水泥用量及骨水泥在骨折区域的分布情况对疗效的影响报道较少，也没有统一的分类标准<sup>[3]</sup>。笔者对 2016 年 4 月至 2018 年 3 月行 PVP 治疗的 90 例 OVCFs 患者进行了回顾性分析，旨在通过影像三维成像技术及计算机辅助软件对骨折区域的骨水泥进行研究，观察骨水泥在骨折区域的体积分布情况及对临床疗效的影响。

### 1 资料与方法

#### 1.1 病例选择

纳入标准:(1)符合骨质疏松诊断并发生单椎体骨折。(2)椎体压缩程度 $\leq 2/3$ 。(3)临床资料完整。(4)均行 PVP 治疗。(5)患者均签署知情同意书，并经医院伦理委员会批准。排除标准:(1)多发椎体骨折患者。(2)有脊髓受压及神经根症状者。(3)行 PKP

治疗者。(4)三柱损伤的患者。(5)除骨质疏松以外其他骨病如:强直性脊柱炎等所致的椎体骨折。(6)椎体转移瘤等病理骨折的患者。

#### 1.2 一般资料

本组 90 例，其中男 31 例，女 59 例，年龄 63~84(72.33±10.12)岁。根据术后骨水泥在骨折区的体积比进行分组研究。对照组 41 例，骨水泥在骨折区的体积比 $<50\%$ 。观察组 49 例，骨水泥在骨折区的体积比 $\geq 50\%$ 。两组患者在年龄、性别、骨密度值等一般资料方面差异无统计学意义( $P>0.05$ )，见表 1。

#### 1.3 研究方法

术前通过 MRI 抑脂像确定骨折的区域，并进行三维建模，通过应用 CAD 软件对 MRI 抑脂像矢状面每层椎体的骨折区面积计算，然后乘以每层厚度，进而计算出骨折区域的体积。在 PVP 术后，对骨水泥进行三维 CT 成像，应用计算机辅助设计软件，对骨折区域进行叠加，计算出骨水泥在骨折区的体积比，然后分组研究(图 1)。对照组:骨水泥在骨折区的体积比 $<50\%$ 。观察组:骨水泥在骨折区的体积比 $\geq 50\%$ 。典型病例见图 2,3。

#### 1.4 观察项目与方法

记录两组患者术前及术后 1 d、术后 3 个月的疼痛视觉模拟评分(visual analogue scale, VAS)及 Oswestry 功能障碍指数(Oswestry Disability Index, ODI)情况，同时记录两组患者的骨水泥用量。

表 1 两组骨质疏松性椎体压缩性骨折患者术前一般资料比较

Tab.1 Comparison of preoperative general data of patients with osteoporotic vertebral compression fractures between two groups

项目	例数	年龄( $\bar{x}\pm s$ , 岁)	性别(例)		病程( $\bar{x}\pm s$ , d)	BMI( $\bar{x}\pm s$ , kg/m <sup>2</sup> )	骨密度 T 值( $\bar{x}\pm s$ , g/cm <sup>3</sup> )
			男	女			
对照组	41	73.61±10.47	14	27	6.31±5.21	24.31±4.58	-3.82±1.31
观察组	49	71.12±10.25	17	32	6.14±5.76	25.21±5.12	-3.77±1.26
检验值		$t=0.45$	$\chi^2=1.57$		$t=0.46$	$t=1.55$	$t=0.66$
P 值		0.23	0.38		0.34	0.17	0.21

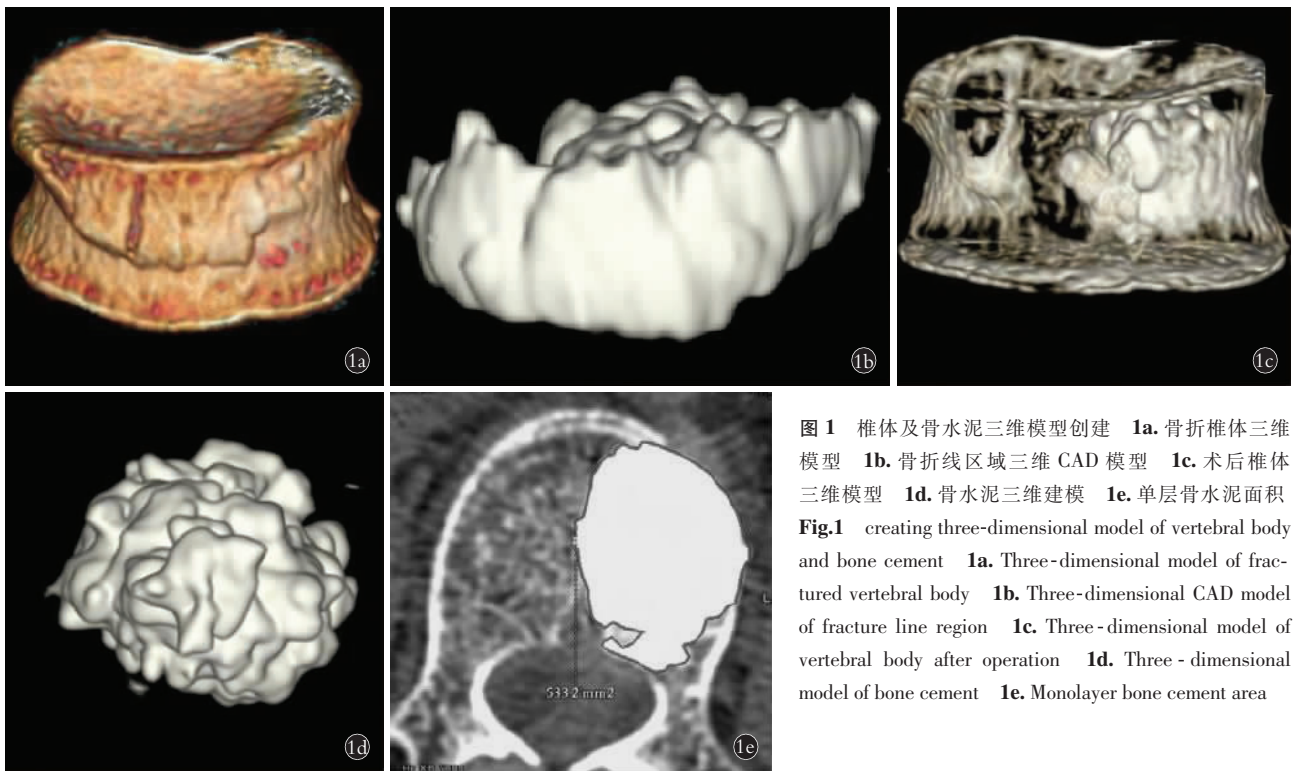


图 1 椎体及骨水泥三维模型创建 1a. 骨折椎体三维模型 1b. 骨折线区域三维 CAD 模型 1c. 术后椎体三维模型 1d. 骨水泥三维建模 1e. 单层骨水泥面积  
Fig.1 creating three-dimensional model of vertebral body and bone cement 1a. Three-dimensional model of fractured vertebral body 1b. Three-dimensional CAD model of fracture line region 1c. Three-dimensional model of vertebral body after operation 1d. Three-dimensional model of bone cement 1e. Monolayer bone cement area

1.5 统计学处理

采用 SPSS 19.0 软件对本研究的数据进行统计分析,定量资料采用均数±标准差( $\bar{x}\pm s$ )表示,手术前后 VAS 评分、ODI 指数等组内比较采用配对样本  $t$  检验,组间比较采用独立样本  $t$  检验,性别比等计数资料采用  $\chi^2$  检验。以  $P<0.05$  为差异有统计学意义。

2 结果

所有患者顺利完成手术,对照组有 3 例发生骨水泥渗漏,观察组有 4 例出现骨水泥渗漏,均无明显临床症状。手术时间 45~105 min,平均 60 min,骨水泥用量 2.5~7.5 ml,平均胸椎 2.9 ml,腰椎 5.2 ml。术后患者疼痛均不同程度缓解。术后持续观察并随访 3 个月,无邻近椎体骨折、感染、骨水泥移位等并发症出现。

两组患者术前 VAS 评分差异无统计学意义( $P>0.05$ ),术后两组 VAS 评分均显著降低,其中在术后

1 d,观察组疗效明显优于对照组( $P<0.05$ )。术后 3 个月时两组 VAS 评分差异无统计学意义。见表 2。

两组患者术前 ODI 指数差异无统计学意义( $P>0.05$ ),术后两组 ODI 指数均显著降低,其中在术后 1 d,观察组疗效明显优于对照组( $P<0.05$ )。术后 3 个月时两组 ODI 评分差异无统计学意义。见表 3。

两组患者在骨水泥用量方面差异无统计学意义。说明:骨水泥在骨折线附近的分布是否良好,与骨水泥用量无直接关系( $P>0.05$ )。对照组有 3 例发生骨水泥渗漏,观察组有 4 例出现骨水泥渗漏,两组比较差异无统计学意义( $P>0.05$ ),见表 4。典型病例骨水泥渗漏情况见图 4,5。

3 讨论

3.1 MRI 在 OVCFs 诊断中的应用

骨质疏松症属于一种全身代谢性疾病,主要表现为骨密度和骨质量下降,骨微结构破坏,脆性增



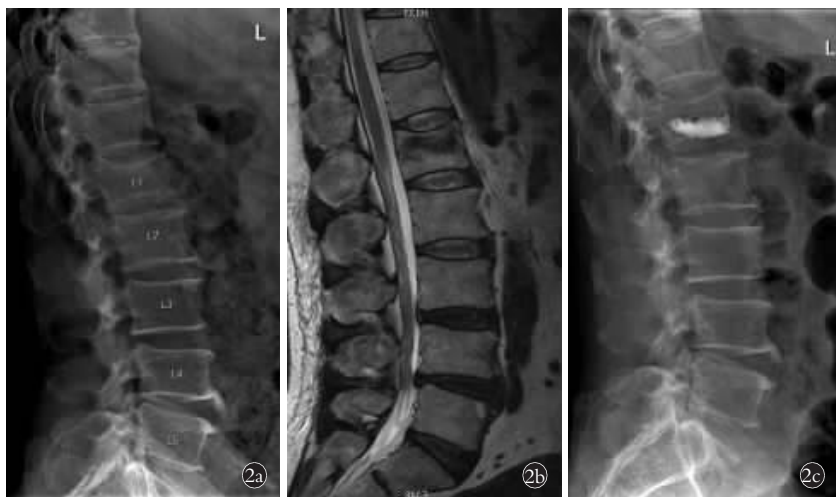

图 2 患者,男,66 岁,跌倒致腰部疼痛 2 d 住院 2a. 术前侧位 X 线示 L<sub>1</sub> 椎体压缩性骨折 2b. 术前 MRI 示骨折线位于椎体中上部 2c. 术后 X 线显示骨水泥位置偏下,通过计算发现骨水泥在骨折线区域分布范围<50%,纳入对照组

**Fig.2** A 66-year-old male patient who has lumbar pain for 2 days because of falling was admitted to hospital 2a. Preoperative lateral X-ray showed L<sub>1</sub> vertebral compression fracture 2b. Preoperative MRI showed the fracture line was located on the upper middle part of the vertebral body 2c. Postoperative X-ray showed the position of the cement was lower and through calculation the distribution of bone cement on the fracture line area was found to be less than 50%, and included in control group

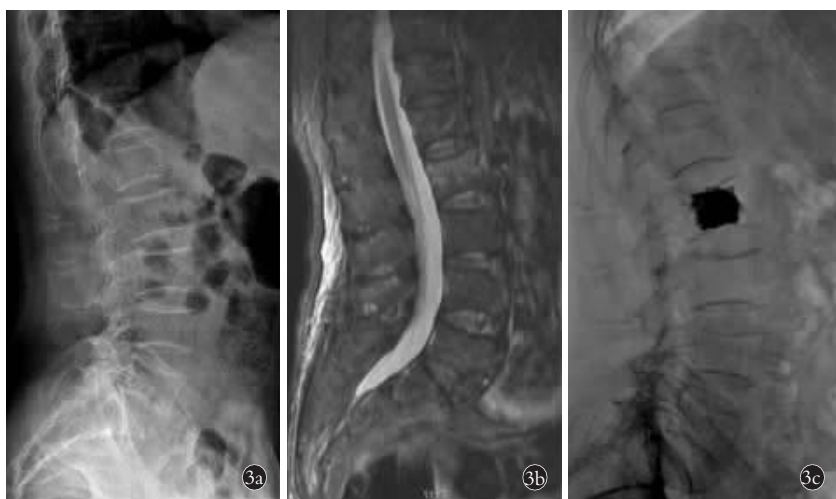

图 3 患者,男,67 岁,因腰痛 10 d 入院 3a. 术前 X 线检查提示 L<sub>2</sub> 椎体压缩性骨折 3b. 术前 MRI 提示骨折线位于椎体中上部 3c. 术后 X 线显示骨水泥充满整个椎体。通过计算发现骨水泥在骨折线区域分布范围>50%,纳入观察组

**Fig.3** A 67-year-old male patient with lumbar pain for 10 days was admitted to hospital 3a. Preoperative X-ray showed L<sub>2</sub> vertebral compression fracture 3b. Preoperative MRI showed the fracture line was located on the upper middle part of the vertebral body 3c. Postoperative X-ray showed bone cement filled the entire vertebral body. The distribution of bone cement on the fracture line area was more than 50% by calculation, and included in the observation group

加,易发生骨折。其中脊柱骨折最为常见,其次为髋部及手腕。骨质疏松患者骨折之后发生再次骨折的风险较高。Kuiper 等<sup>[4]</sup>研究发现,OVCFs 患者有 20% 在第 1 年内会再次发生骨折,在其后的 10 年,有约

80% 会再次发生骨折。OVCFs 的早期诊断至关重要,它可在没有外伤或者轻微外伤情况下出现,部分患者仅表现为轻度腰痛,此时 X 线及 CT 可无明显异常。此时,如果不及时进行干预,骨折椎体可逐渐受压变扁,出现楔形改变<sup>[5]</sup>。随着 MRI 技术的发展,使得 OVCFs 的早期诊断变的更加成熟,通过 MRI 检查可以发现没有外形改变的早期骨折<sup>[6]</sup>。此外, MRI 还可用于鉴别新鲜骨折还是陈旧性骨折,在 MRI 抑脂像中新骨折呈高信号,而陈旧性骨折则呈低信号<sup>[7]</sup>。

### 3.2 椎体成形术技术的应用

以往对于 OVCFs 的治疗以保守治疗为主,但会进一步加重骨质疏松,形成恶性循环。而通过前路或后路切开植骨内固定手术治疗,常因患者年龄大、体质差,椎体骨质疏松严重,导致内固定稳定性差,且开放手术风险性高,创伤大,不容易被老年患者接受<sup>[8]</sup>。椎体成形术是脊柱外科领域的一种微创手术,是由法国医学家发明的,首先在欧洲,然后是在美国逐步得到应用,目前已成为治疗骨质疏松性椎体压缩骨折的首选手术方法<sup>[9]</sup>。它通过向骨折椎体内注入骨水泥的方式,可迅速固化椎体,增加椎体强度及稳定性,术后疼痛缓解明显,可早期下床活动,避免骨质疏松进一步加重,明显改善患者的自理能力及生活质量<sup>[10]</sup>。然而,并非所有患者在椎体成形术后都能获得满意的效果,椎体成形术对临床疗效的影响因素还不明确。

### 3.3 骨水泥分布与疗效的关系

对于骨水泥在椎体中的分布情况与临床疗效的关系,尚存在一定争议<sup>[11]</sup>。Senturk 等<sup>[12]</sup>认为只要骨水泥到达上下椎板,即可获得满意疗效,而与骨折区域的位置无关。研究发现<sup>[13]</sup>,只要骨折区域骨水泥分布良好,即可获得满意疗效。对于骨折区域的划分及疗效判定,

一定争议<sup>[11]</sup>。Senturk 等<sup>[12]</sup>认为只要骨水泥到达上下椎板,即可获得满意疗效,而与骨折区域的位置无关。研究发现<sup>[13]</sup>,只要骨折区域骨水泥分布良好,即可获得满意疗效。对于骨折区域的划分及疗效判定,

**表 2 两组骨质疏松性椎体压缩骨折患者手术前后 VAS 评分比较 ( $\bar{x} \pm s$ , 分)**

**Tab.2 Comparison of pre-and post-operative VAS score between two groups with osteoporotic vertebral compression fractures ( $\bar{x} \pm s$ , score)**

组别	例数	术前	术后 1 d	术后 3 个月
对照组	41	7.41±1.02	4.51±0.78*	1.44±0.52*
观察组	49	7.32±1.14	2.62±0.84*	1.22±0.47*
<i>t</i> 值		0.75	2.71	1.42
<i>P</i> 值		0.87	0.00	0.34

注:与术前比较, \**P*<0.05

Note: Compared with preoperative data, \**P*<0.05

**表 3 两组骨质疏松性椎体压缩骨折患者手术前后 ODI 指数比较 ( $\bar{x} \pm s$ , 分)**

**Tab.3 Comparison of pre-and post-operative ODI index between two groups with osteoporotic vertebral compression fractures ( $\bar{x} \pm s$ , score)**

组别	例数	术前	术后 1 d	术后 3 个月
对照组	41	91.22±1.97	69.23±2.71*	18.12±2.41*
观察组	49	90.88±2.12	47.85±2.14*	18.75±2.26*
<i>t</i> 值		0.68	3.02	1.87
<i>P</i> 值		0.55	0.00	0.44

注:与术前比较, \**P*<0.05

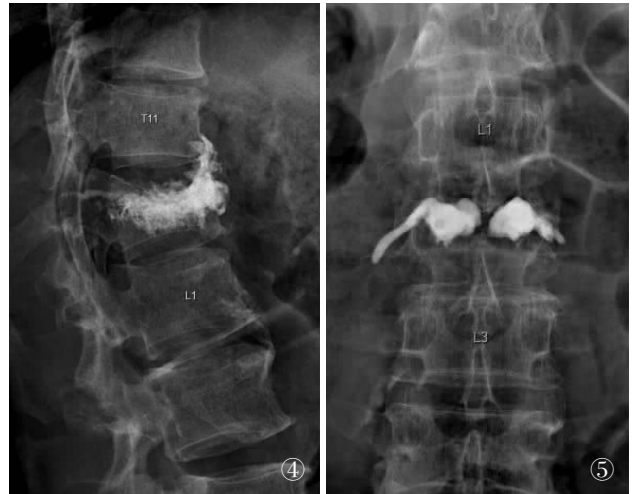Note: Compared with preoperative data, \**P*<0.05

**表 4 两组骨质疏松性椎体压缩骨折患者骨水泥用量及渗漏情况比较**

**Tab.4 Comparison of bone cement dosage and leakage between two groups with osteoporotic vertebral compression fractures**

组别	例数	骨水泥用量( $\bar{x} \pm s$ , ml)	骨水泥渗漏[例(%)]
对照组	41	4.27±1.74	3(7.31)
观察组	49	4.33±1.67	4(8.16)
检验值		<i>t</i> =0.27	$\chi^2=2.21$
<i>P</i> 值		0.53	0.11

相关报道不多。Salvatore 等<sup>[14]</sup>根据矢状面骨折线的位置进行分组研究发现, 骨水泥在骨折区域分布情况与临床疗效关系密切。然而, 由于骨折区域属于一种三维结构, 因此单纯依靠矢状面或者横断面去界定, 并不严谨, 特别是对于单侧椎体的骨折, 如果骨水泥推注到另一侧, 术后 X 线片由于叠加作用, 可显示骨折区骨水泥分布良好, 但临床效果却并不满意。本研究借助三维影像技术, 同时结合计算机辅助软件, 于术前通过 MRI 抑脂像确定骨折的区域, 并



**图 4** 患者, 男, 66 岁, PVP 术后骨水泥向椎体前缘渗漏 **图 5** 患者, 女, 71 岁, PVP 术后骨水泥向静脉渗漏

**Fig.4** A 66-year-old male patient, bone cement leaking to the anterior edge of vertebral body after PVP **Fig.5** A 74-year-old female patient, bone cement leaking to vein after PVP

进行三维建模, 计算出骨折区域的体积。在 PVP 术后, 对骨水泥进行三维成像, 并对骨折区域进行叠加, 计算出骨水泥在骨折区的体积比, 进而进行分组研究, 通过观察发现两组患者在 PVP 术后 VAS 评分及 ODI 指数均较术前明显下降, 其中在术后 1 d 观察组患者评分明显优于对照组, 说明骨水泥在骨折线区域的良好分布, 近期效果显著。在术后 3 个月左右进行随访发现, 两组患者 VAS 评分及 ODI 指数组间比较差异无统计学意义, 可能与非骨水泥填充区的骨质部分愈合等因素有关。

有学者认为骨水泥推注越多, 其在椎体中的分布越好, 效果也越好<sup>[15]</sup>。但也有学者认为骨水泥的分布情况与骨水泥的用量无明显相关性, 反而骨水泥推注过多, 增加了其渗漏风险<sup>[16]</sup>。在本研究中, 笔者发现观察组与对照组在骨水泥用量上差异无统计学意义。在骨水泥渗漏方面, 观察组有 4 例渗漏, 对照组有 3 例渗漏, 均无明显临床症状。骨水泥在椎体内的分布情况并不能完全受人为控制, 可受多种因素影响, 例如骨水泥的浓度、椎体骨质疏松程度、推注时间及速度等<sup>[17]</sup>。骨水泥推注时间过早, 可使其弥散充分, 但也使其渗漏的概率大大增加, 推注过晚, 则由于骨水泥的凝固, 可能导致推注困难及弥散不良。目前多数研究表明, 骨水泥在拔丝期推注最佳<sup>[18]</sup>。骨质疏松程度, 对骨水泥的弥散有一定影响, 骨质疏松越重, 椎体内的骨小梁空隙越大, 骨水泥越容易弥散, 骨质疏松轻的患者, 骨水泥弥散能力差<sup>[19]</sup>。此外, 穿刺针的位置对骨折区域内骨水泥的分布情况亦有一定影响。因此, 术前良好的阅片及确定骨折区域对

术后的疗效至关重要。如果骨折区域在椎体中上部,可通过调节工作套管使其到达骨折区域,以便于骨水泥良好弥散,如果穿刺针偏下,则可能导致骨水泥在骨折区域分布不佳,进而影响疗效。对于骨水泥缓解疼痛的作用机制,目前多数研究认为:(1)骨水泥的弥散及固化,对骨小梁起到粘附支撑作用,不仅承担部分应力,还能稳定椎体,减少折断的微动,进而缓解疼痛。(2)骨水泥在凝固过程中产热,对椎体内神经末梢具有直接杀伤作用。

综上所述,骨水泥在骨折线区域的分布情况,是 PVP 术后早期疗效的影响因素之一。本研究病例样本量较少,随访时间也有一定局限性,术后患者的远期疗效仍有待于进一步随访和观察。

#### 参考文献

- [1] Lin FC, Wang CY, Shang RJ, et al. Identifying unmet treatment needs for patients with osteoporotic fracture: feasibility study for an electronic clinical surveillance system[J]. *J Med Internet Res*, 2018, 20(4): e142.
- [2] 唐向盛, 谭明生, 移平, 等. 椎体后凸成形术治疗伴有肋间痛的胸椎压缩性骨折的临床疗效分析[J]. *中国骨伤*, 2017, 30(9): 823-827.  
TANG XS, TAN MS, YI P, et al. Clinical analysis of kyphoplasty in the treatment of thoracic compression fractures with intercostal pain [J]. *Zhongguo Gu Shang/China J Orthop Trauma*, 2017, 30(9): 823-827. Chinese with abstract in English.
- [3] Du JP, Fan Y, Liu JJ, et al. The analysis of multi-segment thoracolumbar mild osteoporotic fractures surgery or conservative treatment based on the assessment system of thoracolumbar osteoporotic fracture[J]. *Sci Rep*, 2018, 8(1): 8185.
- [4] Kuiper BW, Graybill S, Tate JM, et al. After the fall: improving osteoporosis treatment following hip fracture[J]. *Osteoporos Int*, 2018, 29(6): 1295-1301.
- [5] Messina C, Maffi G, Vitale JA, et al. Diagnostic imaging of osteoporosis and sarcopenia: a narrative review[J]. *Quant Imaging Med Surg*, 2018, 8(1): 86-99.
- [6] Chen Y, Guo Y, Zhang X, et al. Bone susceptibility mapping with MRI is an alternative and reliable biomarker of osteoporosis in postmenopausal women[J]. *Eur Radiol*, 2018 Jun 12. [Epub ahead of print].
- [7] Jin C, Xu G, Weng D, et al. Impact of MRI on treatment-related decision making for osteoporotic vertebral compression fracture: A prospective randomized trial[J]. *Med Sci Monitor*, 2018, 24: 50-57.
- [8] Xu W, Wang S, Chen C, et al. Correlation analysis between the magnetic resonance imaging characteristics of osteoporotic vertebral compression fractures and the efficacy of percutaneous vertebroplasty: a prospective cohort study[J]. *BMC Musculoskelet Disord*, 2018, 19(1): 114.
- [9] Zygourakis CC, DiGiorgio AM, Crutcher NC 2nd, et al. The safety and efficacy of CT-guided, fluoroscopy-free vertebroplasty in adult spinal deformity surgery[J]. *World Neurosurg*, 2018, 116: e944-e950.
- [10] Mansour A, Abdel-Razeq N, Abuali H, et al. Cement pulmonary embolism as a complication of percutaneous vertebroplasty in cancer patients[J]. *Cancer Imaging*, 2018, 18(1): 5.
- [11] Ye LQ, Liang, Jiang X B, et al. Risk factors for the occurrence of insufficient cement distribution in the fractured area after percutaneous vertebroplasty in osteoporotic vertebral compression fractures[J]. *Pain Physician*, 2018, 21(1): E33-E42.
- [12] Senturk S, Akyoldas G, Ünsaltüü, et al. Minimally invasive translaminar endoscopic approach to percutaneous vertebroplasty cement leakage: Technical note[J]. *World Neurosurg*, 2018, 117: 15-19.
- [13] Andrei D, Popa I, Brad S, et al. The variability of vertebral body volume and pain associated with osteoporotic vertebral fractures: conservative treatment versus percutaneous transpedicular vertebroplasty[J]. *Int Orthop*, 2017, 41(5): 963-968.
- [14] Salvatore G, Berton A, Giambini H, et al. Biomechanical effects of metastasis in the osteoporotic lumbar spine: A finite element analysis[J]. *BMC Musculoskel Disord*, 2018, 19(1): 38.
- [15] Peng Y, Du X, Huang L, et al. Optimizing bone cement stiffness for vertebroplasty through biomechanical effects analysis based on patient-specific three-dimensional finite element modeling [J]. *Med Biol Eng Comput*, 2018, 56(11): 2137-2150.
- [16] 孙启才, 茹选良, 宋柏杉, 等. 经皮椎体后凸成形术骨水泥渗漏的中期随访及应对策略[J]. *中国骨伤*, 2017, 30(9): 810-816.  
SUN QC, RU XL, SONG BS, et al. Medium term follow-up and coping strategies of percutaneous cement for percutaneous kyphoplasty[J]. *Zhongguo Gu Shang/China J Orthop Trauma*, 2017, 30(9): 810-816. Chinese with abstract in English.
- [17] 王想福, 范有福, 石瑞芳, 等. 单侧穿刺椎体后凸成形术骨水泥分布与穿刺角度的关系[J]. *中国骨伤*, 2015, 28(8): 704-707.  
WANG XF, FAN YF, SHI RF, et al. Relationship between bone cement distribution and puncture angle in unilateral percutaneous kyphoplasty[J]. *Zhongguo Gu Shang/China J Orthop Trauma*, 2015, 28(8): 704-707. Chinese with abstract in English.
- [18] Amoretti N. Early percutaneous vertebroplasty helps motorsport professionals to resume competition soon after vertebral fracture[J]. *Eur Radiol*, 2018, 28(7): 2870-2871.
- [19] Aebi M, Maas C, Di Pauli von Treuheim T, et al. Comparative biomechanical study of a new transpedicular vertebral device and vertebroplasty for the treatment or prevention of vertebral compression fractures[J]. *Clin Biomech (Bristol, Avon)*, 2018, 56: 40-45.

(收稿日期: 2018-10-18 本文编辑: 王宏)