

·经验交流·

# 股骨近端解剖锁定钢板治疗伴外侧壁骨折的股骨转子间骨折中期疗效随访

徐金渭, 韩雷, 胡云根, 方伟利, 金波  
(浙江中医药大学附属江南医院 杭州市萧山中医院, 浙江 杭州 311201)

**【摘要】 目的:**对股骨近端解剖型钢板治疗伴外侧壁骨折的转子间骨折中期疗效进行回顾性研究。**方法:**2010 年 6 月至 2013 年 1 月采用股骨近端解剖型钢板固定治疗转子间伴外侧壁骨折 18 例,男 8 例,女 10 例;年龄 19~83 岁,平均 75.5 岁;车祸伤 8 例,摔伤 6 例,高处坠落伤 4 例;受伤至手术时间为 1~14 d,平均 4.5 d;随访时拍摄股骨正侧位 X 线片。记录患者手术时间、术中出血量、住院天数,术后疗效评价采用 Parker Palmer mobility score (PPMS)及 Harris 髋关节功能评分标准。**结果:**18 例患者均获得随访,时间 36~68 个月,平均(44.8±8.8)个月。手术时间(61.02±38.28) min,术中出血量(226.00±162.52)ml,住院时间(10.8±9.2) d。所有患者未出现局部感染、深静脉血栓、螺钉切割股骨头及断钉,2 例患者出现不同程度髋内翻短缩畸形,无骨折不愈合患者。骨折愈合时间为 4~10 个月,平均 6.2 个月。末次随访时,PPMS 评分为(7.22±2.36)分;Harris 评分为(79.46±11.02)分,其中优 5 例,良 9 例,可 2 例。**结论:**解剖型锁定钢板治疗伴外侧壁骨折的转子间骨折中期疗效显著,术中可避免外侧壁二次损伤,尤其对外侧壁严重粉碎、髓内钉操作困难以及高龄骨质疏松者,术后需严格随访,不应强调过早负重。

**【关键词】** 髋骨折; 股骨骨折; 骨折固定术,内; 随访研究

**DOI:** 10.3969/j.issn.1003-0034.2017.03.014

**A medium term therapeutic effects of anatomic locking plate for femoral intertrochanteric with lateral femoral wall fractures** XU Jin-wei, HAN Lei, HU Yun-gen, FANG Wei-li, and JI Bo. Traditional Chinese Medical Hospital of Xiaoshan, Hangzhou 311201, Zhejiang, China

**ABSTRACT Objective:** To retrospectively study medium term follow-up outcomes of the femoral intertrochanteric with lateral femoral wall fractures using anatomic locking plate fixation. **Methods:** From June 2010 to January 2013, 18 cases of the unstable femoral intertrochanteric with lateral femoral wall fractures were treated with the anatomic locking plate, included 8 males and 10 females with an average age of 75.5 years ranging from 19 to 83 years old. There were 8 cases of traffic accident injuries, 6 cases of falls injuries, and 4 cases of falling from high place. The time from injury to operation was ranged from 1 to 14 days with an average of 4.5 days. The operation time, intraoperative blood loss and the length of hospitalization were recorded and analyzed. The fracture union was assessed by follow-up radiographs and hip functional recovery by PPMS and Harris hip scoring. **Results:** All patients were followed up from 36 to 68 months with a mean of (44.8±8.8) months. The mean operative time was (61.02±38.28) min; the mean blood loss was (226.00±162.52) ml; the mean length of hospitalization was (10.8±9.2) days. During the follow-up period, no infection, deep vein thrombosis, screwed cut-out and implant failure occurred in all patients. Coxa vara with shortening deformity was noted in 2 cases. Bone union was found in all the cases. The bone healing time was ranged from 4 to 10 months with an average of 6.2 months. The mean PPMS score at the final follow-up was 7.22±2.36. The Harris score was 79.46±11.02, 5 cases were classified as excellent, 9 as good and 2 as fair. **Conclusion:** Proximal femoral anatomic locking plate can be used in treating intertrochanteric fractures with compromised lateral wall, which has a satisfied medium term follow-up outcomes, especially for complex fractures patterns in which intramedullary nailing may be difficult, and should not emphasis on premature loading.

**KEYWORDS** Hip fractures; Femoral fractures; Fracture fixation, internal; Follow up studies

Zhongguo Gu Shang/China J Orthop Trauma, 2017, 30(3):256-260 www.zggszz.com

近年来,国内外学者提出股骨转子外侧壁概念,并且认为外侧壁骨折是判断转子间骨折是否稳定的

重要因素<sup>[1]</sup>。外侧壁在解剖上是指股外侧肌嵴以远的股骨近端外侧皮质<sup>[2]</sup>。多数临床医师对股骨转子间伴外侧壁骨折提倡用髓内固定系统<sup>[3]</sup>,然而也有不少学者证实对于股骨髓腔狭小、股骨前弓过大、外侧壁骨折或转子部冠状面劈裂者使用髓内钉可能增

通讯作者:韩雷 E-mail:hallen505@163.com  
Corresponding author: HAN Lei E-mail:hallen505@163.com

加术中再骨折、骨折再移位的风险<sup>[4]</sup>,尤其对于高龄骨质疏松患者,内固定物切割、髁内翻畸形一直是难以解决的问题。即使髓内钉术后仍有 2%~3.6% 的患者发生内固定物切割、髁内翻畸形<sup>[5]</sup>。并且髓内固定较髓外固定在术后髋关节功能恢复方面无明显优势<sup>[6-8]</sup>。目前关于股骨近端锁定钢板术后随访多限于短期研究。笔者自 2010 年 6 月至 2013 年 1 月采用股骨近端解剖型钢板固定治疗转子间伴有外侧壁骨折 18 例,报告如下。

## 1 临床资料

2010 年 6 月至 2013 年 1 月我院收治股骨转子间骨折患者 176 例,满足如下标准而入选本研究:(1)年龄<18 岁;(2)新鲜闭合性骨折;(3)选择采用解剖锁定钢板固定治疗且随访时间超过 12 个月者;(4)术前 CT 示均伴有不同程度外侧壁骨折(按 X 线正位片,从股骨颈上下各作一切线,切线之间的股骨外侧即为外侧壁,见图 1)<sup>[9]</sup>。共 18 例患者符合标准,其中男 8 例,女 10 例;年龄 19~83 岁,平均 75.5 岁;车祸伤 8 例,摔伤 6 例,高处坠落 4 例;左侧 11 例,右侧 7 例。按 AO/OTA 分型<sup>[10]</sup>:A2.2 型 2 例,A2.3 型 3 例,A3.1 型 5 例,A3.2 型 5 例,A3.3 型 3 例。合并糖尿病 6 例,高血压及冠心病等心脏疾病 13 例,气管炎及肺部疾病 8 例。受伤至手术时间为 1~14 d,平均 4.5 d。

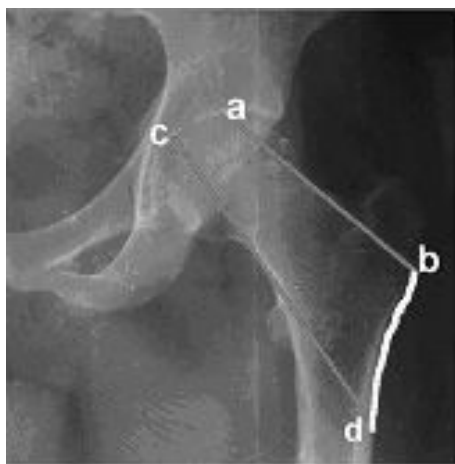


图 1 沿股骨颈股骨颈上下各作一切线,切线之间的股骨外侧即为外侧壁

Fig. 1 Two lines, one as a tangent to the superior femoral neck (a to b) and the other as a tangent to the inferior femoral neck (c to d) were drawn, the part of the lateral femoral cortex which lies between these two lines (b to d) was the lateral femoral wall

## 2 治疗方法

### 2.1 手术方法

患者仰卧牵引床,患肢外展、内旋、内收牵引复

位,C 形臂 X 线透视显示复位满意,取大转子顶点向下作侧方直切口 5~7 cm,切开阔筋膜及股外侧肌,暴露股骨转子,将股外侧肌牵向前下方,无须剥离骨膜,复位骨折断端,恢复颈干角和前倾角,选择适宜长度解剖锁定钢板贴股骨外表面插入,确保钢板与股骨近端接触良好。C 形臂 X 线透视下确定钢板位置及骨折复位满意后,利用导向手柄分别于骨折远、近端各打入 4~6 枚锁定螺钉。再次透视检查骨折复位情况及内固定位置。

### 2.2 术后处理

术后 1 d 即开始进行膝、踝关节功能锻炼,术后 48 h 采用半卧位行主动肌肉舒缩锻炼。门诊随访根据 X 线示有连续性骨痂通过骨折线,患肢即可逐渐负重活动。

## 3 结果

18 例患者均获随访,时间 36~68 个月,平均(44.8±8.8)个月。手术时间(61.02±38.28) min,术中出血量(226.00±162.52) ml,住院时间(10.8±9.2) d。所有患者未出现局部感染、深静脉血栓、螺钉切割股骨头及断钉。2 例患者出现不同程度髁内翻短缩畸形,因患者高龄,可基本满足日常生活,未特殊处理。所有患者骨折 I 期愈合,愈合时间为 4~12 个月,平均 6.2 个月。术后部分负重(身体重量 15%)时间为(10.2±4.3) d,完全负重时间(4.5±2.6)个月。4 例患者术后 1~2.5 年取出钢板,平均 1.5 年。

髋关节功能按 PPMS 评分标准<sup>[11]</sup>(Parker Palmer mobility score, PPMS)(见表 1)进行评价,包括室外活动、室内活动、日常生活自理方面,满分 9 分;末次随访时本组病例 PPMS 评分:室内活动 2.62±1.02,室外活动 2.34±0.42,日常生活自理 2.32±1.08,总分 7.22±2.36。

表 1 Parker-Palmer 评分标准(分)

Tab. 1 Parker and Palmer mobility score(score)

项目	没有困难	使用助步器	需要他人帮助	不能
室外活动	3	2	1	0
室内活动	3	2	1	0
日常生活自理	3	2	1	0

髋关节功能采用 HHS 评分(Harris hip score, HHS)<sup>[12]</sup>进行评价,包括疼痛、功能、畸形、运动范围等 4 个方面,满分 100,优 90~100 分,良 80~89 分,可 70~79 分,差<70 分。末次随访时 Harris 评分结果:疼痛 39.22±2.28,功能 36.16±3.24,运动范围 3.51±0.95,畸形 3.26±0.58,总分 79.46±11.02;其中优 5 例,良 9 例,可 2 例。典型病例见图 2。

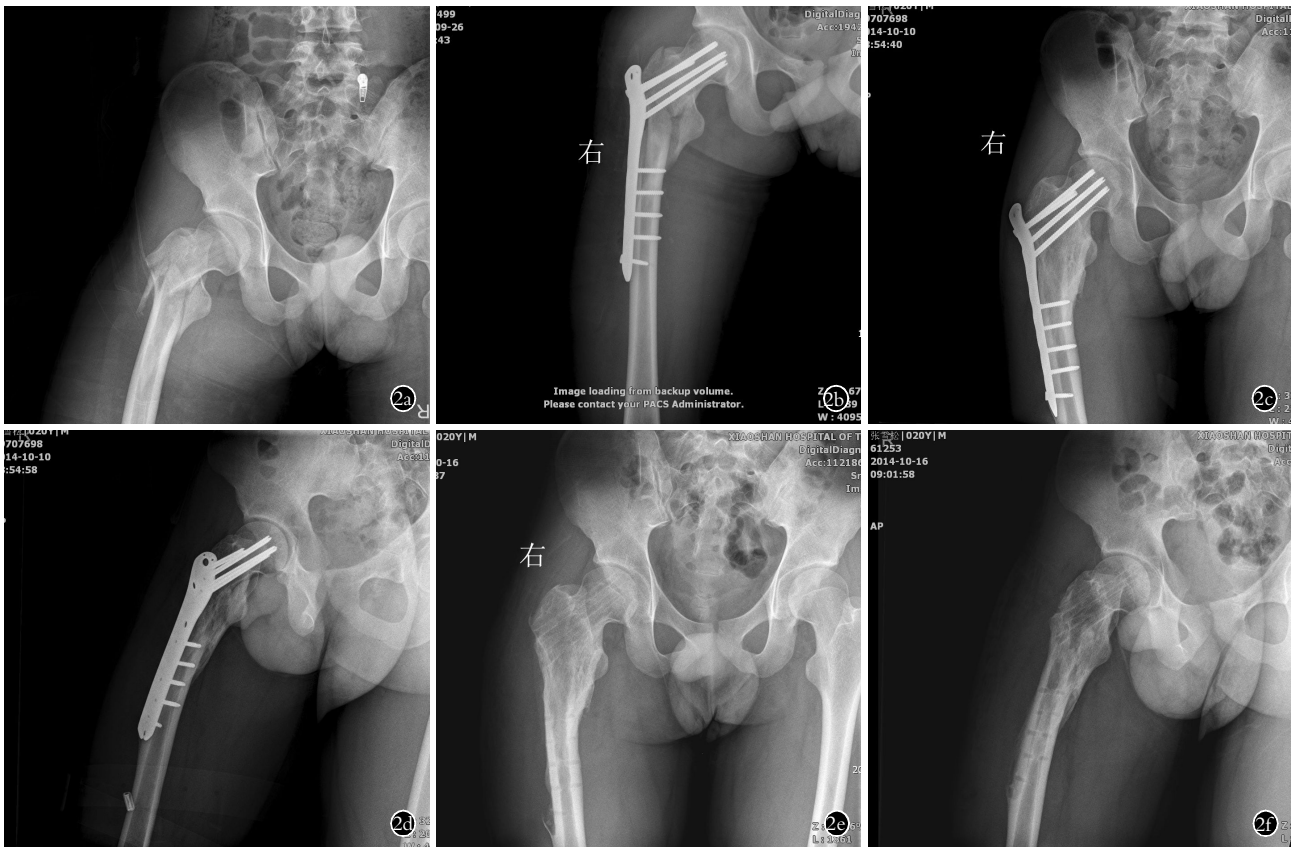


图 2 男,19 岁,右侧股骨转子间骨折,解剖锁定钢板固定 2a. 术前骨盆正位 X 线片示右侧股骨转子间骨折,外侧壁骨折 2b. 术后 3 d 右髋正位 X 线片示骨折复位满意 2c,2d. 术后 6 个月右髋正斜位 X 线片示骨折愈合 2e,2f. 术后 1 年内固定拆除术后

Fig.2 A 19-year-old male with the right intertrochanteric fracture stabilized treated with proximal femoral LCP 2a. Preoperative AP view radiograph of the pelvic showed the intertrochanteric fracture associated with lateral femoral wall fractures 2b. At 3 days after operation, AP X-ray showed satisfied fracture reduction 2c,2d. At 6 months after operation, AP and oblique X-rays showed fracture healing 2e,2f. AP and oblique X-rays at 1-year-follow-up after plate removal showed bony union

#### 4 讨论

##### 4.1 伴有外侧壁骨折的转子间骨折内固定的选择

目前,转子间骨折的内固定技术主要分为髓内固定技术和髓外钉板固定技术。髓外固定系统以 DHS 为代表,是治疗转子间骨折的经典内固定<sup>[13]</sup>。但由于存在轴向、横向及旋转方向的相对不稳定,易发生疲劳断裂、骨折不愈合或内翻畸形等并发症,尤其是后内侧股骨距粉碎、外侧壁不完整的骨折,DHS 的失败率较高<sup>[14-16]</sup>。髓内固定系统因具备微创置入、可较好保护骨折端血供、固定强度可靠等特点而越来越多地被用于转子部骨折的治疗。但对于亚洲人群来说,髓内钉与股骨干一定程度上的不匹配使手术操作困难<sup>[17]</sup>。如果股骨髓腔狭小、股骨前弓过大、转子部冠状面劈裂或外侧壁骨折者,使用髓内钉可造成术中再骨折、骨折再移位,进而加重外侧壁的不稳定性<sup>[18]</sup>。同时如外侧壁下 1.5~2.5 cm 处(即小转子上缘水平线与外侧壁交点处)的骨皮质完整性缺损,则无法提供髓内钉拉力钉的良好支点,故失去了对骨折近端的固定作用;术后患肢内收导致骨折近

端向外上方再移位,后期导致患肢髓内翻畸形<sup>[19]</sup>。循证医学亦证实髓内钉较锁定钢板在手术时间和术后髋关节功能恢复方面无明显优势<sup>[6-8]</sup>。这提示对于外侧壁骨折、转子部冠状面劈裂等髓内固定操作困难或伴有严重骨质疏松的病例可用锁定钢板作为内固定物。

##### 4.2 外侧壁的重要作用

股骨转子外侧壁概念是近年提出并逐渐认识和重视的新理念<sup>[9]</sup>。该部位以松质骨为主要组成部分,且在术中极易受到医源性破坏,形成二次损伤。Gotfried<sup>[2]</sup>提出外侧壁危险型股骨转子间骨折概念,相当于 AO 分型 A2.2 和 A2.3 型顺转子间骨折,从力学上分析外侧壁可对股骨头颈骨块提供外侧方支撑阻挡,一旦外侧壁破坏则可致使近侧头颈骨块外移塌陷,远侧的股骨干内移,形成骨折断端不稳定。Gotfried<sup>[2]</sup>通过对 24 例股骨转子部骨折内固定失败患者的研究发现,所有患者存在外侧壁骨折。Palm 等<sup>[20]</sup>认为外侧壁破裂是 DHS 固定转子间骨折再次翻修手术最重要的独立预测因素,高于拉力螺钉在

股骨头内的位置(即尖顶距)。对于伴有大转子外侧壁粉碎患者,如术中操作不当形成外侧壁医源性爆裂,失去外侧壁对股骨头颈支撑、抗旋及抗内翻重要力学作用<sup>[1]</sup>。本组研究中 3 例患者首选 Gamma 钉,术中发生外侧皮质劈裂,进钉固定后断端仍不稳定,及时更换备用的近端锁定钢板系统。

#### 4.3 解剖型锁定板治疗伴有外侧壁骨折转子间骨折的优点

Zhou 等<sup>[21]</sup>最先报道使用 LISS 倒置固定来治疗不稳定型股骨转子部骨折,获得了良好疗效。解剖锁定钢板较髓内固定系统具有优势:(1)锁钉与钢板的成角稳定,钢板远端单皮质锁定,减少应力集中,从而可以减少螺钉断裂发生;(2)对于骨质疏松明显,同时脂肪栓塞风险较大患者尤为适合;(3)股骨前弓过大、髓腔狭窄及大转子粉碎并伴有冠状面劈裂的患者具有较强适应证。虽然国内外有诸多文献报道 LISS 钢板治疗转子部骨折,但亦有不少术后内固定相关并发症,如螺钉断裂及骨折延迟愈合<sup>[22-23]</sup>。Johnson 等<sup>[23]</sup>回顾性分析 29 例股骨近端锁定钢板治疗股骨转子间骨折的短期疗效,其中 12 例出现内固定并发症。笔者发现需避免以下几个因素来降低内固定失败风险:锁定接骨板多用于治疗严重粉碎性复杂骨折或者严重骨质疏松,且锁定接骨板为偏心固定,故不应强调过早负重,否则容易引起内固定断裂、髓内翻等并发症,待 X 线片示连续骨痂通过骨折线时方可开始部分负重;置入股骨颈内的螺钉应位于下 1/3 骨质密度最高处,以获得最大把持力。

综上所述,对于伴有外侧壁骨折的转子间骨折使用解剖型锁定钢板固定中期疗效可靠,术中可避免外侧壁二次损伤,尤其适合外侧壁严重粉碎、髓内钉操作困难以及高龄骨质疏松者,但因其为偏心固定,不应强调过早负重。

#### 参考文献

- [1] 陈雁西,梅炯,毕刚,等. PFNA 治疗股骨转子间伴或不伴外侧壁骨折的疗效分析[J]. 中华骨科杂志, 2012, 32(7): 614-620. CHEN YX, MEI J, BI G, et al. Efficacy of PFNA in the treatment of femoral intertrochanteric fracture with or without lateral wall fracture[J]. Zhonghua Gu Ke Za Zhi, 2012, 32(7): 614-620. Chinese.
- [2] Gotfried Y. The lateral trochanteric wall: a key element in the reconstruction of unstable pertrochanteric hip fractures[J]. Clin Orthop Relat Res, 2004, (425): 82-86.
- [3] 魏杰,秦德安,郭秀生,等. 防旋型股骨近端髓内钉治疗股骨粗隆间骨折及大粗隆外侧壁不完整型的疗效分析[J]. 中国骨伤, 2015, 28(6): 572-575. WEI J, QIN DA, GUO XS, et al. Curative effect analysis on proximal femoral nail antirotation for the treatment of femoral intertrochanteric fracture and integrity of lateral trochanteric wall[J]. Zhongguo Gu Shang/China J Orthop Trauma, 2015, 28(6): 572-575. Chinese with abstract in English.
- [4] Hwang JH, Oh JK, Han SH, et al. Mismatch between PFNA and medullary canal causing difficulty in nailing of the pertrochanteric fractures[J]. Arch Orthop Trauma Surg, 2008, 128(12): 1443-1446.
- [5] Sahin S, Ertürer E, Öztürk I, et al. Radiographic and functional results of osteosynthesis using the proximal femoral nail antirotation (PFNA) in the treatment of unstable intertrochanteric femoral fractures[J]. Acta Orthop Traumatol Turc, 2010, 44(2): 127-134.
- [6] Matre K, Vinge T, Havelin LI, et al. Trigen intertan intramedullary nail versus sliding hip screw: a prospective, randomized multicenter study on pain, function, and complication in 684 patients with an intertrochanteric or subtrochanteric fracture and one year of follow-up[J]. J Bone Joint Surg Am, 2013, 95(3): 200-208.
- [7] 韦旭明,孙振中,宋晓军. 经皮加压钢板与股骨近端防旋髓内钉治疗外侧壁危险型股骨粗隆间骨折的病例对照研究[J]. 中国骨伤, 2013, 26(12): 981-983. WEI XM, SUN ZZ, SONG XJ, et al. Case-control study on percutaneous compressing plating and proximal femoral nail antirotation in treating intertrochanteric fracture with risk external wall[J]. Zhongguo Gu Shang/China J Orthop Trauma, 2013, 26(12): 981-983. Chinese with abstract in English.
- [8] 胡云根,韩雷,方伟利,等. 解剖型锁定钢板及 Gamma 钉治疗伴有外侧壁骨折股骨转子间骨折的病例对照研究[J]. 中国骨伤, 2016, 29(6): 496-501. HU YG, HAN L, FANG WL, et al. Locking plate versus Gamma nail for unstable femoral intertrochanteric fractures with lateral wall fractures[J]. Zhongguo Gu Shang/China J Orthop Trauma, 2016, 29(6): 496-501. Chinese with abstract in English.
- [9] Haq RU, Marhas V, Pankaj A, et al. Proximal femoral nails compared with reverse distal femoral locking plates in intertrochanteric fractures with a compromised lateral wall: a randomised controlled trial[J]. Int Orthop, 2014, 38(7): 1443-1449.
- [10] Müller ME. Classification and international AO-documentation of femur fractures[J]. Unfallheilkunde, 1980, 83(5): 251-259.
- [11] Parker MJ, Palmer CR. A new mobility score for predicting mortality after hip fracture[J]. J Bone Joint Surg Br, 1993, 75(5): 797-798.
- [12] Harris WH. Traumatic arthritis of the hip after dislocation and acetabular fractures: treatment by mold arthroplasty. An end-result study using a new method of result evaluation[J]. J Bone Joint Surg Am, 1969, 51(4): 737-755.
- [13] Haidukewych GJ. Intertrochanteric fractures: ten tips to improve results[J]. J Bone Joint Surg Am, 2009, 91(3): 712-719.
- [14] 张长青. 关于老年股骨转子间骨折的当代观点[J]. 中华骨科杂志, 2012, 32(7): 611-612. ZHANG CQ. A contemporary view between intertrochanteric fractures for elderly patients[J]. Zhonghua Gu Ke Za Zhi, 2012, 32(7): 611-612. Chinese.
- [15] Hsu CE, Shih CM, Wang CC, et al. Lateral femoral wall thickness. A reliable predictor of post-operative lateral wall fracture in intertrochanteric fractures[J]. Bone Joint J, 2013, 95B(8): 1134-1138.
- [16] Dhamangaonkar AC, Joshi D, Goregaonkar AB, et al. Proximal femoral locking plate versus dynamic hip screw for unstable intertrochanteric femoral fractures[J]. J Orthop Surg (Hong Kong),

2013, 21(3):317-322.

[17] Leung KS, Procter P, Robioneck B, et al. Geometric mismatch of the Gamma nail to the Chinese femur[J]. Clin Orthop Relat Res, 1996, (323):42-48.

[18] 周方, 谭磊, 张志山, 等. 倒置微创锁定接骨板与髓内钉治疗股骨转子部骨折疗效对比分析[J]. 中华骨科杂志, 2015, 35(1): 32-39.  
ZHOU F, TAN L, ZHANG ZS, et al. Reversed less invasive stabilization system versus intramedullary fixation devices for femoral trochanteric fractures[J]. Zhonghua Gu Ke Za Zhi, 2015, 35(1): 32-38. Chinese.

[19] 黄海晶, 辛景义, 马宝通. Gamma 3 型髓内钉治疗股骨转子间骨折手术并发症的原因分析[J]. 中华骨科杂志, 2014, 34(7): 736-742.  
HUANG HJ, XIN JY, MA BT. Causes of the complications in the patients with femoral peritrochanteric fractures with Gamma 3 nail [J]. Zhonghua Gu Ke Za Zhi, 2014, 34(7):736-742. Chinese.

[20] Palm H, Jacobsen S, Sonne-Holm S, et al. Integrity of the lateral femoral wall in intertrochanteric hip fractures: an important predictor of a reoperation[J]. J Bone Joint Surg Am, 2007, 89(3):470-475.

[21] Zhou F, Zhang ZS, Yang H, et al. Less invasive stabilization system (LISS) versus proximal femoral nail anti-rotation (PFNA) in treating proximal femoral fractures: a prospective randomized study[J]. J Orthop Trauma, 2012, 26(3): 155-162.

[20] Glassner PJ, Tejwani NC. Failure of proximal femoral locking compression plate: a case series[J]. J Orthop Trauma, 2011, 25(2): 76-83.

[22] McMichael JC, Moed BR. Failure of intertrochanteric fixation using a locking plate: a case report[J]. Curr Orthop Pract, 2009, 20: 101-104.

[23] Johnson B, Stevenson J, Chamma R, et al. Short-term follow-up of peritrochanteric fractures treated using the proximal femoral locking plate[J]. J Orthop Trauma, 2014, 28(5):283-287.

(收稿日期:2016-08-20 本文编辑:王玉蔓)

·读者·作者·编者·

### 本刊关于参考文献著录的要求

按 GB/T 7714-2015《信息与文献 文后参考文献著录规则》采用顺序编码著录,依照其在文中出现的先后顺序用阿拉伯数字标出,并将序号置于方括号中,排列于文后。中文参考文献要求用英汉双语著录;用汉语拼音书写的人名,姓全大写,其名缩写,取每个汉字拼音的首字母;刊名用汉语拼音拼写。参考文献中的作者,1~3 名全部列出,3 名以上只列前 3 名,后加“等”。外文期刊名称用缩写,以 Index Medicus 中的格式为准。每条参考文献均须著录起止页。①期刊:[序号]作者.题名[J].刊名,年,卷(期);起止页码。②专著:[序号] 著者.书名[M].版次.出版地:出版者,出版年;起止页码。③专著中析出文献:[序号]作者.题名[M]//编者.书名.版次.出版地:出版者,出版年;起止页码。

《中国骨伤》杂志社