者的预后良好。同时抗凝具有相关并发症,如颅内出血、神经损伤加重及创面出血等。因此,我们认为观察处理可作为椎动脉损伤的一种治疗手段。

由于椎动脉损伤具有栓子脱落而导致颅内栓塞潜在的巨大危险,密切随访是必要的。Biffl 等[10] 通过颈部血管造影复查发现,43% 的颈动脉和椎动脉狭窄患者易进展形成假动脉瘤,而假动脉瘤的形成多需手术结扎或介入治疗。对于椎动脉损伤患者,建议创伤后定期行椎动脉 MRA 复查,依据复查结果决定下一步治疗方案。

参考文献

1 Miller PR, Fabian TC, Croce MA, et al. Prospective screening for blunt cerebrovascular injuries: analysis of diagnostic modalities and outcomes. Ann Surg, 2002, 336: 286-395.

2 Levy C, Laissy JP, Raveau V, et al. Carotid and vertebral artery dissections: three-dimensional time of flight MR angiography and MR imaging versus conventional angiography. Radiology, 1997, 28: 97-103.

3 Bok AP, Peter JC. Carotid and vertebral artery occlusion after blunt cervical injury: the role of MR angiography in early diagnosis. Trauma, 1996, 40: 968-972.

4 Friedman D, Flanders A, Thomas C, et al. Vertebral artery injury after acute cervical spine trauma: rate of occurrence as detected by MR angiography and assessment of clinical consequences. Am J Roentgenol, 1995, 164: 443-447.

5 Weller SJ, Rossitch E Jr, Malek AM. Detection of vertebral artery after cervical spine trauma using magnetic resonance angiorgraphy. Trauma, 1999, 46: 660-666.

6 Nibu K, cholewicki J, Panjabi MM, et al. Dynamic elongation of the vertebral artery during an in vitro whiplash simulation. European Spine Journal, 1997, 6: 286-289.

7 Johnson CP, How T, Scraggs M, et al. A biomechanical study of the human vertebral artery with implications for fatal arterial injury. Forensic Science International, 2000, 109: 169-182.

8 Parbhoo AH, Govender S, Corr P. Vertebral artery injury in cervical spine trauma. Injury, 2001, 32: 565-568.

9 Biffl WL, Moore EE, Elliott J, et al. The devastating potential of vertebral arterial injuries. Ann Surg, 2000, 231: 672-681.

10 Biffl WL, Ray CE Jr, Moore EE, et al. Treatment-related outcomes from blunt cerebrovascular injuries: importance of routine follow-up arteriography. Ann Surg, 2002, 235: 699-907.

(收稿日期: 2003-10-23　本文编辑: 连智华)

·病例报告·

跳绳致双足第三跖骨疲劳骨折 1 例

Third metatarsal bone fatigue fractures of both feet caused by rope skipping

曹扬
CAO Yang

关键词　第三跖骨;　疲劳骨折　　**Key words**　Third metatarsal bone;　Fatigue fractures

患者,男,14 岁,初二学生。双足疼痛伴肿胀 10 d。1 个月前为备考体育开始练习跳绳,每天练习 30 min,10 d 前自觉双足持续性疼痛,运动后明显,休息后减轻,并出现足背肿胀,早上肿胀消退。查体:一般情况良好,步态正常,双足背轻度肿胀,第三跖骨中段可触及 3 cm × 2 cm 的梭形肿块,质硬,不活动。X 线片提示:双足第三跖骨中段有骨膜反应,骨皮质不光滑,骨密度增加(见图 1)。血液生化学检查:AKP 190 U/L,血沉 18 mm/h。临床诊断为"双足第三跖骨疲劳骨折",给石膏固定 4 周,病人症状消失,X 线复查骨痂愈合。

讨论

疲劳骨折是发生在特殊人群的损伤,在普通骨科患者中并不多见,易发生于长途行军之后,首先由外科军医所认识,故又称行军骨折。与暴力引起的急性骨折不同,它是由于低于骨骼强度极限的应力反复、持久地作用于骨骼,引起局部骨质累积性微损伤和吸收、破坏所致,并可发展成完全骨折,是阈下损伤积累的结果,其特征是骨的破坏与修复同时进行[1]。由于其临床症状轻微,因此易被忽视。随着体育运动的发展和全民健身活动的开展,这类患者日渐增多,需要引起我们足够的重视。早期应与慢性骨髓炎,尤其是骨肿瘤相鉴别。

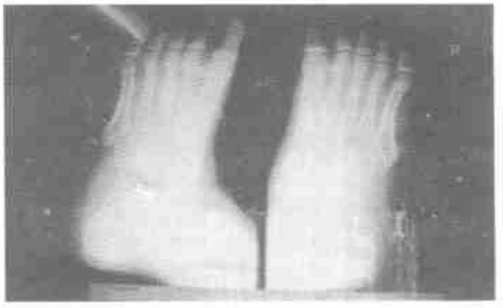

图 1　双足第三跖骨疲劳骨折

Fig. 1　Third metatarsal bone fatigue fractures of both feet

参考文献

1 岳勇,赵东风,黄湘梅,等. 应力性骨折的诊断、治疗与预防. 骨与关节损伤杂志, 2002, 17(6): 470-472.

(收稿日期: 2003-05-27　本文编辑: 李为农)

金华市中心医院骨科,浙江　金华　321000